The Court's Preliminary Injunction Decision Correctly Found that Edeland Undermines the Validity of the '404 Patent

"The [Edeland] reference discloses a method of fixation of a fracture of the tibia by surgically inserting a concave probe via fenestration into the fracture site, pushing the probe into the bone to reduce the fracture by compacting cancellous bone, and injecting a material into the void. Because the probe is inserted via fenestration, the Edeland method appears to form a passage in the bone. With regard to the element 'compacting bone marrow to increase the volume of said passage,' the probe is pushed in order to transfer and compact cancellous bone in front of the probe. The Court finds that pushing the probe to compact cancellous bone could be read to 'increase the volume' of the passage. Furthermore, the Court finds that the [Edeland] reference could be read to disclose 'filling the passage with a flowable material capable of setting to a hardened condition.' "

See Exhibit A-30, p. 7.

Case 1:04-cv-00204-JJF Document 196-16 Filed 04/27/2005 Page 1 of 10

Edeland Predates the Effective Filing Date and Discloses the Preamble of Claim 1: "method of fixation of a fracture"

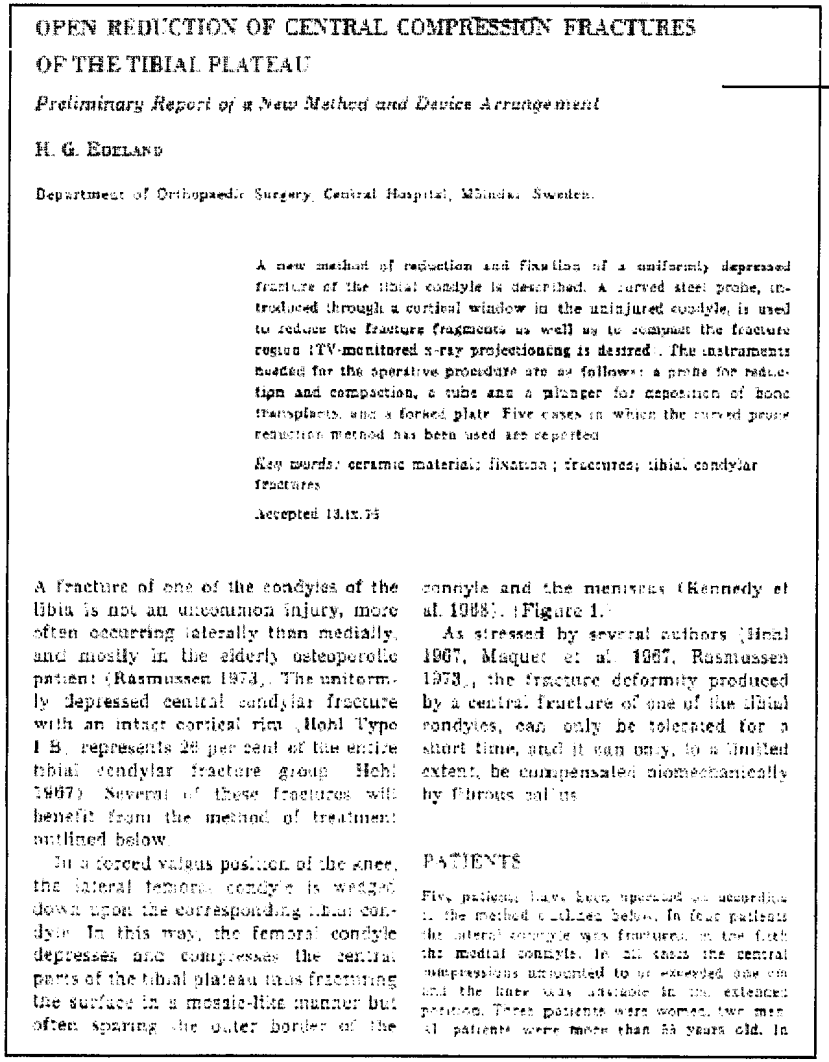

OPEN REDUCTION OF CENTRAL COMPRESSION FRACTURES OF THE TIBIAL PLATEAU

Preliminary Report of a New Method and Device Arrangement

H. G. EDELAND

Department of Orthopaedic Surgery, Central Hospital, Mölndal, Sweden.

A new method of reduction and fixation of a uniformly depressed fracture of the tibial condyle is described. A curved steel probe, introduced through a cortical window in the uninjured condyle, is used to reduce the fracture fragments as well as to compress the fracture region (TV-monitored x-ray projections) is desired. The instruments needed for the operative procedure are as follows: a probe for reduction and compaction, a tube and a plunger for deposition of bone transplants, and a forked plate. Five cases in which the curved probe reduction method has been used are reported.

Key words: ceramic materials; fixation; fractures; tibial condylar fractures

Accepted 13.IX.76

A fracture of one of the condyles of the tibia is not an uncommon injury, more often occurring laterally than medially, and mostly in the elderly osteoporotic patient (Rasmussen 1973). The uniformly depressed central condylar fracture with an intact cortical rim (Hohl Type I B) represents 28 per cent of the entire tibial condylar fracture group (Hohl 1967). Several of these fractures will benefit from the method of treatment outlined below.

In a forced valgus position of the knee, the lateral femoral condyle is wedged down upon the corresponding tibial condyle. In this way, the femoral condyle depresses and compresses the central parts of the tibial plateau thus fracturing the surface in a mosaic-like manner but often sparing the outer border of the condyle and the meniscus (Kennedy et al. 1968). (Figure 1.)

As stressed by several authors (Hohl 1967, Maquet et al. 1967, Rasmussen 1973), the fracture deformity produced by a central fracture of one of the tibial condyles, can only be tolerated for a short time, and it can only, to a limited extent, be compensated biomechanically by fibrous callus.

PATIENTS

Five patients have been operated on according to the method outlined below. In four patients the lateral condyle was fractured, in the fifth the medial condyle. In all cases the central compression amounted to or exceeded one cm and the knee was unstable in the extended position. Three patients were women, two men. All patients were more than 55 years old. In

OPEN REDUCTION OF CENTRAL COMPRESSION FRACTURES OF THE TIBIAL PLATEAU

Preliminary Report of a New Method and Device Arrangement

H. G. EDELAND

1976

Exhibit A-17

Case 1:04-cv-00204-JJF Document 196-16 Filed 04/27/2005 Page 2 of 10

Edeland Discloses the "Forming the Passage" Step of Claim 1

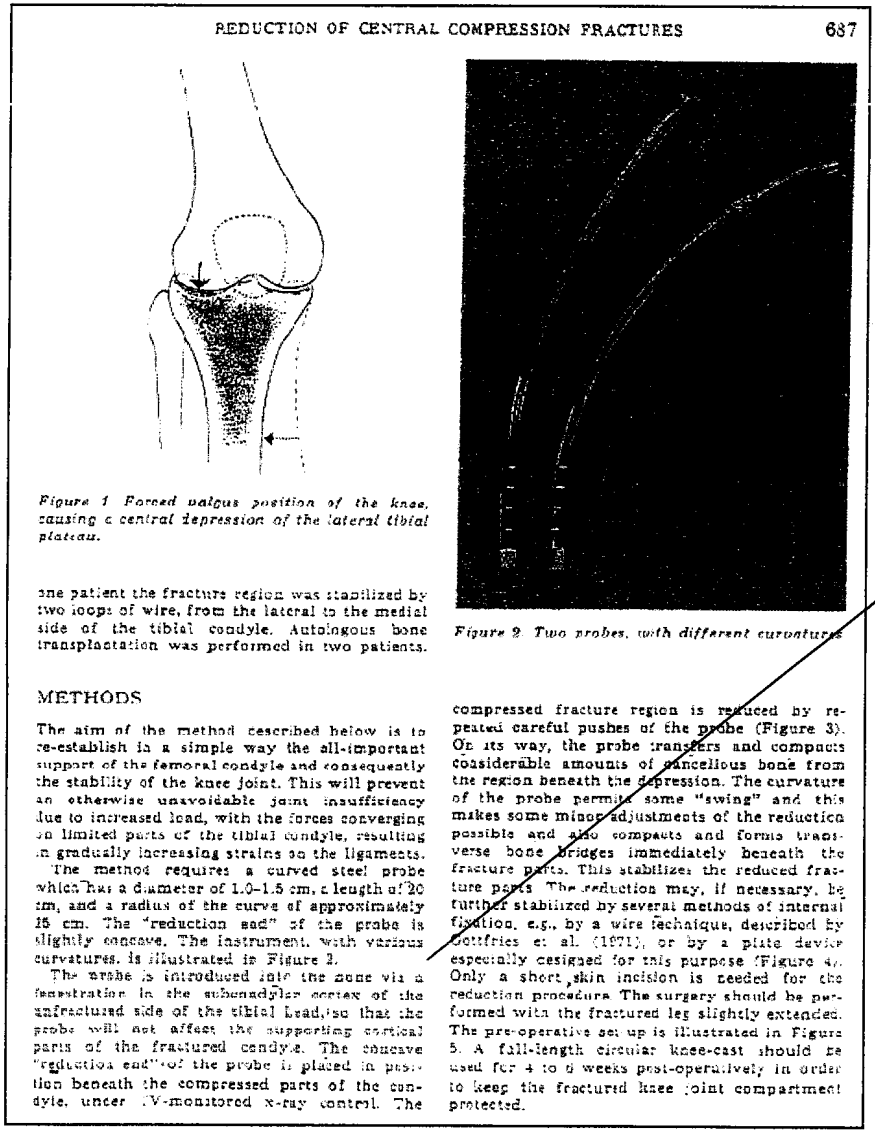

REDUCTION OF CENTRAL COMPRESSION FRACTURES 687

Figure 1. Forced valgus position of the knee, causing a central depression of the lateral tibial plateau.

one patient the fracture region was stabilized by two loops of wire, from the lateral to the medial side of the tibial condyle. Autologous bone transplantation was performed in two patients.

METHODS

The aim of the method described below is to re-establish in a simple way the all-important support of the femoral condyle and consequently the stability of the knee joint. This will prevent an otherwise unavoidable joint insufficiency due to increased load, with the forces converging on limited parts of the tibial condyle, resulting in gradually increasing strains on the ligaments.

The method requires a curved steel probe which has a diameter of 1.0–1.5 cm, a length of 20 cm, and a radius of the curve of approximately 15 cm. The "reduction end" of the probe is slightly concave. The instrument, with various curvatures, is illustrated in Figure 2.

The probe is introduced into the bone via a fenestration in the subchondylar cortex of the unfractured side of the tibial head, so that the probe will not affect the supporting cortical parts of the fractured condyle. The concave "reduction end" of the probe is placed in position beneath the compressed parts of the condyle, under TV-monitored x-ray control. The

Figure 2. Two probes, with different curvatures

compressed fracture region is reduced by repeated careful pushes of the probe (Figure 3). On its way, the probe transfers and compacts considerable amounts of cancellous bone from the region beneath the depression. The curvature of the probe permits some "swing" and this makes some minor adjustments of the reduction possible and also compacts and forms transverse bone bridges immediately beneath the fracture parts. This stabilizes the reduced fracture parts. The reduction may, if necessary, be further stabilized by several methods of internal fixation, e.g., by a wire technique, described by Gottfries et al. (1971), or by a plate device especially designed for this purpose (Figure 4). Only a short skin incision is needed for the reduction procedure. The surgery should be performed with the fractured leg slightly extended. The pre-operative set up is illustrated in Figure 5. A full-length circular knee-cast should be used for 4 to 6 weeks post-operatively in order to keep the fractured knee joint compartment protected.

"The probe is introduced into the bone via a fenestration in the subcondylar cortex of the unfractured side of the tibial head, so that the probe will not affect the supporting cortical parts of the fractured condyle."

Exhibit A-17, at p. 687

Case 1:04-cv-00204-JJF Document 196-16 Filed 04/27/2005 Page 3 of 10

Edeland Discloses the "Compacting" Step of Claim 1, as that Term is Construed by Kyphon

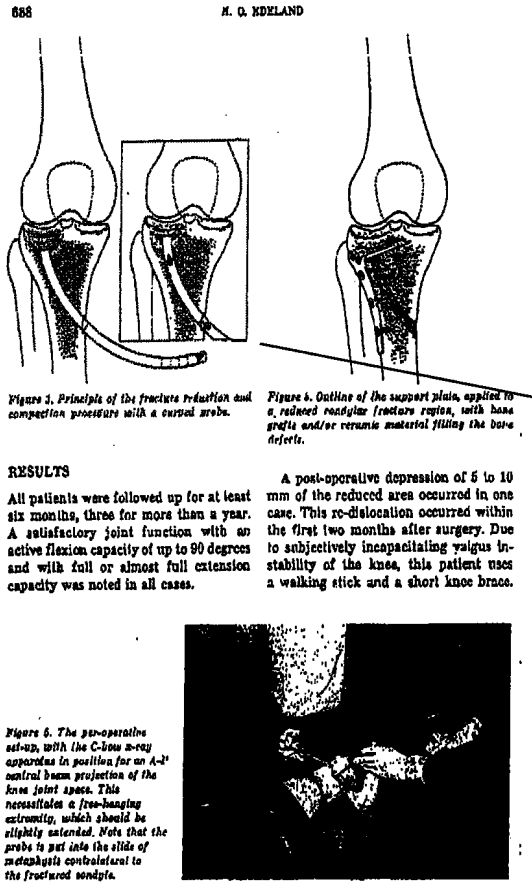

688 H. G. EDELAND

Figure 3. Principle of the fracture reduction and compaction procedure with a curved probe.

Figure 4. Outline of the support plate, applied to a reduced condylar fracture region, with bone grafts and/or ceramic material filling the bone defects.

RESULTS

All patients were followed up for at least six months, three for more than a year. A satisfactory joint function with an active flexion capacity of up to 90 degrees and with full or almost full extension capacity was noted in all cases.

A post-operative depression of 5 to 10 mm of the reduced area occurred in one case. This re-dislocation occurred within the first two months after surgery. Due to subjectively incapacitating valgus instability of the knee, this patient uses a walking stick and a short knee brace.

Figure 5. The per-operative set-up, with the C-bow x-ray apparatus in position for an A-P central beam projection of the knee joint space. This necessitates a free-hanging extremity, which should be slightly extended. Note that the probe is put into the slide of metaphysis contralateral to the fractured condyle.

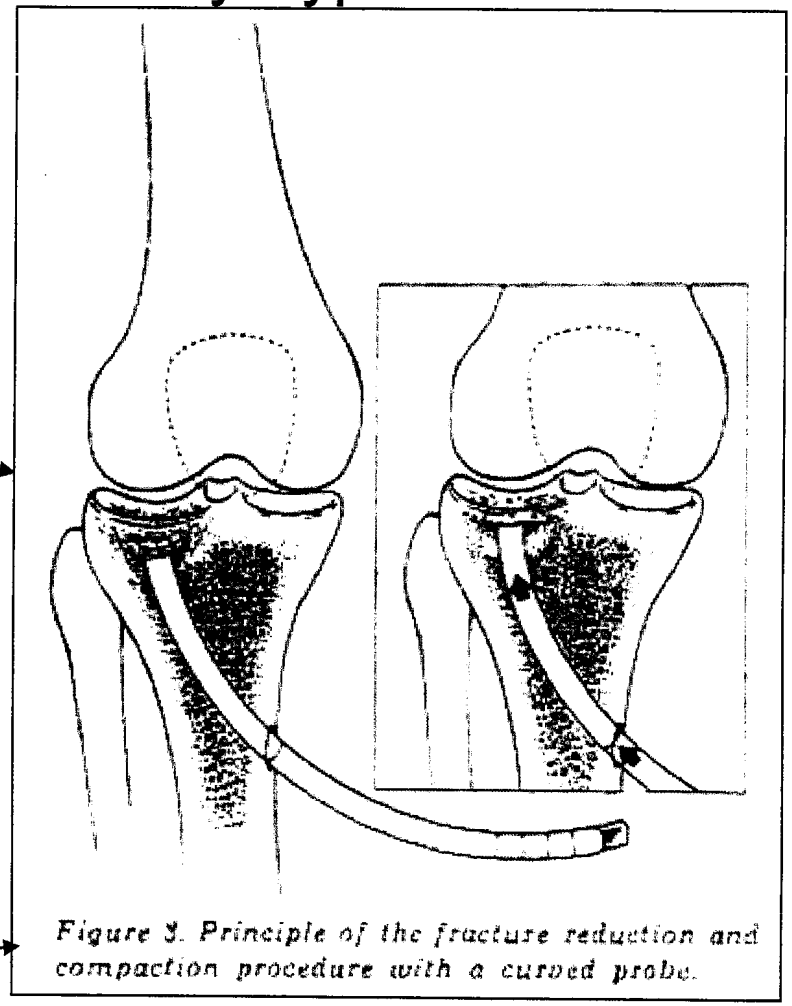

Figure 3. Principle of the fracture reduction and compaction procedure with a curved probe.

Exhibit A-17, at p. 688

"Figure 3. Principle of the fracture reduction and compaction procedure with a curved probe."

Case 1:04-cv-00204-JJF Document 196-16 Filed 04/27/2005 Page 4 of 10

Edeland Discloses the "Compacting" Step of Claim 1, as that Term is Construed by Kyphon

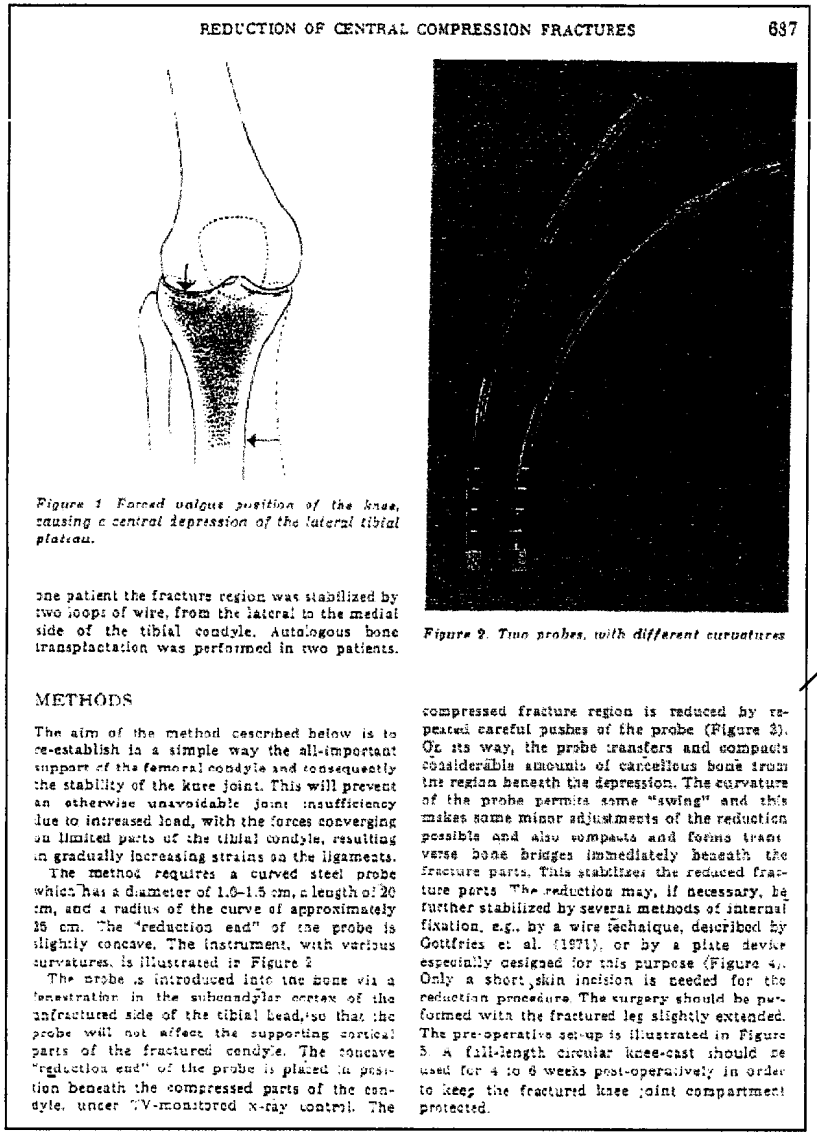

REDUCTION OF CENTRAL COMPRESSION FRACTURES 687

Figure 1. Forced valgus position of the knee, causing a central depression of the lateral tibial plateau.

Figure 2. Two probes, with different curvatures

one patient the fracture region was stabilized by two loops of wire, from the lateral to the medial side of the tibial condyle. Autologous bone transplantation was performed in two patients.

METHODS

The aim of the method described below is to re-establish in a simple way the all-important support of the femoral condyle and consequently the stability of the knee joint. This will prevent an otherwise unavoidable joint insufficiency due to increased load, with the forces converging on limited parts of the tibial condyle, resulting in gradually increasing strains on the ligaments.

The method requires a curved steel probe which has a diameter of 1.0–1.5 cm, a length of 20 cm, and a radius of the curve of approximately 35 cm. The "reduction end" of the probe is slightly concave. The instrument, with various curvatures, is illustrated in Figure 2.

The probe is introduced into the bone via a fenestration in the subchondylar cortex of the unfractured side of the tibial head, so that the probe will not affect the supporting cortical parts of the fractured condyle. The concave "reduction end" of the probe is placed in position beneath the compressed parts of the condyle, under TV-monitored x-ray control. The compressed fracture region is reduced by repeated careful pushes of the probe (Figure 3). On its way, the probe transfers and compacts considerable amounts of cancellous bone from the region beneath the depression. The curvature of the probe permits some "swing" and this makes some minor adjustments of the reduction possible and also compacts and forms transverse bone bridges immediately beneath the fracture parts. This stabilizes the reduced fracture parts. The reduction may, if necessary, be further stabilized by several methods of internal fixation, e.g., by a wire technique, described by Gottfries et al. (1971), or by a plate device especially designed for this purpose (Figure 4). Only a short skin incision is needed for the reduction procedure. The surgery should be performed with the fractured leg slightly extended. The pre-operative set-up is illustrated in Figure 5. A full-length circular knee-cast should be used for 4 to 6 weeks post-operatively in order to keep the fractured knee joint compartment protected.

Exhibit A-17, at p. 687

"The compressed fracture region is reduced by repeated careful pushes of the probe (Figure 3). On its way, the probe transfers and compacts considerable amounts of cancellous bone from the region beneath the depression."

Case 1:04-cv-00204-JJF Document 196-16 Filed 04/27/2005 Page 5 of 10

Compacting in Edeland is separate from forming the passage

- Passage: Probe is "introduced into the bone via a fenestration"
- Compacting occurs to increase the size of that passage
- Consistent with district court's finding:
  - "The Court finds that pushing the probe to compact cancellous bone could be read to 'increase the volume' of the passage."

Case 1:04-cv-00204-JJF Document 196-16 Filed 04/27/2005 Page 6 of 10

Edeland Discloses the "Filling the Passage" Step of Claim 1

"Instead of bone grafts to compensate for the bone defects, porous ceramic material could be used ... The ceramic material (e.g. tricalcium phosphate) could be introduced into the bone defect region by the use of a cylinder-and-piston type of instrument arrangement, as shown in Figure 6."

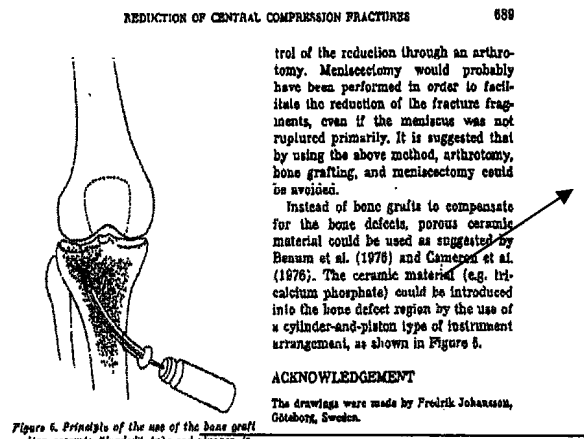

REDUCTION OF CENTRAL COMPRESSION FRACTURES 689

trol of the reduction through an arthrotomy. Meniscectomy would probably have been performed in order to facilitate the reduction of the fracture fragments, even if the meniscus was not ruptured primarily. It is suggested that by using the above method, arthrotomy, bone grafting, and meniscectomy could be avoided.

Instead of bone grafts to compensate for the bone defects, porous ceramic material could be used as suggested by Benum et al. (1976) and Cameron et al. (1976). The ceramic material (e.g. tricalcium phosphate) could be introduced into the bone defect region by the use of a cylinder-and-piston type of instrument arrangement, as shown in Figure 6.

Figure 6. Principle of the use of the bone graft and/or ceramic "loaded" tube-and-plunger instrument set-up.

All patients had sagittal stability. Two patients (one mentioned above) had some valgus instability. All patients were able to use stairs. No-one was troubled by night pains. One patient had permanent joint swelling. There have been no infections or serious general complications, such as venous thrombosis or pulmonary embolism.

DISCUSSION

The method described is probably only suitable for the treatment of uniformly depressed central condylar fractures. The alternative to the selected method would have implied a wider approach to the fracture area. This would have decreased the support of the fracture region even if bone grafts had been used. This standard method usually includes visual con-

ACKNOWLEDGEMENT

The drawings were made by Fredrik Johansson, Göteborg, Sweden.

REFERENCES

Benum, P., Lyng, Bø O., Hafn, I. & Heffner, J. D. W. (1976) Porous ceramics as a bone substitute in the medial condyle of the tibia. *Acta orthop. scand.* 47, 155–166.

Cameron, H. U., McNab, I. & Pilliar, R. M. (1976) Evaluation of a bio-degradable ceramic. Abstract, Program, 1976 Meeting, *American Society of Biomaterials*, p. 82.

Gelfriez, A., Hagert, C.-G. & Stressen, S. E. (1971) T- and Y-fractures of the tibial condyle. A follow-up study of cases treated by closed reduction and surgical fixation with a wire loop. *Injury* 2,2, 84–93.

Hohl, M. (1967) Tibial condylar fractures. *J. Bone Jt Surg.* 49-A, 1455–1467.

Kennedy, J. C. & Bailey, W. H. (1968) Experimental tibial-plateau fractures. Studies of the mechanism and a classification. *J. Bone Jt Surg.* 50-A, 1522–1534.

Maquet, P., Simonet, J. & de Marchin, P. (1967) Biomécanique du genou et gonarthroses. *Rev. Chir. orthop.* 53, 117–138.

Rasmussen, P. S. (1973) Tibial condylar fractures. Impairment of knee joint stability as an indication for surgical treatment. *J. Bone Jt Surg.* 55-A, 1331–1350.

Correspondence to: H. O. Edeland, M.D., Department of Orthopaedic Surgery, Central Hospital, S-431 22 Mölndal, Sweden.

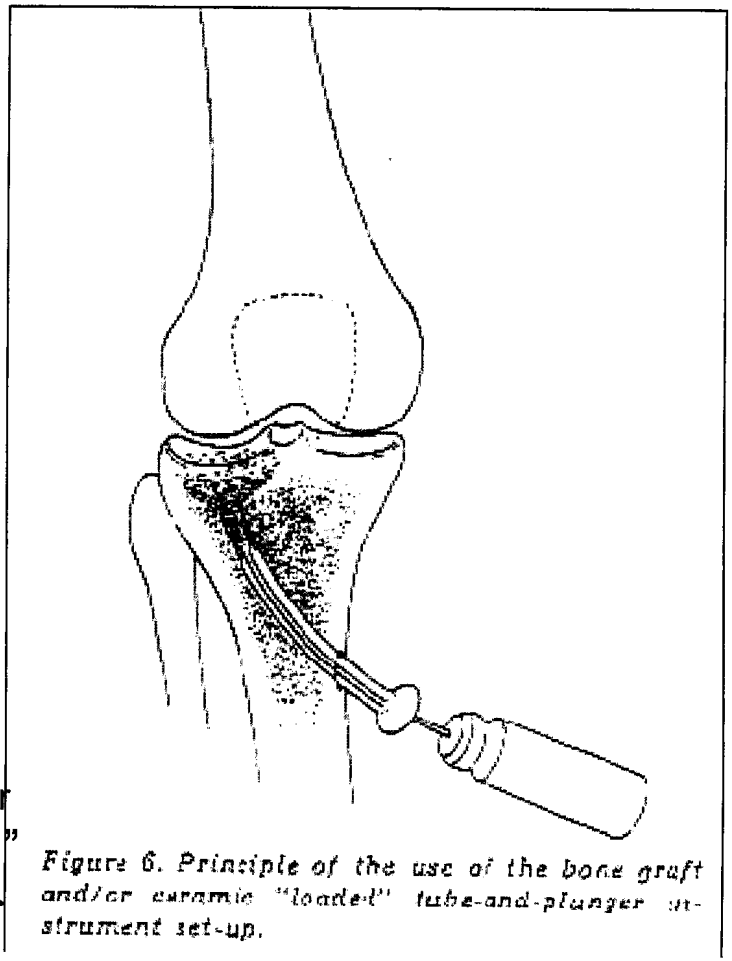

Figure 6. Principle of the use of the bone graft and/or ceramic "loaded" tube-and-plunger instrument set-up.

Figure 6. Principle of the use of the bone graft and/or ceramic 'loaded' tube-and-plunger instrument set-up."

Case 1:04-cv-00204-JJF Document 196-16 Filed 04/27/2005 Page 7 of 10

Edeland Discloses the "Filling the Passage" Step of Claim 1

- Calcium phosphate ceramics constitute "flowable material" capable of setting to a hardened condition.
  - The ceramic material can be made into a slurry by suspension in a liquid medium.
  - The slurry can be inserted into bone via a tube-and-plunger instrument or bone filler device.
  - The slurry hardens over time and becomes bone.

[1] Exhibit E, Mitchell Decl., ¶ ¶ 11, 12

Case 1:04-cv-00204-JJF Document 196-16 Filed 04/27/2005 Page 8 of 10

It Would Be Safe -- and Obvious -- to Fill the Edeland Void With Other Flowable Materials Including Methyl Methacrylate

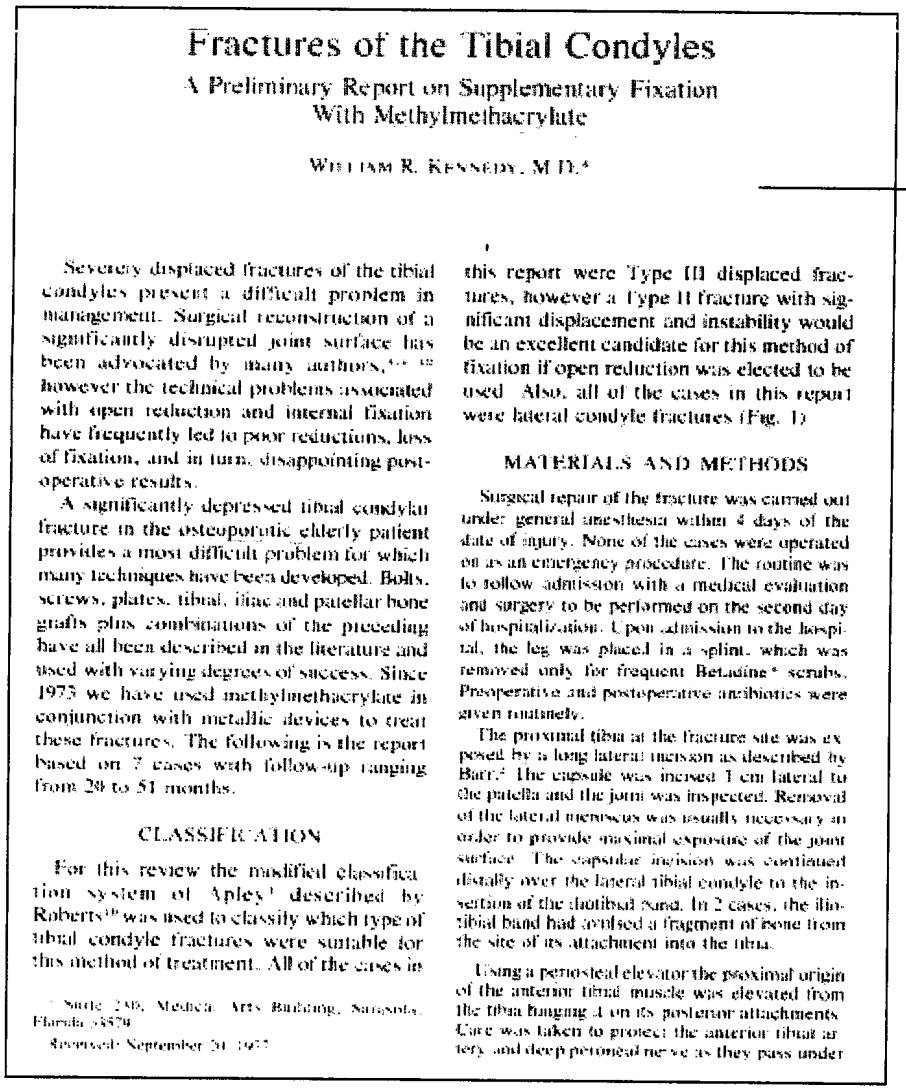

Fractures of the Tibial Condyles

A Preliminary Report on Supplementary Fixation With Methylmethacrylate

WILLIAM R. KENNEDY, M.D.*

Severely displaced fractures of the tibial condyles present a difficult problem in management. Surgical reconstruction of a significantly disrupted joint surface has been advocated by many authors,[1-3, 10] however the technical problems associated with open reduction and internal fixation have frequently led to poor reductions, loss of fixation, and in turn, disappointing postoperative results.

A significantly depressed tibial condylar fracture in the osteoporotic elderly patient provides a most difficult problem for which many techniques have been developed. Bolts, screws, plates, tibial, iliac and patellar bone grafts plus combinations of the preceding have all been described in the literature and used with varying degrees of success. Since 1973 we have used methylmethacrylate in conjunction with metallic devices to treat these fractures. The following is the report based on 7 cases with follow-up ranging from 28 to 51 months.

CLASSIFICATION

For this review the modified classification system of Apley[1] described by Roberts[10] was used to classify which type of tibial condyle fractures were suitable for this method of treatment. All of the cases in this report were Type III displaced fractures, however a Type II fracture with significant displacement and instability would be an excellent candidate for this method of fixation if open reduction was elected to be used. Also, all of the cases in this report were lateral condyle fractures (Fig. 1).

MATERIALS AND METHODS

Surgical repair of the fracture was carried out under general anesthesia within 4 days of the date of injury. None of the cases were operated on as an emergency procedure. The routine was to follow admission with a medical evaluation and surgery to be performed on the second day of hospitalization. Upon admission to the hospital, the leg was placed in a splint, which was removed only for frequent Betadine® scrubs. Preoperative and postoperative antibiotics were given routinely.

The proximal tibia at the fracture site was exposed by a long lateral incision as described by Barr.[2] The capsule was incised 1 cm lateral to the patella and the joint was inspected. Removal of the lateral meniscus was usually necessary in order to provide maximal exposure of the joint surface. The capsular incision was continued distally over the lateral tibial condyle to the insertion of the tibialis anticus. In 2 cases, the iliotibial band had avulsed a fragment of bone from the site of its attachment into the tibia.

Using a periosteal elevator the proximal origin of the anterior tibial muscle was elevated from the tibia hinging it on its posterior attachments. Care was taken to protect the anterior tibial artery and deep peroneal nerve as they pass under

* Suite 230, Medical Arts Building, Sarasota, Florida 33578

Received: September 20, 1977

Fractures of the Tibial Condyles

A Preliminary Report on Supplementary Fixation With Methylmethacrylate

WILLIAM R. KENNEDY, M.D.*

Kennedy article is dated July-August 1978: More than 10 years before the filing date for the '888 Patent

Exhibit A-18

Case 1:04-cv-00204-JJF Document 196-16 Filed 04/27/2005 Page 9 of 10

It Would Be Safe to Fill the Edeland Void With Methyl Methacrylate

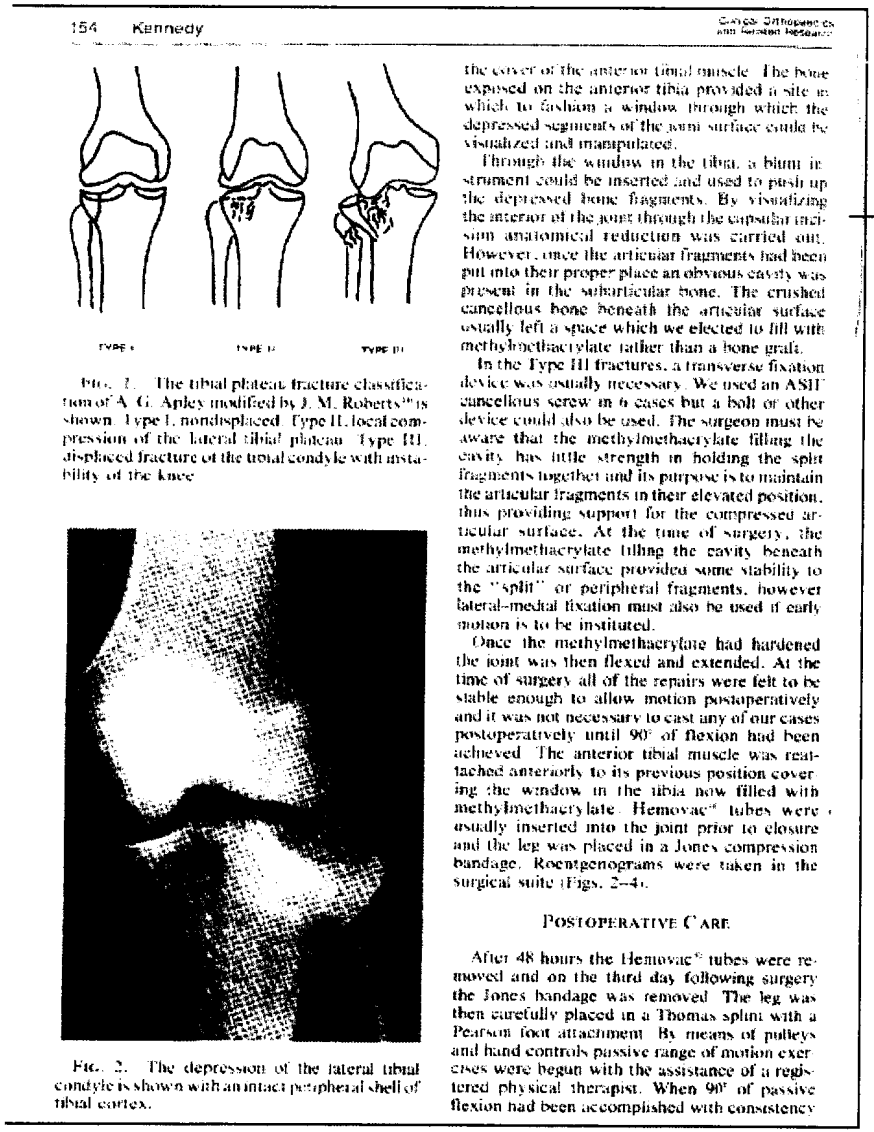

154 Kennedy

FIG. 1. The tibial plateau fracture classification of A. G. Apley modified by J. M. Roberts[10] is shown. Type I, nondisplaced. Type II, local compression of the lateral tibial plateau. Type III, displaced fracture of the tibial condyle with instability of the knee.

FIG. 2. The depression of the lateral tibial condyle is shown with an intact peripheral shell of tibial cortex.

the cover of the anterior tibial muscle. The bone exposed on the anterior tibia provided a site in which to fashion a window through which the depressed segments of the joint surface could be visualized and manipulated.

Through the window in the tibia, a blunt instrument could be inserted and used to push up the depressed bone fragments. By visualizing the interior of the joint through the capsular incision anatomical reduction was carried out. However, once the articular fragments had been put into their proper place an obvious cavity was present in the subarticular bone. The crushed cancellous bone beneath the articular surface usually left a space which we elected to fill with methylmethacrylate rather than a bone graft.

In the Type III fractures, a transverse fixation device was usually necessary. We used an ASIF cancellous screw in 6 cases but a bolt or other device could also be used. The surgeon must be aware that the methylmethacrylate filling the cavity has little strength in holding the split fragments together and its purpose is to maintain the articular fragments in their elevated position, thus providing support for the compressed articular surface. At the time of surgery, the methylmethacrylate filling the cavity beneath the articular surface provided some stability to the "split" or peripheral fragments, however lateral-medial fixation must also be used if early motion is to be instituted.

Once the methylmethacrylate had hardened the joint was then flexed and extended. At the time of surgery all of the repairs were felt to be stable enough to allow motion postoperatively and it was not necessary to cast any of our cases postoperatively until 90° of flexion had been achieved. The anterior tibial muscle was reattached anteriorly to its previous position covering the window in the tibia now filled with methylmethacrylate. Hemovac® tubes were usually inserted into the joint prior to closure and the leg was placed in a Jones compression bandage. Roentgenograms were taken in the surgical suite (Figs. 2–4).

POSTOPERATIVE CARE

After 48 hours the Hemovac® tubes were removed and on the third day following surgery the Jones bandage was removed. The leg was then carefully placed in a Thomas splint with a Pearson foot attachment. By means of pulleys and hand controls passive range of motion exercises were begun with the assistance of a registered physical therapist. When 90° of passive flexion had been accomplished with consistency

"Through the window in the tibia, a blunt instrument could be inserted and used to push up the depressed bone fragments. . . . The crushed cancellous bone beneath the articular surface usually left a space which we elected to fill with methylmethacrylate rather than a bone graft."

Exhibit A-18, at p. 184

Kennedy has same the disclosure as Edeland – except methyl methacrylate bone cement filled the void instead of bone graft paste.

Case 1:04-cv-00204-JJF Document 196-16 Filed 04/27/2005 Page 10 of 10