Redacted

Redacted

Would Have Been Obvious to Use PMMA as well

- By February 1989 ('888 Filing date), PMMA well known for filling voids in bone fractures
- Kennedy – 1978 – PMMA used in the Edeland procedure

Case 1:04-cv-00204-JJF Document 196-15 Filed 04/27/2005 Page 3 of 10

Kyphon's Expert Used PMMA to Fill Bone Voids Prior to '888 Patent

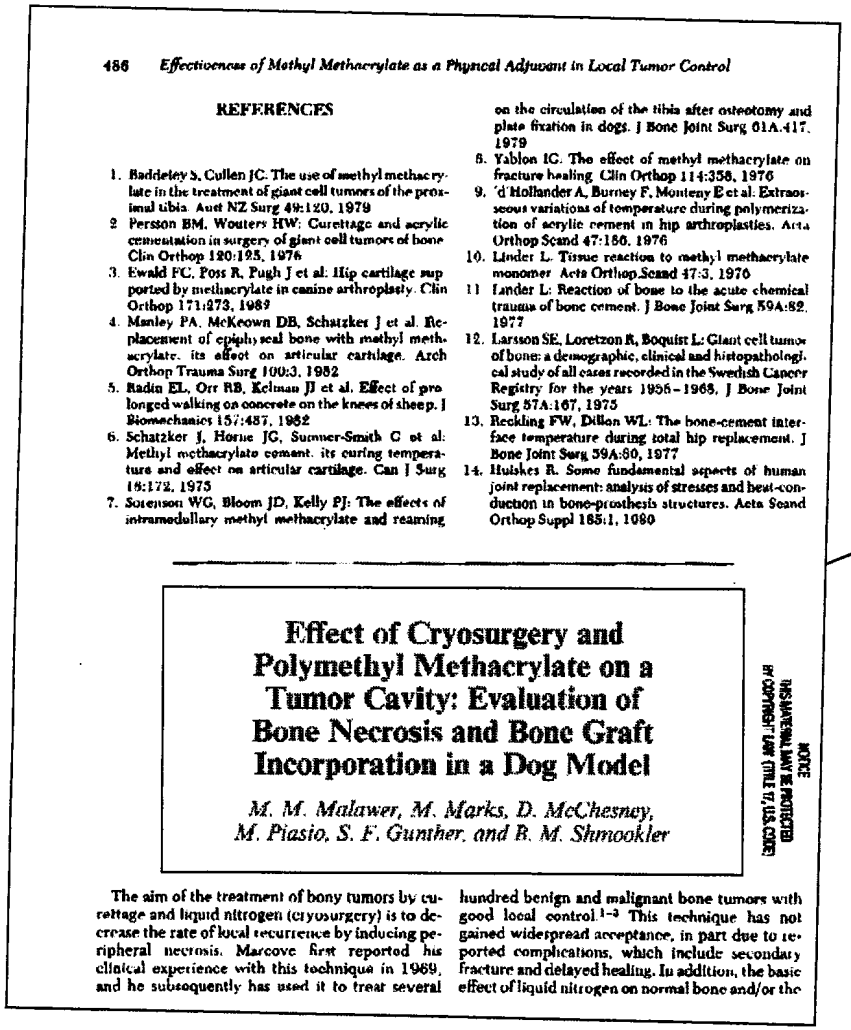

486 *Effectiveness of Methyl Methacrylate as a Physical Adjuvant in Local Tumor Control*

REFERENCES

1. Baddeley S, Cullen JC: The use of methyl methacrylate in the treatment of giant cell tumors of the proximal tibia. Aust NZ Surg 49:120, 1979
2. Persson BM, Wouters HW: Curettage and acrylic cementation in surgery of giant cell tumors of bone. Clin Orthop 120:195, 1976
3. Ewald FC, Poss R, Pugh J et al: Hip cartilage supported by methacrylate in canine arthroplasty. Clin Orthop 171:273, 1989
4. Manley PA, McKeown DB, Schatzker J et al: Replacement of epiphyseal bone with methyl methacrylate: its effect on articular cartilage. Arch Orthop Trauma Surg 100:3, 1982
5. Radin EL, Orr RB, Kelman JJ et al: Effect of prolonged walking on concrete on the knees of sheep. J Biomechanics 15:487, 1982
6. Schatzker J, Horne JG, Sumner-Smith G et al: Methyl methacrylate cement: its curing temperature and effect on articular cartilage. Can J Surg 18:172, 1975
7. Sorenson WG, Bloom JD, Kelly PJ: The effects of intramedullary methyl methacrylate and reaming on the circulation of the tibia after osteotomy and plate fixation in dogs. J Bone Joint Surg 61A:417, 1979
8. Yablon IG: The effect of methyl methacrylate on fracture healing. Clin Orthop 114:358, 1976
9. 'd'Hollander A, Burney F, Monteny E et al: Extraosseous variations of temperature during polymerization of acrylic cement in hip arthroplasties. Acta Orthop Scand 47:150, 1976
10. Linder L: Tissue reaction to methyl methacrylate monomer. Acta Orthop Scand 47:3, 1976
11. Linder L: Reaction of bone to the acute chemical trauma of bone cement. J Bone Joint Surg 59A:82, 1977
12. Larsson SE, Lorentzon R, Boquist L: Giant cell tumor of bone: a demographic, clinical and histopathological study of all cases recorded in the Swedish Cancer Registry for the years 1956–1968. J Bone Joint Surg 57A:167, 1975
13. Reckling FW, Dillon WL: The bone-cement interface temperature during total hip replacement. J Bone Joint Surg 59A:80, 1977
14. Huiskes R: Some fundamental aspects of human joint replacement: analysis of stresses and heat-conduction in bone-prosthesis structures. Acta Scand Orthop Suppl 185:1, 1980

Effect of Cryosurgery and Polymethyl Methacrylate on a Tumor Cavity: Evaluation of Bone Necrosis and Bone Graft Incorporation in a Dog Model

M. M. Malawer, M. Marks, D. McChesney, M. Piasio, S. F. Gunther, and B. M. Shmookler

NOTICE THIS MATERIAL MAY BE PROTECTED BY COPYRIGHT LAW (TITLE 17, U.S. CODE)

The aim of the treatment of bony tumors by curettage and liquid nitrogen (cryosurgery) is to decrease the rate of local recurrence by inducing peripheral necrosis. Marcove first reported his clinical experience with this technique in 1969, and he subsequently has used it to treat several hundred benign and malignant bone tumors with good local control.[1–3] This technique has not gained widespread acceptance, in part due to reported complications, which include secondary fracture and delayed healing. In addition, the basic effect of liquid nitrogen on normal bone and/or the

Effect of Cryosurgery and Polymethyl Methacrylate on a Tumor Cavity: Evaluation of Bone Necrosis and Bone Graft Incorporation in a Dog Model

M. M. Malawer, M. Marks, D. McChesney, M. Piasio, S. F. Gunther, and B. M. Shmookler

1987 Article

(Exhibit E-4)

Case 1:04-cv-00204-JJF Document 196-15 Filed 04/27/2005 Page 4 of 10

Kyphon's Expert Used PMMA to Fill Bone Voids Prior to '888 Patent

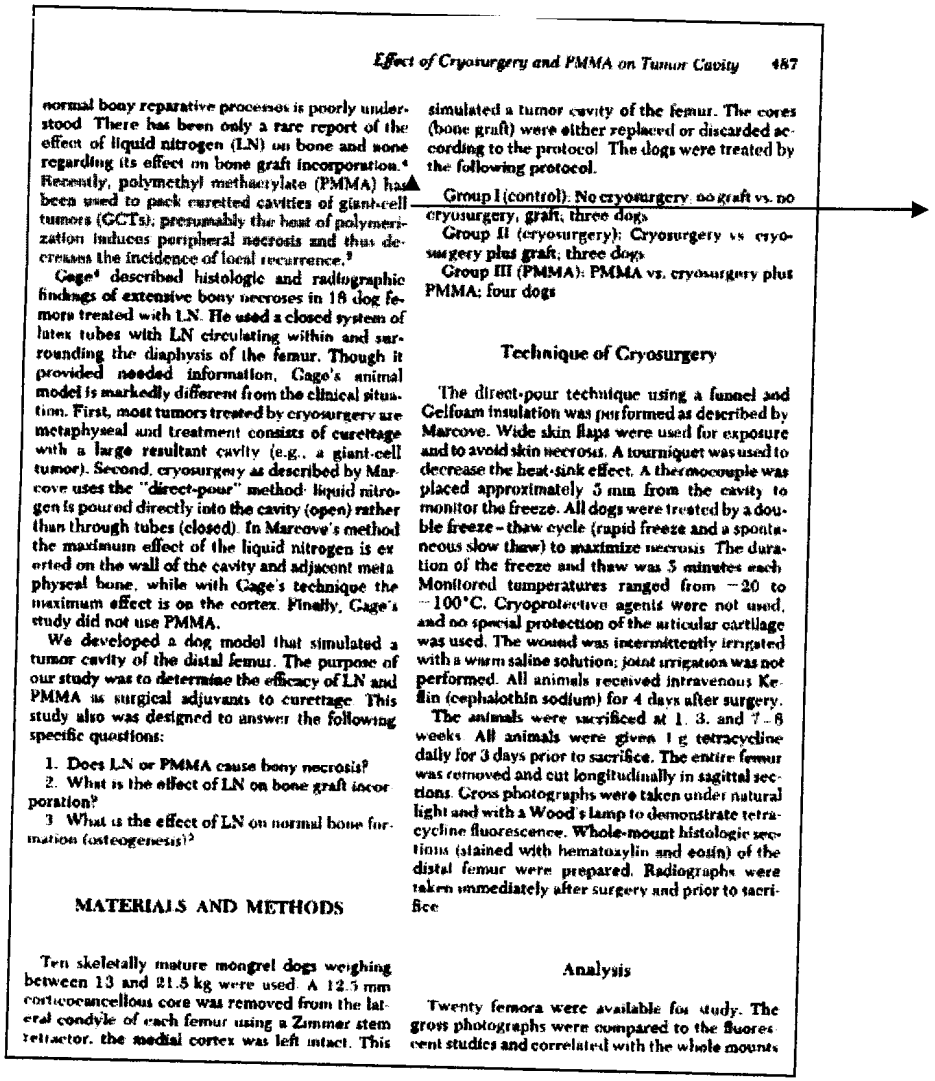

Effect of Cryosurgery and PMMA on Tumor Cavity 487

normal bony reparative processes is poorly understood. There has been only a rare report of the effect of liquid nitrogen (LN) on bone and none regarding its effect on bone graft incorporation.[4] Recently, polymethyl methacrylate (PMMA) has been used to pack curetted cavities of giant-cell tumors (GCTs); presumably the heat of polymerization induces peripheral necrosis and thus decreases the incidence of local recurrence.[5]

Cage[4] described histologic and radiographic findings of extensive bony necroses in 18 dog femora treated with LN. He used a closed system of latex tubes with LN circulating within and surrounding the diaphysis of the femur. Though it provided needed information, Cage's animal model is markedly different from the clinical situation. First, most tumors treated by cryosurgery are metaphyseal and treatment consists of curettage with a large resultant cavity (e.g., a giant-cell tumor). Second, cryosurgery as described by Marcove uses the "direct-pour" method: liquid nitrogen is poured directly into the cavity (open) rather than through tubes (closed). In Marcove's method the maximum effect of the liquid nitrogen is exerted on the wall of the cavity and adjacent metaphyseal bone, while with Cage's technique the maximum effect is on the cortex. Finally, Cage's study did not use PMMA.

We developed a dog model that simulated a tumor cavity of the distal femur. The purpose of our study was to determine the efficacy of LN and PMMA as surgical adjuvants to curettage. This study also was designed to answer the following specific questions:

1. Does LN or PMMA cause bony necrosis?
2. What is the effect of LN on bone graft incorporation?
3. What is the effect of LN on normal bone formation (osteogenesis)?

MATERIALS AND METHODS

Ten skeletally mature mongrel dogs weighing between 13 and 21.5 kg were used. A 12.5 mm corticocancellous core was removed from the lateral condyle of each femur using a Zimmer stem reflector, the medial cortex was left intact. This simulated a tumor cavity of the femur. The cores (bone graft) were either replaced or discarded according to the protocol. The dogs were treated by the following protocol.

Group I (control): No cryosurgery, no graft vs. no cryosurgery, graft; three dogs.

Group II (cryosurgery): Cryosurgery vs. cryosurgery plus graft; three dogs.

Group III (PMMA): PMMA vs. cryosurgery plus PMMA; four dogs.

Technique of Cryosurgery

The direct-pour technique using a funnel and Gelfoam insulation was performed as described by Marcove. Wide skin flaps were used for exposure and to avoid skin necrosis. A tourniquet was used to decrease the heat-sink effect. A thermocouple was placed approximately 5 mm from the cavity to monitor the freeze. All dogs were treated by a double freeze–thaw cycle (rapid freeze and a spontaneous slow thaw) to maximize necrosis. The duration of the freeze and thaw was 5 minutes each. Monitored temperatures ranged from −20 to −100°C. Cryoprotective agents were not used, and no special protection of the articular cartilage was used. The wound was intermittently irrigated with a warm saline solution; joint irrigation was not performed. All animals received intravenous Keflin (cephalothin sodium) for 4 days after surgery.

The animals were sacrificed at 1, 3, and 7–8 weeks. All animals were given 1 g tetracycline daily for 3 days prior to sacrifice. The entire femur was removed and cut longitudinally in sagittal sections. Gross photographs were taken under natural light and with a Wood's lamp to demonstrate tetracycline fluorescence. Whole-mount histologic sections (stained with hematoxylin and eosin) of the distal femur were prepared. Radiographs were taken immediately after surgery and prior to sacrifice.

Analysis

Twenty femora were available for study. The gross photographs were compared to the fluorescent studies and correlated with the whole mounts.

Recently, polymethyl methacrylate (PMMA) has been used to pack curetted cavities of giant-cell tumors (GCTs); presumably the heat of polymerization induces peripheral necrosis and thus decreases the incidence of local recurrence.[5]

Marks' article notes the use of methyl methacrylate bone cement (PMMA) to pack large cavities created by curettes.

Thus, methyl methacrylate bone cement was known to fill bone voids before the '888 Patent

Case 1:04-cv-00204-JJF Document 196-15 Filed 04/27/2005 Page 5 of 10

Olerud Discloses the Claim 3 Limitation: "compacting step includes forcing the bone marrow outwardly of the central portion of the bone"

relatively easily with a pair of tongs. The screw grips are then locked to the bolt grips by means of the conical screws. When the threaded rods are rotated, the fractured vertebra is distracted (Fig. 2) until the height of the vertebral body is restored to normal.

Subsequently, the threaded rods are locked to the bolt grips. If the posterior articular system is undamaged, the two segments around the fractured vertebra will be adequately stabilized. If any intervertebral joints or vertebral arches are fractured, however, some instability will remain in bending and in rotation. With the use of two diagonal cerclage wires between the two units of the instrument, adequate stability can be achieved.

On reduction of a compressed vertebral body, defects will occur in the cancellous bone (as in compression fractures in tibial condyles). Similarly, with the insertion of transpedicular screws, a hole can be made with a 5-mm drill through one of the pedicles of the fractured vertebra into the vertebral body. A slightly curved punch is brought through the pedicle into the vertebral body (Fig. 3) under fluoroscopic control with the image intensifier, the end plates and anterior wall of the vertebra are reduced, if possible. An aural speculum is inserted into the pedicular hole and a cancellous bone graft—bone paste obtained from the posterior aspect of the iliac crest with an acetabular reamer[14]—is pressed into the vertebra.[8]

Posterolateral fusions are only rarely performed, i.e., in cases of facet fractures and after a laminectomy. Preoperative myelography or computed tomography (CT) scans will reveal any fragments that have been displaced into the spinal canal. If there is a burst fracture, the fragment can often be reduced with only distraction. Otherwise, with a minor laminectomy such a fragment can be identified by fluoroscopy with an image intensifier and with the aid of an elevator inserted at the side of the dura. Using the PSF, the fragment can then be pressed back into the vertebral body. If this is not possible, a limited laminectomy can be performed after removal of the threaded rod on one side. Any fracture fragments can then be reduced or any fragments present in the spinal canal extracted without any effect on the dura. The removed threaded rod is subsequently reinserted. The reduction usually is not jeopardized by short-term intraoperative dismantling of one of the device units, because the patient is in hyperextension. If desirable, intraoperative myelography can be performed as a check. After operation, the patients can often be mobilized immediately without any external support or, in a few cases, with a simple three-point brace.[13]

At follow-up examination the reduction effect was measured by comparing the anterior height of the injured vertebra with the calculated height of the same vertebra (the mean value of the vertebra above and the one below the injured vertebra). The reduction effect was also estimated by comparing the Cobb angle.

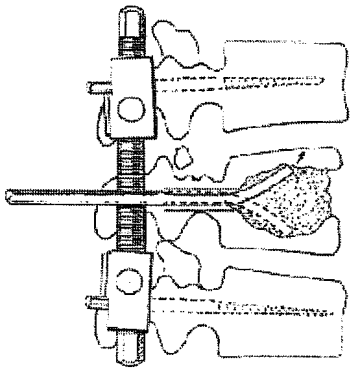

FIG. 3. With a transpedicularly introduced punch, further reduction of fragments in the vertebral body can be reduced. The defect in the vertebra is then filled with a graft in the form of bone paste.[8,15]

PATIENTS

This series consisted of 20 consecutive patients with thoracolumbar burst fractures (14 men and six women) aged 16–59 years (average, 35 years). All fractures had been caused by high-energy trauma, mainly traffic accidents (13 patients). Ten of the patients had neurologic symptoms on admission but only one had complete paraplegia. The injured vertebrae were T12 in three, L1 in five, L2 in four, L3 in two, and L4 in five patients (Table 1).

When classified according to Denis,[3] three fractures were of Type A, 14 of Type B, two of Type D, and one of Type E.

Two patients were treated at a relatively late stage (19 and 45 days, respectively) after injury, and the remaining 18 patients were treated within five days of injury. Of these, seven had surgery on the day of injury.

All were treated with open reduction and fixation with the PSF in the manner described above.

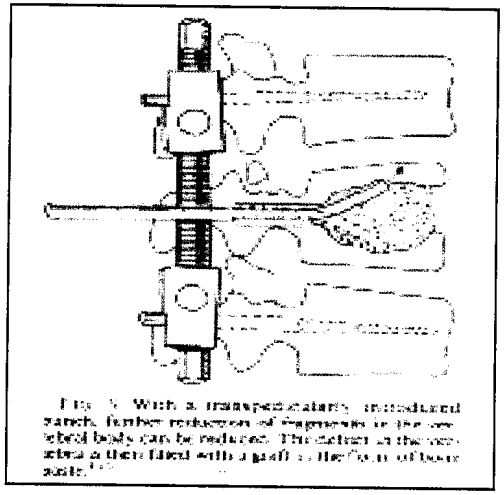

FIG. 3. With a transpedicularly introduced punch, further reduction of fragments in the vertebral body can be reduced. The defect in the vertebra is then filled with a graft in the form of bone paste.[8,15]

Fig. 3 provides a snapshot of a push of probe that is repeated in different areas of the bone, from the center to the outer portion of bone, both upwards and downwards.

Kyphon's contention that the procedure is limited to the periphery of bone is without merit.

Case 1:04-cv-00204-JJF Document 196-15 Filed 04/27/2005 Page 6 of 10

Olerud Discloses the Drilling Limitations of Claims 8, 9 and 10 (drilling into bone marrow, under guidance, to a predetermined depth)

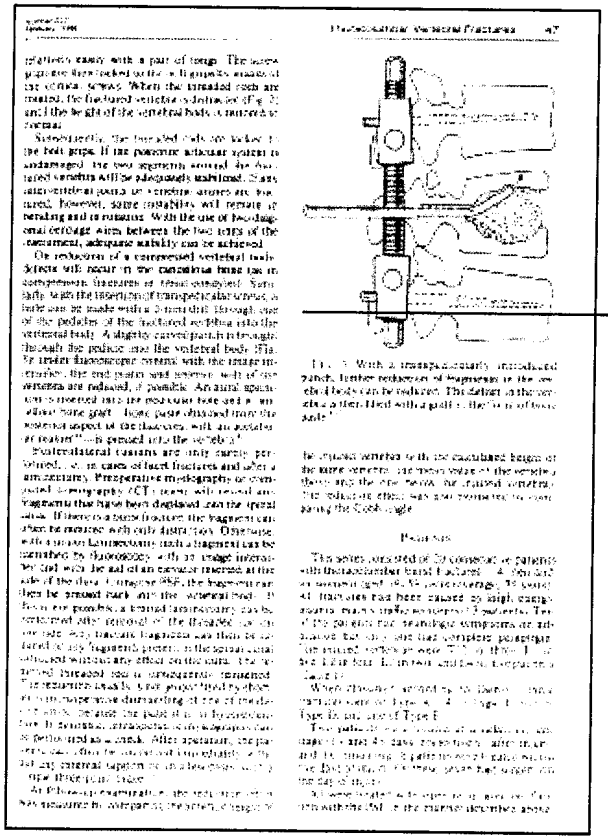

"[A] hole can be made with a 5-mm drill through one of the pedicles of the fractured vertebra, into the vertebral body. A slightly curved punch is brought through the pedicle into the vertebral body (Fig. 3); under fluoroscopic control with the image intensifier, the end plates and anterior wall of the vertebra are reduced, if possible."

Kyphon's expert, Dr. Marks, does not dispute this fact.[1]

[1]Exhibit V, pp. 10-12

Olerud Discloses the "Vertebral Fracture" Limitation of Claim 12

Transpedicular Fixation of Thoracolumbar Vertebral Fractures

SVEN OLERUD, M.D.,* GÖRAN KARLSTRÖM, M.D.,** AND LENNART SJÖSTRÖM, M.D.†

The most frequent surgical treatment of thoracolumbar fractures is still the Harrington rod system despite some adverse effects, the most serious being the locking of five to seven segments. The new pedicular fixation modifications suggested by Magerl and Dick lock only two segments and give far better stability of the fractures. Used internally, the system is convenient for the patient, permitting early mobilization, often without any external support. The instrument, called the "posterior segmental fixator" (PSF), is used both as a reduction device and as a fixation device. The injured vertebra is grafted through the pedicle, giving security against late collapse after device removal. Twenty patients treated with this method had an average follow-up period of ten months. The primary reduction attains 88% of the calculated height of the injured vertebra, with only a few percent loss during follow-up time. Clearance of fragments in the spinal canal, diagnosed with computed tomography scan in eight patients, was successfully accomplished in all but one, with only distraction or reduction of the fragment through a limited laminotomy. The instrumentation in these cases was lateral to the dura. Nine patients with neurologic deficits improved and could walk without support or with crutches within a few months. One patient with complete paraplegia remained unchanged.

The main goals of surgical treatment of thoracolumbar vertebral fractures are to achieve reduction, stability, and early, painless mobilization. It is assumed, though not proven, that stable fracture fixation and decompression of nerve structures facilitate the restoration of neurologic deficits,[4,5,16-19,22,24,25,27,33] A further aim is to avoid late malpositions and to preserve lumbar mobility and posture.[11,37,38,42]

Harrington instrumentation and similar methods are currently the most commonly used fixations for thoracolumbar fractures.[2,7,12,21,39,40,43] However, fracture treatment with the Harrington device has certain limitations. The main disadvantage is that this device fixates five to seven vertebrae, resulting in negative effects on mobility. This negative effect is greater the farther down in the lumbar spine the fracture is located. Furthermore, in the postoperative period a brace is needed for mobilization of the patient during healing time to avoid instrument failures.[21,39] Moreover, the patient is not allowed to sit for six months.

Instability, instrument failures, and correction losses have been reported.[1,5,15,23,32,41,45] Some loss of correction may occur after removal of the distraction devices, so that the end result is often roughly similar to the original deformation.[1,28,36]

Roy-Camille and co-workers' transpedicular screw fixations of plates[37,38] paved the way for Magerl's external fixation of vertebral fractures with the aid of transpedicular screws[30,31] and for posterior segmental fixation with an internal fixator.[1-13] This instrumentation, according to Dick, seems to have

From the Department of Orthopaedic Surgery, Uppsala University, Uppsala Hospital.
* Professor and Chairman, Orthopaedic Department, University of Uppsala.
** Associate Professor.
† Fellow.
Reprint requests to Sven Olerud, M.D., Department of Orthopaedic Surgery, University Hospital, S-751 85 Uppsala, Sweden.
Received: April 13, 1987.

Transpedicular Fixation of Thoracolumbar Vertebral Fractures

Case 1:04-cv-00204-JJF Document 196-15 Filed 04/27/2005 Page 8 of 10

Edeland Anticipates Every Limitation of Claims 1, 3, 8, 9 and 10 of the '404 Patent

1. A method of fixation of a fracture or impending fracture of a bone having bone marrow therein comprising:

forming a passage in the bone marrow;

compacting the bone marrow to increase the volume of said passage; and

filling the passage with a flowable material capable of setting to a hardened condition.

3. A method as set forth in claim 1, wherein said compacting step includes forcing the bone marrow outwardly of the central portion of the bone.

Case 1:04-cv-00204-JJF Document 196-15 Filed 04/27/2005 Page 9 of 10

Edeland Anticipates Every Limitation of Claims 1, 3, 8, 9 and 10 of the '404 Patent

8. A method as set forth in claim 1, wherein said forming step includes drilling said bone marrow to form said passage.

9. A method as set forth in claim 8, wherein said drilling step includes guiding a drill through and into the proximate cortical bone marrow.

10. A method as set forth in claim 8, wherein said forming step includes drilling the bone marrow to a predetermined depth.

15. [DOT is no longer asserting anticipation of claim 15, as that claim requires "liquid" synthetic bone.]

Case 1:04-cv-00204-JJF Document 196-15 Filed 04/27/2005 Page 10 of 10