Olerud Anticipates Every Limitation of Claims 1, 3, 8, 9, 10 and 12 of the '404 Patent

1. A method of fixation of a fracture or impending fracture of a bone having bone marrow therein comprising:

forming a passage in the bone marrow;

compacting the bone marrow to increase the volume of said passage; and

filling the passage with a flowable material capable of setting to a hardened condition.

3. A method as set forth in claim 1, wherein said compacting step includes forcing the bone marrow outwardly of the central portion of the bone.

Case 1:04-cv-00204-JJF Document 196-14 Filed 04/27/2005 Page 1 of 10

Olerud Anticipates Every Limitation of Claims 1, 3, 8, 9, 10 and 12 of the '404 Patent

8. A method as set forth in claim 1, wherein said forming step includes drilling said bone marrow to form said passage.

9. A method as set forth in claim 8, wherein said drilling step includes guiding a drill through and into the proximate cortical bone marrow.

10. A method as set forth in claim 8, wherein said forming step includes drilling the bone marrow to a predetermined depth.

12. A method as set forth in claim 1, wherein the fracture is a fracture of a vertebral body of the human spine.

Case 1:04-cv-00204-JJF Document 196-14 Filed 04/27/2005 Page 2 of 10

Redacted

Case 1:04-cv-00204-JJF Document 196-14 Filed 04/27/2005 Page 3 of 10

Redacted

Case 1:04-cv-00204-JJF Document 196-14 Filed 04/27/2005 Page 4 of 10

Olerud Predates the Effective Filing Date and Discloses the Preamble of Claim 1: "method of fixation of a fracture"

Transpedicular Fixation of Thoracolumbar Vertebral Fractures

SVEN OLERUD, M.D.,* GÖRAN KARLSTRÖM, M.D.,** AND LENNART SJÖSTRÖM, M.D.†

The most frequent surgical treatment of thoracolumbar fractures is still the Harrington rod system despite some adverse effects, the most serious being the locking of five to seven segments. The new pedicular fixation modifications suggested by Magerl and Dick lock only two segments and give far better stability of the fractures. Used internally, the system is convenient for the patient, permitting early mobilization, often without any external support. The instrument, called the "posterior segmental fixator" (PSF), is used both as a reduction device and as a fixation device. The injured vertebra is grafted through the pedicle, giving security against late collapse after device removal. Twenty patients treated with this method had an average follow-up period of ten months. The primary reduction attains 88% of the calculated height of the injured vertebra, with only a few percent loss during follow-up time. Clearance of fragments in the spinal canal, diagnosed with computed tomography scan in eight patients, was successfully accomplished in all but one, with only distraction or reduction of the fragment through a limited laminotomy. The instrumentation in these cases was lateral to the dura. Nine patients with neurologic deficits improved and could walk without support or with crutches within a few months. One patient with complete paraplegia remained unchanged.

The main goals of surgical treatment of thoracolumbar vertebral fractures are to achieve reduction, stability, and early, painless mobilization. It is assumed, though not proven, that stable fracture fixation and decompression of nerve structures facilitate the restoration of neurologic deficits.[4,5,16-19,22,24,25,27,33] A further aim is to avoid late malpositions and to preserve lumbar mobility and posture.[11,37,38,42]

Harrington instrumentation and similar methods are currently the most commonly used fixations for thoracolumbar fractures.[2,7,12,21,39,40,43] However, fracture treatment with the Harrington device has certain limitations. The main disadvantage is that this device fixates five to seven vertebrae, resulting in negative effects on mobility. This negative effect is greater the farther down in the lumbar spine the fracture is located. Furthermore, in the postoperative period a brace is needed for mobilization of the patient during healing time to avoid instrument failures.[21,39] Moreover, the patient is not allowed to sit for six months.

Instability, instrument failures, and correction losses have been reported.[1,5,15,23,32,41,45] Some loss of correction may occur after removal of the distraction devices, so that the end result is often roughly similar to the original deformation.[1,28,36]

Roy-Camille and co-workers' transpedicular screw fixations of plates[37,38] paved the way for Magerl's external fixation of vertebral fractures with the aid of transpedicular screws[30,31] and for posterior segmental fixation with an internal fixator.[1,13] This instrumentation, according to Dick, seems to have

From the Department of Orthopaedic Surgery, Uppsala University, Uppsala Hospital.
* Professor and Chairman, Orthopaedic Department, University of Uppsala.
** Associate Professor.
† Fellow.
Reprint requests to Sven Olerud, M.D., Department of Orthopaedic Surgery, University Hospital, S-751 85 Uppsala, Sweden.
Received: April 13, 1987.

Transpedicular Fixation of Thoracolumbar Vertebral Fractures

February 1988

Case 1:04-cv-00204-JJF Document 196-14 Filed 04/27/2005 Page 5 of 10

Olerud Discloses the "Forming the Passage" Step of Claim 1

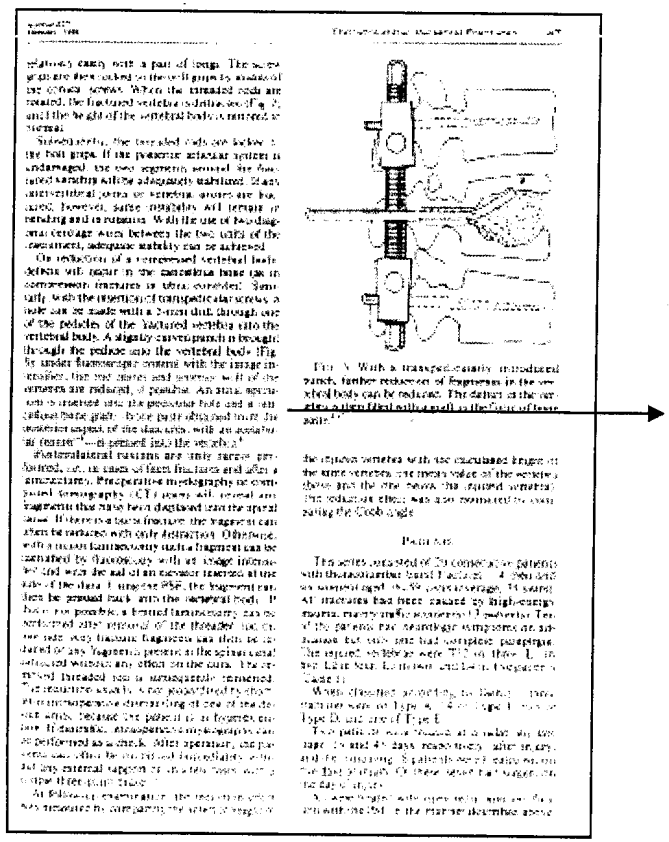

"[A] hole can be made with a 5-mm drill through one of the pedicles of the fractured vertebra, into the vertebral body. A slightly curved punch is brought through the pedicle into the vertebral body (Fig. 3); under fluoroscopic control with the image intensifier, the end plates and anterior wall of the vertebra are reduced, if possible."

Kyphon does not dispute the disclosure of this element.

Olerud Discloses the "Compacting" Step of Claim 1

relatively easily with a pair of tongs. The screw grips are then locked to the bolt grips by means of the conical screws. When the threaded rods are rotated, the fractured vertebra is distracted (Fig. 2) until the height of the vertebral body is restored to normal.

Subsequently, the threaded rods are locked to the bolt grips. If the posterior articular system is undamaged, the two segments around the fractured vertebra will be adequately stabilized. If any intervertebral joints or vertebral arches are fractured, however, some instability will remain in bending and in rotation. With the use of two diagonal cerclage wires between the two units of the instrument, adequate stability can be achieved.

On reduction of a compressed vertebral body, defects will occur in the cancellous bone (as in compression fractures in tibial condyles). Similarly, with the insertion of transpedicular screws, a hole can be made with a 5-mm drill through one of the pedicles of the fractured vertebra into the vertebral body. A slightly curved punch is brought through the pedicle into the vertebral body (Fig. 3) under fluoroscopic control with the image intensifier, the end plates and anterior wall of the vertebra are reduced, if possible. An aural speculum is inserted into the pedicular hole and a cancellous bone graft—bone paste obtained from the posterior aspect of the iliac crest with an acetabular reamer[14]—is pressed into the vertebra.[4]

Posterolateral fusions are only rarely performed, *i.e.*, in cases of facet fractures and after a laminectomy. Preoperative myelography or computed tomography (CT) scans will reveal any fragments that have been displaced into the spinal canal. If there is a burst fracture, the fragment can often be reduced with only distraction. Otherwise, with a minor laminectomy such a fragment can be identified by fluoroscopy with an image intensifier and with the aid of an elevator inserted at the side of the dura. Using the PSF, the fragment can then be pressed back into the vertebral body. If this is not possible, a limited laminectomy can be performed after removal of the threaded rod on one side. Any fracture fragments can then be reduced or any fragments present in the spinal canal extracted without any effect on the dura. The removed threaded rod is subsequently reinserted. The reduction usually is not jeopardized by short-term intraoperative dismantling of one of the device units, because the patient is in hyperextension. If desirable, intraoperative myelography can be performed as a check. After operation, the patients can often be mobilized immediately, without any external support or, in a few cases, with a simple three-point brace.[12]

At follow-up examination the reduction effect was measured by comparing the anterior height of

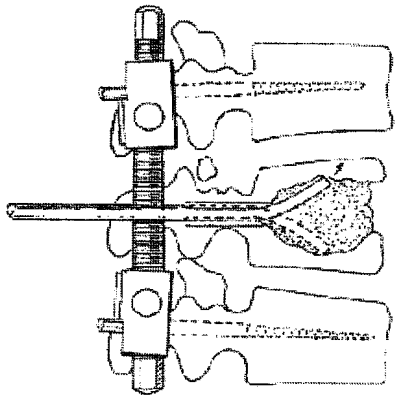

FIG. 3. With a transpedicularly introduced punch, further reduction of fragments in the vertebral body can be reduced. The defect in the vertebra is then filled with a graft in the form of bone paste.[4, 13]

the injured vertebra with the calculated height of the same vertebra (the mean value of the vertebra above and the one below the injured vertebra). The reduction effect was also estimated by comparing the Cobb angle.

PATIENTS

This series consisted of 20 consecutive patients with thoracolumbar burst fractures (14 men and six women) aged 16–59 years (average, 35 years). All fractures had been caused by high-energy trauma, mainly traffic accidents (13 patients). Ten of the patients had neurologic symptoms on admission but only one had complete paraplegia. The injured vertebrae were T12 in three, L1 in five, L2 in four, L3 in two, and L4 in five patients (Table 1).

When classified according to Denis,[5] three fractures were of Type A, 14 of Type B, two of Type D, and one of Type E.

Two patients were treated at a relatively late stage (19 and 45 days, respectively) after injury, and the remaining 18 patients were treated within five days of injury. Of these, seven had surgery on the day of injury.

All were treated with open reduction and fixation with the PSF in the manner described above.

FIG. 3. With a transpedicularly introduced punch, further reduction of fragments in the vertebral body can be reduced. The defect in the vertebra is then filled with a graft in the form of bone paste.[4, 13]

"A slightly curved punch is brought through the pedicle into the vertebral body (Fig. 3); under fluoroscopic control with the image intensifier, the end plates and anterior wall of the vertebra are reduced, if possible."

Case 1:04-cv-00204-JJF Document 196-14 Filed 04/27/2005 Page 7 of 10

Element 3 – "Filling the passage with flowable material capable of setting to a hardened condition"

Flowable is Not Limited to a Liquid

- Kyphon says flowable material means fluid; but improperly limits to liquid
- "Fluid" is defined as "**a nonsolid substance**, such as a liquid or gas, **that tends to flow or conform to the shape of the container**." Stedman's Medical Dictionary. (Exhibit EE.)
- Slurries (made from calcium phosphate) and pastes (made from bone graft) have been used since prior to the filing date of the '888 and '404 Patents. (Exhibit E, at ¶¶ 11-12 and Exhibits E-2, E-3.)
- Slurries and pastes are flowable. (Id.)
- Moreover, even today, polymethylmethacrylate cement, which Kyphon concedes is flowable, is injected in kyphoplasty in a paste form – i.e., it is not flowable in the liquid sense, any more than toothpaste is. (See Exhibit E, ¶ 13.)

Case 1:04-cv-00204-JJF Document 196-14 Filed 04/27/2005 Page 8 of 10

Olerud Discloses the "Filling the Passage with Flowable Material Capable of Setting to a Hardened Condition" Step of Claim 1

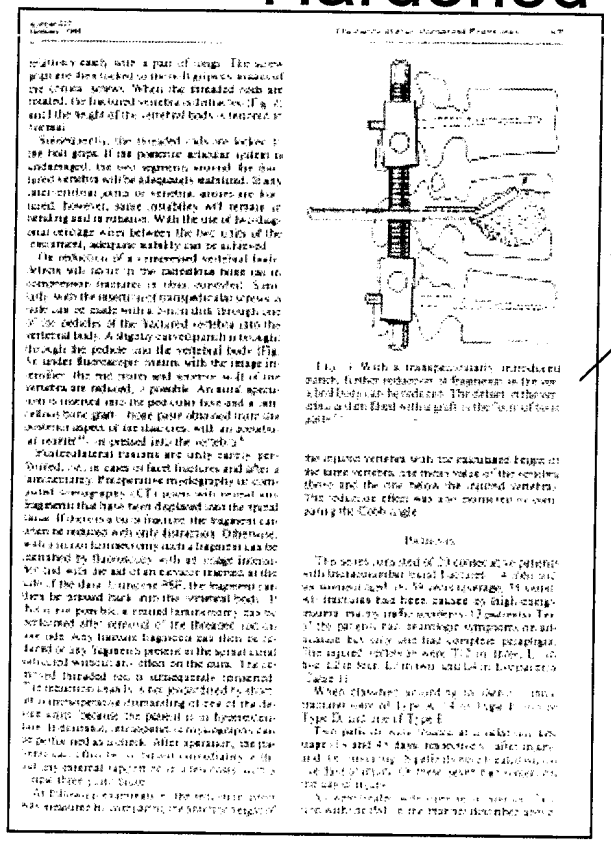

"The defect in the vertebra is then filled with a graft in the form of bone paste."

Exhibit A-20, at p.47, Fig. 3

The Prior Art Showed That Bone Paste Was Flowable

- Bone paste constitutes a "flowable material capable of setting to a hardened condition."
  - Bone Paste is ground bone graft mixed with blood. (See Dick, Exhibit A-15, p. 237 and title.)
  - Bone paste can be inserted into bone via a tube-and-plunger instrument or bone filler device.[1]
  - Bone paste hardens after time and becomes bone.

See Exhibit E, Mitchell Decl., ¶ 18

Case 1:04-cv-00204-JJF Document 196-14 Filed 04/27/2005 Page 10 of 10