E-6

REDACTED

E-7

REDACTED

E-8

REDACTED

E-9

AJNR Am J Neuroradiol 22:373–381, February 2001

Review Article

Percutaneous Vertebroplasty: A Developing Standard of Care for Vertebral Compression Fractures

John M. Mathis, John D. Barr, Stephen M. Belkoff, Michelle S. Barr, Mary E. Jensen, and Hervé Deramond

Acrylic cements have been used for the augmentation of weakened or partially destroyed bones for decades (1). The term vertebroplasty originally described an open surgical procedure that introduces bone graft or acrylic cement to mechanically augment weakened vertebral bodies. Polymethylmethacrylate (PMMA) is the acrylic most commonly used as a bone filler, and its application in the treatment of pathologic vertebral compression fractures (VCFs) has been reported extensively (1–10). In particular, it has been used to treat VCFs created by metastatic disease and primary bone tumors, such as aggressive hemangiomas and giant cell tumors (11).

The first image-guided percutaneous vertebral augmentation, or percutaneous vertebroplasty (PVP), was performed in France in 1984, when Deramond and Galibert (12) injected PMMA into a C2 vertebra that had been partially destroyed by an aggressive hemangioma. The procedure relieved the patient's long-term pain. Shortly thereafter, PVP was used to treat VCFs caused by osteoporosis (13) (Fig 1).

The interest in PVP has continued to grow since its introduction in Europe and its subsequent introduction in the United States by the interventional neuroradiology team at the University of Virginia (14). PVP reportedly offers the patient rapid relief from the pain associated with VCFs and is evolving as a standard of care for VCFs (15). In this review, we describe patient selection criteria, technical aspects of the procedure, and potential complications; review some of the basic science and biomechanics research related to the procedure; and present some future hurdles that still must be overcome for PVP to become a fully accepted standard of care.

Received July 6, 2000; accepted July 26.

From the Departments of Radiology (J.D.B., M.S.B.) and Neurosurgery (J.D.B.), Lewis-Gale Medical Center, Salem, VA (J.M.M.); the Department of Radiology, Cleveland Clinic Foundation, Cleveland, OH; the Department of Surgery, Division of Orthopaedics, University of Maryland, Baltimore (S.M.B.); the Department of Radiology, University of Virginia, Charlottesville (M.E.J.); and Service de Radiologie A, Centre Hospitaliere Universitaire, Amiens, France (H.D.)

Address reprint requests to Stephen M. Belkoff, PhD, c/o Elaine P. Bulson, Editor, Department of Orthopaedic Surgery, Johns Hopkins Bayview Medical Center, 4940 Eastern Ave, #030, Baltimore, MD 21224-2780.

© American Society of Neuroradiology

Demographics of Vertebral Compression Fracture

VCFs occur when the combined axial and bending loads on the spine exceed the strength of the vertebral body (16). Reduction in the individual vertebral body strength may result from infiltrative processes created by benign or malignant tumors or, more commonly, from bone mineral loss precipitated by osteoporosis (17–19). Osteoporosis, which may be age-related (primary) or due to steroid use (secondary), is the most common cause of VCF in the United States (20).

VCF may be defined as either a radiographic or a symptomatic clinical event (21). The prevalence of radiographic VCF has been reported by Melton et al (22) to be as high as 26% in women 50 years old or older. The frequency of radiographic evidence of VCF increases from 500 per 100,000 person years (py) in women aged 50 to 54 years to 2960 per 100,000 py in women more than 85 years old. Radiographic changes may be present without the patient experiencing pain.

Cooper et al (23) found an age- and sex-adjusted incidence of clinically symptomatic VCF of 123 per 100,000 py for the years 1985 to 1989 in a population-based study in Rochester, MN (men and women of all ages combined). The age-adjusted incidence in women (153 per 100,000 py) was almost double that for men (81 per 100,000 py) (23). Even so, the high incidence in men contradicts the common misconception that osteoporosis is a women's health problem. The incidence of VCF exceeded the age- and sex-adjusted rate (114 per 100,000 py) for hip fractures (23).

Patients with VCFs may experience severe and prolonged pain that can markedly alter activities of daily living. In the United States, VCFs account for 150,000 hospital admissions, 161,000 physician office visits, and more than 5 million restricted activity days annually (20). In addition, it has now been shown that patients with VCF may experience other related comorbid events. For example, Schlaich et al (24) found a significantly lower vital capacity and forced expiratory volume in patients who had incurred spinal osteoporotic fractures as compared with control subjects without such fractures. Kado et al (25) reported higher mortality rates in women with VCFs as compared with age-matched control subjects without fracture. Women with one or more fractures had a 1.23-fold greater age-adjusted mortality rate, and mortality rose as the number of VCFs increased: women with five or more fractures had a more than twofold increase.

VCF may also result from tumor infiltration, but the rate of occurrence is hard to assess accurately. Osteolytic metastases and myeloma are the most frequent malignant lesions of the spine (9). Improved cancer treatments have prolonged the life span of patients with primary tumors but have also increased the number of patients who subsequently experience metastatic vertebral involvement and collapse. In addition, because treatment of malignant lesions often includes the use of glucocorticoids, secondary osteoporosis may develop and result in VCFs.

Patient Selection for Vertebroplasty

The primary indication of PVP is pain caused by a VCF resulting from either osteoporosis or tumor

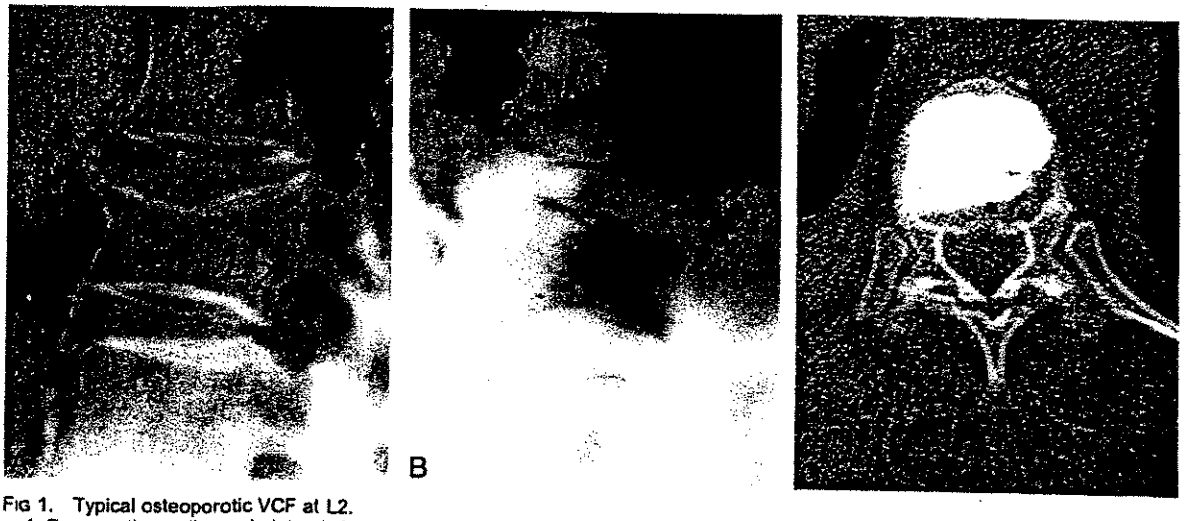

FIG 1. Typical osteoporotic VCF at L2.
A, Preoperative radiograph, lateral view.
B, Radiograph after treatment with vertebroplasty. The dark area represents PMMA opacified with barium sulfate.
C, Axial CT scan of the treated L2 segment.

infiltration (14, 26–33). Currently, we lack the data to support the prophylactic use of PVP in vertebrae at risk of fracture. Although the high probability of VCF in these patients is well known, the precise vertebrae that may become fractured cannot be predicted with sufficient accuracy to justify prophylactic intervention (34). Prophylactic intervention may evolve as more physiological cements or agents capable of stimulating bone remodeling are developed and become available. Substantial pain may also be associated with a clinically aggressive vertebral hemangioma with or without VCF. Although this situation is uncommon relative to osteoporotic and malignant VCF-related pain, it, too, is effectively treated with PVP (33, 34).

The timing of intervention for VCF pain must be individualized. Initially, therapeutic intervention with PVP was limited to those patients for whom nonoperative therapy (eg, analgesics, bed rest, physical therapy, bracing) had failed (14, 15, 26, 27), and early intervention was reserved for those who had side effects (eg, pneumonia, thrombophlebitis, and intolerance to narcotic analgesics) resulting from their disability or who were nonambulatory because of pain refractory to analgesics (35). However, early intervention with PVP may be indicated because of the low complication rates associated with the procedure in patients with osteoporotic VCFs (14, 15, 31, 36) and because of the possibility of continued collapse of the fractured vertebra during the often lengthy period of nonoperative therapy (14, 15, 26–33).

Before initiating PVP, one should carefully assess the patient to ensure that the pain is related to a VCF. Other spinal entities, such as facet arthropathy, herniated nucleus pulposus, and spinal stenosis, may also be present and complicate the evaluation. VCF pain usually worsens with weightbearing and improves with recumbency. VCF pain is typically localized to the area of the fracture and lacks radicular qualities that suggest nerve root or cord compression. Local palpation over the posterior elements of the involved vertebral body will often elicit pain and, combined with imaging verification of the anatomic site of compression, will aid in localization.

The presence of multiple VCFs makes it difficult to ensure accurate localization via standard radiographs and physical examination alone. Pain localization by physical examination should not be assumed to be more accurate than one vertebra above or below the level of maximal discomfort. Also, differentiating acute from chronic VCF on standard radiographs is impossible without comparison films with which to date the fractures. Therefore, in almost all complex situations with multiple compressions or prolonged pain after an inciting event, MR imaging should be used. MR images show both anatomic vertebral collapse and loss of normal signal from the marrow space of vertebrae with acute fractures. These findings are well seen on sagittal T1-weighted sequences because the edema associated with the compression produces a low (dark) signal compared with the high (bright) signal normally seen in the marrow fat. Heavily T2-weighted sequences, such as sagittal short-tau inversion recovery sequences, are the most sensitive, with fluid representing marrow edema. Standard T2-weighted fast spin-echo sequences without fat saturation pulses are often insensitive to marrow edema because of the relatively high signal intensity from fatty marrow. One should be cautious about treating vertebrae that exhibit normal signal on MR images, because many of these patients experience little or no pain relief after PVP. Careful patient selection increases the likelihood of good treatment results.

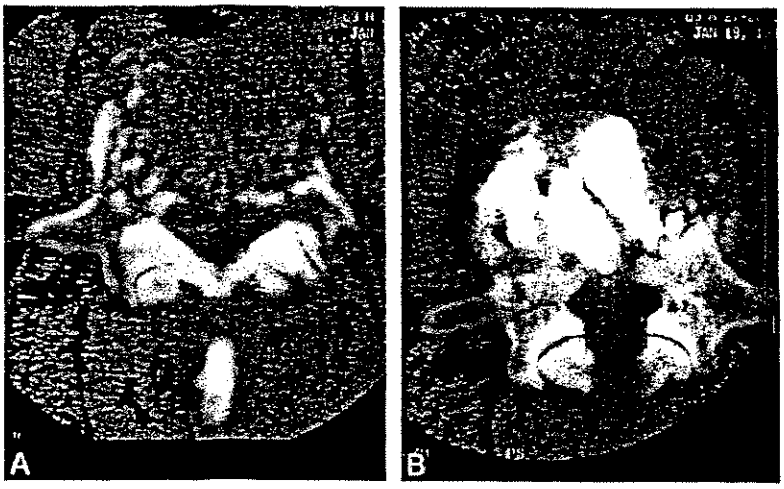

FIG 2. *A* and *B*, Pre- (*A*) and postoperative (*B*) axial CT studies in a patient with an L5 vertebra destroyed by renal cell carcinoma who experienced pain relief 24 hours after PVP (which filled much of the vertebra with PMMA).

Bone scans may also be useful to assess problematic VCF(s), but we prefer MR imaging whenever possible because the latter offers exquisite anatomic detail and concurrent information about other abnormalities, such as spinal stenosis, that impact decisions about the use of PVP. Bone scans are sensitive in detecting VCFs, and a negative bone scan, like a negative MR image, indicates a low likelihood of pain relief after PVP therapy. Bone scans, however, can be positive long after substantial healing of a VCF has occurred. This fact, coupled with the more restricted anatomic information it affords (as compared with MR imaging), makes bone scans our choice only when MR imaging cannot be performed.

As is the case with VCFs, tumor invasion into the vertebral marrow space will also cause a loss of T1 signal on MR images. The presence of a tumor should be suspected when the entire vertebral marrow space appears dark on MR images. On the other hand, in the presence of osteoporosis, only the area immediately adjacent to collapse is dark. There is, however, overlap of signal alteration with this finding, making the low signal on T1-weighted images not totally specific. Similarly, radionuclide bone scans, although sensitive to both fracture and tumor invasion, are unable to differentiate a specific pathogenesis. Therefore, when a tumor is suspected, it may be appropriate to precede PVP with a biopsy. After the cannula is placed for PVP but before cement is injected, a coaxial biopsy specimen may easily be obtained. Pain caused by VCF due to tumor invasion is also effectively treated with PVP; therefore, PVP may immediately follow the biopsy (Fig 2). PVP does not hinder the therapeutic result of subsequent or concomitant radiation or chemotherapy.

Vertebroplasty Technique

High-quality fluoroscopic equipment is essential for the safe performance of PVP. The cannula must be placed accurately to avoid collateral damage, and the cement must be observed during injection to prevent extravasation. Biplane fluoroscopic equipment allows the procedure to be performed more rapidly, but it can also be accomplished safely with a single-plane C-arm (34). CT has been described as an aid to fluoroscopy (36), but it adds considerable complexity and cost to the procedure without corresponding benefit to the routine treatment of a VCF. The use of CT is of benefit in the cervical spine (to avoid the carotid vessels during an anterolateral approach) and down to approximately T4 (where lateral fluoroscopy may be impossible through the shoulders). Regardless of the system used, it is essential to visualize the cement injection in real time (or after the injection of a fraction of a cubic centimeter of cement) to avoid excessive extravasation of cement, which presents the most likely potential for complications (29, 37, 38).

Patients typically receive intravenous antibiotics 30 minutes before the start of the procedure. Although this has become routine, its efficacy has never been validated in a controlled study. Prophylactic preoperative antibiotics (typically 1 g of cephazolin 30 minutes before the procedure) are routinely administered to patients undergoing open surgical procedures that entail PMMA implantation. Antibiotics may also be administered in the cement. Such delivery is usually used for patients who are known to be immunocompromised, but some clinicians routinely mix 1.2 g of tobramycin into the cement for all patients. This practice is empirical, and because it has not proved to be necessary (the occurrence rate of infection associated with PVP is very low), it cannot be scientifically or economically justified.

We typically use fentanyl (Sublimase, Abbott Labs, Chicago, IL) and midazolam (Versed, Roche, Manati, PR) to provide conscious sedation. Conscious sedation does not remove the need for adequate local anesthesia, which should affect not only



FIG 3. Venographic studies of an osteoporotic VCF.

A, Lateral digital subtraction venogram shows nonionic radiographic contrast material leaking into both adjacent disks through endplate fractures.

B, Lateral venogram without digital subtraction of the same site, obtained approximately 10 minutes after *A*. Note that the radiographic contrast agent is still apparent and thus may have impeded visualization of possible cement leaks during PVP.

the skin and subcutaneous tissues but also the periosteum of the vertebral body into which the cannula will be introduced. General anesthetics are seldom administered in patients in whom fluoroscopic guidance is used. With CT, however, patient movement is more critical, and general anesthesia is usually necessary. In addition, general anesthesia may be required for patients undergoing treatment of numerous levels, in which a lengthy operative time is necessary. (We believe that the treatment of more than three levels at one time is relatively contraindicated because of the potential risk of large quantities of marrow elements being embolized to the lungs.)

The area to be treated is prepared in a strictly sterile manner (as if placing a sterile port), with sterile drapes used over other regions. All personnel in the procedure room must observe a full sterile protocol. A posterior oblique projection that places the pedicle of the vertebra over the vertebral body is chosen, and local anesthetic is injected into the overlying skin, needle tract, and periosteum of the involved bone. A small dermatotomy is made with a scalpel. Using fluoroscopic guidance, an 11-gauge trocar and cannula system bone biopsy needle is introduced through the dermatotomy site to the posterior element of the vertebra. A small osteotomy is made in the bone with the cannula, which is then passed through the pedicle and into the vertebral body anterior to the midline of the body (as observed in the lateral projection). The position is checked in both anteroposterior and lateral projections during needle introduction. Alternative approaches include a) parapedicular cannula insertion in the thoracic spine between the rib head and lateral margin of the pedicle and b) posterolateral cannula insertion in the lumbar spine. Compared with the transpedicular approach, the parapedicular and posterolateral approaches may be more highly associated with cement leakage from the vertebral body when the trocar is removed. An anterolateral approach is needed in the cervical spine, and care must be taken to avoid the carotid and vertebral arteries during trocar insertion.

Venography is considered helpful and is routinely used during PVP by some physicians in the United States, but it is not commonly used in Europe. In the United States, it was adopted as a means of assessing cannula location for risk of cement leakage outside the vertebra; however, there are limitations to this method. First, contrast material and bone cement have different flow characteristics, so it is unknown whether there is accurate correlation between the flow path of the two agents. Second, even with the demonstration of extracorporeal venous filling, physicians rarely modify their techniques on the basis of information gained from venograms. High-resolution, real-time visualization of the cement and termination of the injection when a leak is observed provide maximum safety to the patient during the procedure. Third, some types of fractures, such as those that affect the endplates, can leak contrast material into the disk. During venography, these leaks may fill with contrast agent, which remains in place after the procedure, precluding early detection of PMMA if a similar leak occurs (Fig 3). Because of these considerations, some of us do not use venography.

Currently, PVP is performed with some type of PMMA, such as Simplex P (Stryker-Howmedica-Osteonics, Rutherford, NJ), Osteobond (Zimmer, Warsaw, IN), or Cranioplastic (CMW, Blackpool, England). Only Simplex P is approved by the United States Food and Drug Administration (FDA) for use in pathologic fractures, including those in the spine. Simplex P and Osteobond contain 10% wt/vol of barium sulfate for opacification; however, this amount is insufficient for easy visualization during fluoroscopically guided PVP (33). Cranioplastic contains no barium sulfate and is not intrinsically radiopaque. Therefore, all PMMA cements that are currently available commercially require the addition of opacifier in sufficient quantity to ensure visualization and safe injection under fluoroscopy. In Europe, tungsten and tantalum powder are commonly used opacifiers (33), but these substances are difficult to obtain in sterile, medical grade in the United States and they are not

approved by the FDA as opacifiers for PMMA cement. Therefore, in the United States, sterile barium sulfate has been the predominant choice as a cement opacifier. Approximately 30% wt/vol of barium sulfate must be added to PMMA powder to provide sufficient opacification for fluoroscopic monitoring (Jasper LE, Deramond H, Mathis JM, Belkoff SM, unpublished data, 2000). The barium sulfate must be pure, as defined by the United States Pharmacopoeia, and must not contain additives such as those commonly present in barium used for gastrointestinal evaluations. Barium sulfate requires sterilization by dry heat or radiation; ethylene oxide and steam are not acceptable methods of sterilization.

Biomechanical tests have shown that the addition of barium sulfate powder to the cement changes its strength; however, the strength of the cement with barium sulfate added to produce a 30% wt/vol mixture produces no practical change in the compressive strength of the PMMA (39), and it is doubtful that this change is clinically significant, because no mechanical failures of vertebrae treated by PVP have been reported.

Visualization of the cement during injection and careful monitoring for cement extravasation are the keys to making PVP safe. Even though small leaks (eg, a fraction of a cubic centimeter) may be tolerated without clinical sequelae, every attempt should be made to avoid extravasation. If biplane fluoroscopic equipment is used, visualization can easily be maintained in two projections during injection. With only single-plane equipment, the lateral projection must be monitored constantly, because this view allows rapid identification of cement leaks into the epidural space. One must still periodically check the anteroposterior projections to ensure that lateral leaks are avoided. If CT or MR imaging is used, real-time monitoring of the cement during injection is more difficult. Currently, most clinicians who use these imaging guidance methods for needle placement revert to fluoroscopic guidance during cement injection (36).

Once the procedure is completed, the patient should be maintained recumbent to prevent weight-bearing while the cement hardens. PMMA cements typically set within 20 minutes and achieve approximately 90% of their ultimate strength within 1 hour of injection (40). Antibiotic ointment should be applied to the needle introduction sites and then covered with a sterile bandage, similar to skin care given to the injection site after angiography. If the procedure is performed on an outpatient basis, as is now common in the United States, the patient should be observed in the recovery area for 1 to 3 hours after surgery. Patients commonly experience pain relief between 4 and 24 hours postoperatively; however, local tenderness and minimal bruising at the puncture site are common and should be explained to the patient and family before and after the procedure. Typically, patients are medicated with analgesics before the procedure and are maintained on these medications after the procedure as needed. We routinely perform clinical follow-up examinations with repeat visual analog pain scale testing at 1, 7, and 30 days after PVP and compare these values with the results of preoperative testing. Additional radiographic evaluation is conducted only if the patient has not responded positively to the treatment.

Results and Complications

To date, no prospective, randomized trials comparing PVP with nonoperative medical therapy have been reported. Although the reports that do exist must be considered anecdotal, they are uniformly positive about the ability of PVP to produce pain relief for VCF with low complication rates. In the United States, Jensen et al (14) reported 90% pain relief in 29 patients treated with PVP for osteoporotic VCF. The only complications were two rib fractures. Notably, there were no neurologic complications. In a study of 38 patients, Barr et al (35) reported that 63% had marked pain relief and 32% had moderate pain relief after PVP. Only 5% of their patients experienced no improvement after PVP. (Note, however, that all the patients were treated with PVP only after nonoperative management had failed.)

Clinical complications reported after PVP include transitory fever, transient worsening of pain, radiculopathy, rib fractures, cement pulmonary embolism, infection, and spinal cord compression. The rate of complications varies considerably with the indications for PVP. With osteoporotic VCFs, complications are few (usually 1% to 2%) and most often are nonneurologic and transient (14, 15, 30, 35). In patients with malignant tumors, the complication rate increases owing to the risk of leakage of cement resulting from the vertebral body destruction caused by the primary malignant process. Transient radiculopathy has been reported in 3% to 6% of cases and has been successfully treated with steroids and antiinflammatory medications (27, 29, 32, 33); however, persistent radiculopathy occurred in 2% to 3% of patients and required surgical intervention for cement removal. Infection was reported only once, occurring in an immunocompromised patient (27).

Existing Hurdles

Several problems must be overcome before PVP can become the standard of care for the treatment of pain associated with VCF, most importantly the lack of an FDA-approved cement that contains adequate opacification for fluoroscopic monitoring. Several manufacturers are developing cement formulations that will accomplish this goal, but the regulatory process may delay the availability of an adequately opacified cement. As of this writing, several states have approved Medicare reimbursement for PVP, even with the complexities involving

available cements. Such approval has largely been based on the observed efficacy and low complication rate of PVP, coupled with the general lack of an equivalent alternative.

Along with the need for optimal materials for PVP is the coexistent need for scientific validation through prospective randomized clinical trials that compare PVP with conventional medical therapy. Although the published studies are anecdotal and not randomized, they report rapid pain control in a high percentage of responders (12–14, 26–33, 36). In addition, these results have been achieved with a very low complication rate in the case of osteoporotic VCFs (14, 26, 27, 32, 33).

Studies that provide scientific validation may also provide better data about guidelines for appropriate use. The partially compressed, painful VCF seems an obvious choice. More information is needed, however, about the treatment of chronic fractures, fractures at multiple levels, extreme VCFs, and prophylactic use for at-risk vertebrae.

Biomechanics

Several bench-top studies have been conducted to gain a better understanding of the underlying mechanics responsible for the success of PVP as well as basic information on the materials used in the procedure. Such investigations are giving impetus to the development of new devices and materials to improve efficacy of the treatment (41, 42).

Several mechanisms have been proposed to explain the pain relief associated with vertebroplasty, including thermal necrosis and chemotoxicity of the intraosseous pain receptors as well as mechanical stabilization (43). It has been hypothesized that the monomer leachate may be neurotoxic (43–46). This is of particular concern with PVP because, to create a less viscous cement with a longer working time, more monomer is typically added to the powder than is recommended by the manufacturer (14, 37, 47). Such toxicity may also account for the necrotic zone reported around an injected tumor (48). The necrotic zone may also be caused by thermal damage resulting from the exothermic polymerization reaction of PMMA cement (48). During polymerization, temperatures can reach 122°C for large quantities of cement (49). A recent in vitro study of osteoporotic cadaveric vertebrae (50) suggested, however, that temperatures generated during vertebroplasty are not likely to be sufficient to result in widespread thermal necrosis of osteoblasts (51, 52) or neural tissue (53). There is also little risk of thermal damage to the spinal cord or nerve roots, provided the cement is contained within the vertebral body (50). Because tumor tissue may be more sensitive to the thermal effects of the cement than normal tissue is, temperature may still play a role in PVP for the treatment of tumors. Another possible mechanism responsible for the zone of necrosis in tumors is ischemia, which may result from direct (cement intrusion) or indirect (compression) occlusion of tumor vessels.

The most likely mechanism for pain relief after PVP treatment of osteoporotic VCFs appears to be mechanical stabilization of the vertebral body (39, 41, 50, 54). In most ex vivo studies, injection of cement into the vertebral body nearly restored its stiffness and increased its strength (39, 41, 54). We hypothesize that the injected cement prevents painful micromotion at the fracture site.

Currently, no cement has been approved by the FDA specifically for use in vertebroplasty. Of the cements commercially available for human use, all require alteration of their composition to make them suitable for vertebroplasty. To decrease viscosity and increase cement injectability, more monomer has been added to the cement powder than is recommended by the manufacturer (14, 37, 47). Changing the monomer-to-powder ratio can reduce the elastic modulus, yield strength, and ultimate strength of PMMA by as much as 24% (47); however this alteration in cement material properties is apparently of no clinical importance, as we have found no reports of complications attributed to cement failure or to insufficient cement strength or stiffness.

The various cements used in vertebroplasty possess different material properties, both in bench-top tests (Jasper LE, Deramond H, Mathis JM, Belkoff SM, unpublished data, 2000) and when injected into cadaveric specimens (39, 41, 54). Of the commercially available cements, Simplex P has exhibited the strongest and stiffest repair of in vitro specimens (39). Cranioplastic, a commonly used cement for vertebroplasty in the United States, exhibits the lowest strength and stiffness, yet still results in good clinical outcomes (14, 26). In addition, Cotten et al (29) found no correlation between the volume of cement injected and clinical outcome. We have learned from clinical practice that less than a complete vertebral body fill usually provides good pain relief (14, 26, 29). As with other orthopedic devices used to aid fracture healing, the goal of PVP is to provide stability to the vertebral body during the process of fracture healing. In this sense, PVP should be viewed more as a fracture repair technique than as an implant. Recently, research has indicated that a relatively small amount of PMMA is needed to restore prefracture strength to cadaveric vertebrae: 4.4, 3.1, and 2.5 mL into the lumbar, thoracolumbar, and thoracic regions, respectively (55).

Originally, PVP was performed via a bipedicular injection of PMMA (Fig 4A). The question subsequently arose as to whether a unipedicular injection of cement alone could provide sufficient stabilization. A recent bench-top study performed to evaluate this possibility found that unipedicular injections (Fig 4B) that achieve fill across the midline can provide substantial restoration of strength (54). In a recent clinical study, half of the patients were treated with PVP by unipedicular injection, and



FIG 4. Injection techniques.
A, Anterolateral radiograph shows vertebroplasty performed via a bipedicular approach and injections.
B, Anterolateral radiograph shows vertebroplasty performed via a single parapedicular approach, which resulted in a central needle position and good filling with one injection of cement.

there were no complications associated with this method of injection (35); however, small volume fills that do not distribute cement across the central vertical axis of the vertebral body should not be considered biomechanically adequate.

Future Directions

Within the next several years, new, non-PMMA bone cements will be available that will allow the testing of PVP as a treatment for new indications, which may include more aggressive therapy for neoplastic disease of bone by providing concurrent strength augmentation and chemotherapeutic potential. Percutaneous augmentation will most likely develop for areas other than the spine; for example, some preliminary data indicate that percutaneous cement augmentation may provide pain relief for metastatic involvement of the pelvis.

At this time, the primary goal of PVP is pain relief. Height restoration with reduction of kyphosis, along with pain control, is likely to play a larger role in the future. A percutaneously introduced inflatable bone tamp has been developed (Kyphon Inc, Santa Clara, CA) and has FDA approval. Although the device has been tested in vitro (42, 56), as yet there are no published findings in humans to indicate its efficacy or to delineate its indications or contraindications for use as compared with standard PVP. Indeed, height restoration has been reported to occur spontaneously (57) and has been achieved by one of us during PVP by using simple distraction before cement introduction while the patient was on the procedure table. The seemingly elementary technique of distraction may provide adequate height restoration without the need for additional devices or complexity.

Investigation of the prophylactic treatment of vertebrae at risk is just beginning. Because of the increased risk of additional fractures in patients with osteoporosis after their first VCF (25, 58), there may be a substantial need for prophylactic augmentation to prevent future collapse in these at-risk vertebrae. Epidemiologic and bone densitometric data may help provide the information needed to select the patients and the specific vertebrae that would most benefit from augmentation. Hydroxyapatite cements (that potentially can be remodeled into bone), osteoconductive cements, or bone stimulants (such as bone morphogenic protein) may find applications in this area. New materials may be introduced into the bone by using smaller cannulas than those now in common use. In addition, robotic or stereotactic guidance may improve the speed and accuracy of cannula placement.

Conclusions

To date, PVP has provided pain relief related to VCF with a very low complication rate. We believe that it will continue to gain scientific and patient acceptance and that it may ultimately become the standard of care for the treatment of painful VCFs. The use of percutaneous injection of cement to mechanically augment the skeleton may expand considerably beyond its currently limited application in the spine after VCF.

References

1. Harrington KD, Sim FH, Enis JE, Johnston JO, Diok HM, Gristina AG. **Methylmethacrylate as an adjunct in internal fixation of pathological fractures: experience with three hundred and seventy-five cases.** *J Bone Joint Surg* 1976;58A:1047–1055
2. Sundaresan N, Galicich JH, Lane JM, Bains MS, Mc Cormack P. **Treatment of neoplastic epidural cord compression by vertebral body resection and stabilization.** *J Neurosurg* 1985;63:676–684
3. Cybulski GR. **Methods of surgical stabilization for metastatic disease of the spine.** *Neurosurgery* 1989;25:240–252
4. Persson BM, Ekelund L, Lovdahl R, Gunterberg B. **Favourable results of acrylic cementation for giant cell tumors.** *Acta Orthop Scand* 1984;55:209–214
5. O' Donnell RJ, Springfield DS, Motwani HK, Ready JE, Gebhardt MC, Mankin HJ. **Recurrence of giant-cell tumors of the long bones after curettage and packing with cement.** *J Bone Joint Surg* 1994;76A:1827–1833

6. Nicola N, Lins E. Vertebral hemangioma: retrograde embolization-stabilization with methyl methacrylate. *Surg Neurol* 1987;27:481–486
7. Cortet B, Cotten A, Deprez X, et al. Value of vertebroplasty combined with surgical decompression in the treatment of aggressive spinal angioma: apropos of 3 cases [in French]. *Rev Rhum Ed Fr* 1994;61:16–22
8. Mavian GZ, Okulski CJ. Double fixation of metastatic lesions of the lumbar and cervical vertebral bodies utilizing methylmethacrylate compound: report of a case and review of a series of cases. *J Am Osteopath Assoc* 1986;86:153–157
9. Alleyne CH Jr, Rodts GE Jr, Haid RW. Corpectomy and stabilization with methylmethacrylate in patients with metastatic disease of the spine: a technical note. *J Spinal Disord* 1995;8: 439–443
10. Beaver DP, Mac Pherson GC, Muir P, Johnson KA. Methylmethacrylate and bone screw repair of seventh lumbar vertebral fracture-luxations in dogs. *J Small Anim Pract* 1996; 37:381–386
11. Menendez LR, Murata GT, Cahill EL, Moore TM. Polymethylmethacrylation in the treatment of giant cell tumors. In: Langlais F, Tomeno B, eds. *Limb Salvage: Major Reconstructions in Oncologic and Nontumoral Conditions*. Berlin: Springer;1991: 147–153
12. Galibert P, Deramond H, Rosat P, Le Gars D. Preliminary note on the treatment of vertebral angioma by percutaneous acrylic vertebroplasty [in French]. *Neurochirurgie* 1987;33:166–168
13. Bascoulergue Y, Duquesnel J, Leclercq R, Mottolese C, Lapras C. Percutaneous injection of methyl methacrylate in the vertebral body for the treatment of various diseases: percutaneous vertebroplasty (abstract). *Radiology* 1988;169P:372–372
14. Jensen ME, Evans AJ, Mathis JM, Kallmes DF, Cloft HJ, Dion JE. Percutaneous polymethylmethacrylate vertebroplasty in the treatment of osteoporotic vertebral body compression fractures: technical aspects. *AJNR Am J Neuroradiol* 1997;18:1897–1904
15. Mathis JM, Eckel TS, Belkoff SM, Deramond H. Percutaneous vertebroplasty: a therapeutic option for pain associated with vertebral compression fracture. *J Back Musculoskel Rehab* 1999;13:11–17
16. Garfin SR, Blair B, Eismont FJ, Abitbol J-J. Thoracic and upper lumbar spine injuries. In: Browner BD, Jupiter JB, Levine AM, Trafton PG, eds. *Skeletal Trauma: Fractures, Dislocations, Ligamentous Injuries, 2nd ed*. Philadelphia: Saunders;1998:947–1034
17. Hayes WC, Piazza SJ, Zysset PK. Biomechanics of fracture risk prediction of the hip and spine by quantitative computed tomography. *Radiol Clin North Am*1991;29:1–18
18. Hayes WC. Biomechanics of cortical and trabecular bone: implications for assessment of fracture risk. In: Mow VC, Hayes WC, eds. *Basic Orthopaedic Biomechanics*. New York: Raven Press;1991:93–142
19. Peck WA, Riggs BL, Bell NH, et al. Research directions in osteoporosis. *Am J Med* 1988;84:275–282
20. Riggs BL, Melton LJ III. The worldwide problem of osteoporosis: insights afforded by epidemiology. *Bone* 1995;17:505S–511S
21. Silverman SL. The clinical consequences of vertebral compression fracture. *Bone* 1992;13:S27–S31
22. Melton LJ III, Kan SH, Frye MA, Wahner HW, O' Fallon WM, Riggs BL. Epidemiology of vertebral fractures in women. *Am J Epidemiol* 1989;129:1000–1011
23. Cooper C, Atkinson EJ, O' Fallon WM, Melton LJ III. Incidence of clinically diagnosed vertebral fractures: a population-based study in Rochester, Minnesota, 1985–1989. *J Bone Miner Res* 1992;7:221–227
24. Schlaich C, Minne HW, Bruckner T, et al. Reduced pulmonary function in patients with spinal osteoporotic fractures. *Osteoporos Int* 1998;8:261–267
25. Kado DM, Browner WS, Palermo L, Nevitt MC, Genant HK, Cummings SR. Vertebral fractures and mortality in older women: a prospective study: study of Osteoporotic Fractures Research Group. *Arch Intern Med* 1999;159:1215–1220
26. Mathis JM, Petri M, Naff N. Percutaneous vertebroplasty treatment of steroid-induced osteoporotic compression fractures. *Arthritis Rheum* 1998;41:171–175
27. Chiras J, Depriester C, Weill A, Sola-Martinez MT, Deramond H. Percutaneous vertebral surgery: techniques and indications [in French]. *J Neuroradiol* 1997;24:45–59
28. Cotten A, Deramond H, Cortet B, et al. Preoperative percutaneous injection of methyl methacrylate and n-butyl cyanoacrylate in vertebral hemangiomas. *AJNR Am J Neuroradiol* 1996; 17:137–142
29. Cotten A, Dewatre F, Cortet B, et al. Percutaneous vertebroplasty for osteolytic metastases and myeloma: effects of the percentage of lesion filling and the leakage of methyl methacrylate at clinical follow-up. *Radiology* 1996;200:525–530
30. Weill A, Chiras J, Simon JM, Rose M, Sola-Martinez T, Enkaoua E. Spinal metastases: indications for and results of percutaneous injection of acrylic surgical cement. *Radiology* 1996;199: 241–247
31. Debussche-Depriester C, Deramond H, Fardellone P, et al. Percutaneous vertebroplasty with acrylic cement in the treatment of osteoporotic vertebral crush fracture syndrome. *Neuroradiology* 1991;33:149–152
32. Cotten A, Boutry N, Cortet B, et al. Percutaneous vertebroplasty: state of the art. *Radiographics* 1998;18:311–323
33. Deramond H, Depriester C, Galibert P, Le Gars D. Percutaneous vertebroplasty with polymethylmethacrylate: technique, indications, and results. *Radiol Clin North Am* 1998;36:533–546
34. Wehrli FW, Ford JC, Haddad JG. Osteoporosis: clinical assessment with quantitative MR imaging in diagnosis. *Radiology* 1995;196:631–641
35. Barr JD, Barr MS, Lemley TJ, Mc Cann RM. Percutaneous vertebroplasty for pain relief and spinal stabilization. *Spine* 2000; 25:923–928
36. Gangi A, Kastler BA, Dietemann JL. Percutaneous vertebroplasty guided by a combination of CT and fluoroscopy. *AJNR Am J Neuroradiol* 1994;15:83–86
37. Deramond H, Depriester C, Toussaint P, Galibert P. Percutaneous vertebroplasty. *Semin Musculoskel Radiol* 1997;1:285–295
38. Padovani B, Kasriel O, Brunner P, Peretti-Viton P. Pulmonary embolism caused by acrylic cement: a rare complication of percutaneous vertebroplasty. *AJNR Am J Neuroradiol* 1999;20: 375–377
39. Belkoff SM, Maroney M, Fenton DC, Mathis JM. An in vitro biomechanical evaluation of bone cements used in percutaneous vertebroplasty. *Bone* 1999;25:23S–26S
40. Mathis JM, Maroney M, Fenton DC, Belkoff SM. Evaluation of bone cements for use in percutaneous vertebroplasty (abstract). In: *Proceedings of the 13th Annual Meeting of the North American Spine Society (San Francisco, CA, October 28–31, 1998)*. Rosemont, IL: North American Spine Society;1998:210–211
41. Belkoff SM, Mathis JM, Erbe EM, Fenton DC. Biomechanical evaluation of a new bone cement for use in vertebroplasty. *Spine* 2000;25:1061–1064
42. Belkoff SM, Fenton DC, Scribner RM, Reiley MA, Talmadge K, Mathis JM. An in vitro biomechanical evaluation of an inflatable bone tamp used in the treatment of compression fracture. *Spine* 2001;26:151–156
43. Bostrom MP, Lane JM. Future directions: augmentation of osteoporotic vertebral bodies. *Spine* 1997;22:38S–42S
44. Dahl OE, Garvik LJ, Lyberg T. Toxic effects of methylmethacrylate monomer on leukocytes and endothelial cells in vitro [published erratum appears in Acta Orthop Scand 1995;66: 387]. *Acta Orthop Scand* 1994;65:147–153
45. Danilewicz-Stysiak Z. Experimental investigations on the cytotoxic nature of methyl methacrylate. *J Prosthet Dent* 1980; 44:13–16
46. Seppalainen AM, Rajaniemi R. Local neurotoxicity of methyl methacrylate among dental technicians. *Am J Ind Med* 1984;5: 471–477
47. Jasper LE, Deramond H, Mathis JM, Belkoff SM. The effect of monomer-to-powder ratio on the material properties of cranioplastic. *Bone* 1999;25:27S–29S
48. San Millan RD, Burkhardt K, Jean B, et al. Pathology findings with acrylic implants. *Bone* 1999;25:85S–90S
49. Jefferiss CD, Lee AJC, Ling RSM. Thermal aspects of self-curing polymethylmethacrylate. *J Bone Joint Surg* 1975;57B:511–518
50. Deramond H, Wright NT, Belkoff SM. Temperature elevation caused by bone cement polymerization during vertebroplasty. *Bone* 1999;25:17S–21S
51. Eriksson RA, Albrektsson T, Magnusson B. Assessment of bone viability after heat trauma: a histological, histochemical and vital microscopic study in the rabbit. *Scand J Plast Reconstr Surg* 1984;18:261–268
52. Rouiller C, Majno G. Morphologische und chemische untersuchung an knochen nach hitzeeinwirkung. *Beitr Pathol Anat Allg Pathol* 1953;113:100–120
53. De Vrind HH, Wondergem J, Haveman J. Hyperthermia-induced damage to rat sciatic nerve assessed in vivo with functional

methods and with electrophysiology. *J Neurosci Methods* 1992; 45:165–174
54. Tohmeh AG, Mathis JM, Fenton DC, Levine AM, Belkoff SM. Biomechanical efficacy of unipedicular versus bipedicular vertebroplasty for the management of osteoporotic compression fractures. *Spine* 1999;24:1772–1776
55. Belkoff S, Deramond H, Mathis J, Jasper L. Vertebroplasty: the biomechanical effect of cement volume (abstract). *Trans Orthop Res Soc* 2000;25:356
56. Wilson DR, Myers ER, Mathis JM, et al. Effect of augmentation on the mechanics of vertebral wedge fractures. *Spine* 2000;25: 158–165
57. Nelson DA, Kleerekoper M, Peterson EL. Reversal of vertebral deformities in osteoporosis: measurement error or "rebound"? *J Bone Miner Res* 1994;9:977–982
58. Ross PD, Davis JW, Epstein RS, Wasnich RD. Pre-existing fractures and bone mass predict vertebral fracture incidence in women. *Ann Intern Med* 1991;114:919–923

E-10

SPINE Volume 28, Number 22, pp E457–E460
©2003, Lippincott Williams & Wilkins, Inc.

Polymethylmethacrylate Cement Dislodgment Following Percutaneous Vertebroplasty: A Case Report

Tsung-Ting Tsai, MD, Wen-Jer Chen, MD, Po-Liang Lai, MD, Lih-Huei Chen, MD, Chi-Chien Niu, MD, Tsai-Sheng Fu, MD, and Chak-Bor Wong, MD

Study Design. A case report is presented.

Objectives. To report a rare complication of delayed cement displacement following percutaneous vertebroplasty.

Summary of Background Data. Although percutaneous vertebroplasty is considered a minimally invasive procedure, it may result in several complications. To our knowledge, this is the first report of delayed cement displacement after percutaneous vertebroplasty.

Methods. A 69-year-old man with T12 osteoporotic compression fracture received percutaneous vertebroplasty. One month after surgery, the patient complained of progressive severe back pain, and roentgenographic image revealed a breakdown of the anterior cortex of the T12 vertebral body with anterior displacement of the bone cement.

Results. The complication was solved by one stage anterior and posterior operation: thoracoabdominal approach with removal of the displaced cement and posterior instrumentation from T11 to L1. The severe back pain with associated weakness improved after surgery.

Conclusions. This complication is rare and likely to occur in treatment of osteoporotic vertebral fracture with avascular necrosis and anterior cortical defect. [Key words: polymethylmethacrylate bone cement, percutaneous vertebroplasty, complication] **Spine 2003;28:E457–E460**

Percutaneous vertebroplasty is a minimally invasive therapeutic procedure initially described by Galibert *et al* in 1987.[1] The technique involves a posterior transpedicular approach of the spinal needle under fluoroscopic guidance and then an injection of polymethylmethacrylate (PMMA) cement into the collapsed vertebral body.[2]

The procedure became popular for the management of pain associated with benign compression fracture, multiple myelomas, lymphomas, vertebral metastatic lesions, and hemangiomas. Recent papers reported that 90% of the patients described pain relief within 24 hours after treatment.[3] Vertebroplasty has been corroborated to be a safe and useful procedure for the treatment of focal back pain when conservative treatment has failed.[4]

However, complications are reported, including bleeding at the puncture site, local infection, leakage of cement into the spinal canal or paravertebral tissues, perivertebral venous leakage, and pulmonary embolism.[2,5–7] The following case report documents a rare complication of delayed cement displacement after percutaneous vertebroplasty for an osteoporotic compression fracture of spine.

Case Report

A 69-year-old man suffered from persistently severe low back pain and progressive kyphotic deformity since he slipped down from stairs 3 months before medical consult. The findings on neurologic examination were within normal limits. Roentgenographic study revealed T12 vertebral body height decreased without evidence of endplate erosion. Magnetic resonance imaging (MRI) studies of the thoracolumbar spine revealed collapse of the vertebral body with formation of a cavitary lesion. High signal on T2-weighted MRI revealed a fluid-filled intravertebral cleft. There was no evidence of soft tissue mass or paravertebral abscess. Benign osteoporotic compression fracture with avascular necrosis was confirmed (Figure 1).

Because of the intractable back pain without neurologic deficits, which had been unrelieved by nonoperative care, percutaneous vertebroplasty was performed. After closed postural reduction of the T12 vertebral body, 12 cc PMMA bone cement was injected (7 cc *via* the left pedicle and 5 cc *via* the right pedicle) into the vacuum space of vertebral body. The preoperative intractable pain was relieved dramatically after vertebroplasty. Postoperative roentgenographic image revealed reduction of the fracture associated kyphosis and increased vertebral body height. The bone cement was well localized in the cystic cavity of T12 vertebral body (Figure 2).

One month after surgery, the patient complained of progressive severe back pain radiating to the lower abdomen, with associated weakness of ankle dorsiflexion and plantarflexion. The progressive severe back pain was also present as he attempted walking.

Roentgenographic image revealed a breakdown of the anterior cortex of the T12 vertebral body, with anterior displacement of the bone cement and kyphotic deformity of the thoracolumbar junction. A thoracolumbar MRI further confirmed the anterior dislodgment of the bone cement with kyphotic deformity and anterior compression of the spinal cord (Figure 3).

The patient was brought to the operating room for a one-stage anterior and posterior operation. A left-sided thoracoabdominal approach with removal of the T10 rib for a total corpectomy of T12 and decompression of the spinal canal were performed. The anteriorly dislodged bone cement was found and removed between the anterior longitudinal ligament and the vertebral body of T12 (Figure 4). After corpectomy of T12 and well curettage of the T11 inferior and L1 superior endplates, a 4 cm autologous iliac bone graft was used as a strut

From the Department of Orthopaedic Surgery, Chang Gung Memorial Hospital, Taipei, Taiwan, Republic of China.
Acknowledgment date: April 11, 2003. First revision date: June 13, 2003. Acceptance date: June 17, 2003.
The manuscript submitted does not contain information about medical device(s)/drug(s). No funds were received to support this work. No benefits in any form have been or will be received from a commercial party related directly or indirectly to the subject of this manuscript.
Address correspondence and reprint requests to Dr. Wen-Jer Chen, Department of Orthopaedic Surgery, Chang Gung Memorial Hospital, 5, Fu-Shin Street, Kweishan, Taoyuan, Taiwan, R.O.C.

KY 386774

Copyright © Lippincott Williams & Wilkins. Unauthorized reproduction of this article is prohibited.



Figure 1. Lateral radiographs (A) demonstrating T12 vertebral body height decreased with kyphotic deformity. Sagittal magnetic resonance imaging scans of thoracolumbar spine, demonstrating fracture and avascular necrosis with formation of a cavitary lesion. High signal on T2-weighted magnetic resonance image revealed fluid-filled intravertebral cleft (B).

graft for anterior fusion. Then, posterior instrumentation and fusion from T11 to L1 with posterior iliac bone graft was performed on prone position.

The severe back pain with associated weakness improved after surgery, whereas the kyphotic deformity was corrected. The patient was discharged from the hospital on the seventh postoperative day.

■ Discussion

Management of symptomatic osteoporotic vertebral compression fractures by vertebroplasty with PMMA has become increasingly popular. Although percutaneous vertebroplasty is considered a minimally invasive procedure, it may result in several complications.[2,5–7] The current case demonstrates a rare complication of delayed PMMA bone cement dislodgment following vertebroplasty that occurred 1 month after the procedure.

In order to minimize the risk of direct cement extrusion into the canal through cortical defects or enlarged venous sinusoids, most authors who are experienced in performing vertebroplasty have recommended that the PMMA be injected in a viscous or partially polymerized consistency through large-bore (10-gauge) needles.[8,9] However, injection of viscous cement with low pressure decreases the penetration of the cement into the microstructure of cancellous bone.[10,11] Krause *et al*[12] reported that doughy cement on an unclean surface resulted in a very low interface strength compared to a low-viscosity cement made to penetrate a cleaned bone surface. Thermal necrosis of the surrounding tissue caused by the high polymerization temperature and the nonunion of fibrous tissue on the surface of the fractured cancellous bone intercept the interdigitation of methylmethacrylate to achieve a mechanical interlock. The current case we reported had a delayed posttraumatic vertebral collapse and an intravertebral vacuum cleft which has long been considered as pathognomonic for avascular necrosis.[13–15] Injection of PMMA into a cystic cavity would be expected to have far less interdigitation with the surrounding bone than would injection into partially intact trabecular bone. The above mentioned reasons make PMMA cement in vertebroplasty merely a space occupying material without mechanical interlock and biocompatibility and, thus, make the potential for dislodgment.

The integrity of the anterior cortex is another consideration of anterior dislodgment. The wedge-type compression fractures showed greater loss in anterior height than in posterior height, and the extravasation of the PMMA cement was most common at the anterolateral wall of the vertebral body.[16] The anterior cortex defect, such as the current case, may have increased the chance of anterior dislodgment of the cement under weight bearing.

Vertebroplasty is a simple and convenient procedure for the management of pain associated with benign compression fractures and other osteolytic spine lesions. We



Figure 2. Postvertebroplasty lateral radiographs demonstrating reduction of the fracture associated kyphosis and increased vertebral body height. The bone cement was well localized in the cystic cavity of T12 vertebral body.

KY 386775

Copyright © Lippincott Williams & Wilkins. Unauthorized reproduction of this article is prohibited.

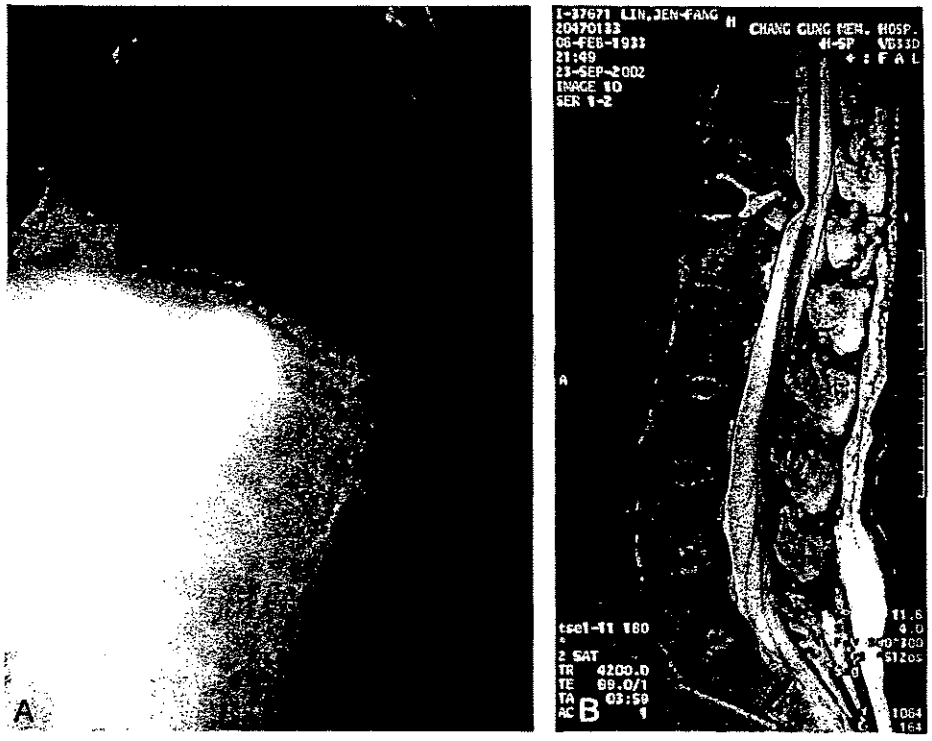

Figure 3. One month after surgery, roentgenographic image revealed a breakdown of the anterior cortex of the T12 vertebral body, with anterior dislodgment of the bone cement and kyphotic deformity of the thoracolumbar junction (A). A thoracolumbar magnetic resonance image further confirmed the anterior displacement of the bone cement with kyphotic deformity and anterior compression of the spinal cord (B).

reported a rare complication of delayed cement displacement after percutaneous vertebroplasty. The delayed extrusion of the PMMA is likely to occur in treatment of osteoporotic vertebral fracture with avascular necrosis and anterior cortical defect.



Figure 4. The anteriorly dislodged bone cement was found and removed between the anterior longitudinal ligament and the T12 vertebral body.

■ Key Points

- The rare complication of delayed cement displacement after percutaneous vertebroplasty is presented.
- Injection of PMMA in a viscous consistency with low pressure can minimize the risk of direct cement extrusion; however, it decreases the penetration of the cement into the microstructure of cancellous bone.
- Injection of PMMA into a cystic cavity would be expected to have far less interdigitation with the surrounding bone than would injection into partially intact trabecular bone.

KY 386776

References

1. Galibert P, Deramond H, Rosat P, et al. Preliminary note on the treatment of vertebral angioma by percutaneous acrylic vertebroplasty. *Neurochirurgie* 1987;33:166–8.
2. Deramond H, Depriester C, Galibert P, et al. Percutaneous vertebroplasty with polymethylmethacrylate. Technique, indications, and results. *Radiol Clin North Am* 1998;36:533–46.
3. Jensen ME, Evans AJ, Mathis JM, et al. Percutaneous polymethylmethacrylate vertebroplasty in the treatment of osteoporotic vertebral body compression fractures: technical aspects. *Am J Neuroradiol* 1997;18:1897–904.
4. Grados F, Depriester C, Cayrolle G, et al. Long-term observations of vertebral osteoporotic fractures treated by percutaneous vertebroplasty. *Rheumatology* 2000;39:1410–4.
5. Chen HL, Wong CS, Ho ST, et al. A lethal pulmonary embolism during percutaneous vertebroplasty. *Anesth Analg* 2002;95:1060–2.

Copyright © Lippincott Williams & Wilkins. Unauthorized reproduction of this article is prohibited.

6. Cotten A, Dewatre F, Cortet B, et al. Percutaneous vertebroplasty for osteolytic metastases and myeloma: effects of the percentage of lesion filling and the leakage of methylmethacrylate at clinical follow-up. *Radiology* 1996; 200:525–30.
7. Levine SA, Perin LA, Hayes D, et al. An evidence-based evaluation of percutaneous vertebroplasty. *Manag Care* 2000;9:56–60.
8. Barr M, Barr J. Invited commentary. *Radiographics* 1998;18:320–2.
9. Bostrom MP, Lane JM. Future directions. Augmentation of osteoporotic vertebral bodies. *Spine* 1997;22(24 suppl):385–425.
10. Askew MJ, Steege JW, Lewis JL, et al. Effect of cement pressure and bone strength on polymethylmethacrylate fixation. *J Orthop Res* 1984;1: 412–20.
11. Panjabi MM, Drinker H, Goel VK, et al. Effects of medullary injection pressure on interdigitation of methylmethacrylate and cancellous bone. *Trans Orthop Res Soc* 1981;6:319.
12. Krause WR, Krug W, Eng B, et al. Strength of the cement-bone interface. *Clin Orthop* 1982;163:290–9.
13. Kummell H sen. Der heutige Standpunkt der posttraumatischen Wirbelerkrankung ("Kummelsche Krankheit"). *Arch Orthop Unfall-Chir* 1928; 26:471–502.
14. Lane JI, Maus TP, Wald JT, et al. Intravertebral clefts opacified during vertebroplasty: pathogenesis, technical implications, and prognostic significance. *Am J Neuroradiol* 2002;23:1642–6.
15. Maldague BE, Noel HM, Malghem JJ. The intravertebral vacuum cleft: a sign of ischemic vertebral collapse. Radiology 1978;129:23–9.
16. Lim TH. Biomechanical evaluation of an injectable calcium phosphate cement for vertebroplasty. *Spine* 2002;27:1297–302.

Copyright © Lippincott Williams & Wilkins. Unauthorized reproduction of this article is prohibited.

E-11

General Articles
Case Reports

Severe Hypercapnia Due to Pulmonary Embolism of Polymethylmethacrylate During Vertebroplasty

Kay Stricker, MD*, Rene Orler, MD†, Katrin Yen, MD‡, Jukka Takala, MD, PhD§, and Martin Luginbühl, MD*

Departments of *Anesthesiology and †Orthopedic Surgery, University Hospital of Bern, Switzerland; and ‡Institute for Legal Medicine and §Department of Intensive Care Medicine, University of Bern, Switzerland

Pulmonary polymethylmethacrylate embolism is a rare but potentially fatal complication of percutaneous vertebroplasty. Clinical signs are typical for pulmonary embolism: they include respiratory distress, hypotension, and decreases in end-tidal CO_2. We report a case of fatal pulmonary polymethylmethacrylate embolism during percutaneous vertebroplasty that initially presented with hypertension (arterial blood pressure 190/90 mm Hg), normocardia, and hypercapnia ($Paco_2$ 96 mm Hg), along with loss of consciousness. Several pieces of polymethylmethacrylate were found in the pulmonary vasculature at autopsy.

(Anesth Analg 2004;98:1184–6)

Injection of polymethylmethacrylate (PMMA) into vertebral bodies is performed to stabilize osteoporotic fractures and for rapid pain relief (1). The procedure is minimally invasive and is mostly performed under local anesthesia and conscious sedation (2,3), even in high-risk patients (4). Although the intervention has generally been considered safe, several severe complications of this procedure have been reported; these are mainly due to embolization of fat, bone marrow, or PMMA monomer (5–7) and mostly present with severe hypotension and hypocapnia. We report on a patient with PMMA embolism during percutaneous vertebroplasty who presented with massive hypercapnia and coma.

Case Report

An 83-yr-old woman (height, 158 cm; weight, 57 kg) with severe lumbar back pain due to an osteoporotic fracture of her first lumbar vertebra was scheduled for percutaneous vertebroplasty of the lumbar vertebral bodies 1 through 4. The patient had a history of chronic obstructive pulmonary disease, which was treated with 10 mg of prednisone by mouth and with inhalation therapy with ipratropium bromide and salbutamol. Her recurrent congestive heart failure was controlled with hydrochlorothiazide and amiloride and with aspirin.

On arrival in the operating room, the patient, who had not received any premedication, was monitored and turned to the prone position. During the entire 55-min procedure, she was given oxygen 6 L/min and repeated IV doses of alfentanil (250 μg). During insertion of the injection needles, arterial blood pressure was approximately 140/50 mm Hg, heart rate was 75–90 bpm, respiratory rate was 12 to 16 breaths/min, oxygen saturation was 100%, and the patient was arousable and responsive. PMMA injection was started approximately 30 min after the beginning of surgery. During the last injection of PMMA (all performed under continuous lateral fluoroscopic control), the patient became restless and moaned but remained responsive, and the anesthesiologist observed increased spontaneous respiration. This was interpreted as pain and was treated with another 250 μg of alfentanil. A gradual decrease of transcutaneous oxygen saturation to 92% and an arterial blood pressure increase to 160/65 mm Hg were observed. After termination of the PMMA injection, the patient was no longer responsive to verbal and painful stimuli; the respiratory rate was approximately 12 breaths/min, and transcutaneous oxygen saturation was still 92%. Loss of consciousness was related to alfentanil, and because the procedure was shortly before completion, it was decided to await skin closure before turning the patient to the supine position. Besides sinus tachycardia, there were no electrocardiographic changes at this time. Another 10 min later, she was turned to the supine position, and arterial blood pressure further increased to 190/90 mm Hg and heart rate to 120 bpm, whereas oxygen saturation further decreased to 80%. Assisted bag/mask ventilation was started to support spontaneous ventilation, which was approximately 7 L/min as measured with the breathing circuit and a tight-fitting face mask; this was higher than the expected minute ventilation for a patient of this weight (3.5–5 L/min). After 20 min of assisted mask ventilation with 100% oxygen (approximately 10 L/min),

Accepted for publication October 15, 2003.

Address correspondence to Kay Stricker, MD, DEAA, Department of Anesthesiology, University Hospital, CH-3010 Bern, Switzerland. Address e-mail to Kay.Stricker@insel.ch. Reprints will not be available from the authors.

DOI: 10.1213/01.ANE.0000104585.83801.C5

©2004 by the International Anesthesia Research Society
0003-2999/04

KY 386778

© International Anesthesia Research Society. Unauthorized Use Prohibited.

ANESTH ANALG
2004;98:1184–6

the patient remained unresponsive, and an arterial blood gas analysis showed a pH of 7.11, a Pao_2 of 71 mm Hg, a $Paco_2$ of 96 mm Hg, a base excess of −3.9 mEq/L, and a bicarbonate level of 28.2 mmol/L. Although the total dose of alfentanil administered during the procedure was only 1.5 mg and although the respiratory rate and pattern were not typical for opioid-induced respiratory depression, incremental IV doses of naloxone were administered (120 μg in total). This indeed increased assisted spontaneous ventilation to 12 L/min. However, neither hypercapnia nor level of consciousness improved, and the trachea was intubated after the administration of etomidate and atracurium. The change from assisted spontaneous ventilation to positive-pressure ventilation induced a decrease in systolic arterial blood pressure from 150 to 70 mm Hg, and distended neck veins were recognized. With repeated IV boluses of noradrenaline (5–10 μg each) and adrenaline (10 and 100 μg), hemodynamic variables improved. During hypotension, an ST segment depression was noted.

A transthoracic echocardiogram demonstrated a massively dilated right ventricle. A high-resolution computed tomographic (CT) scan performed 6 h later revealed several pieces of high-contrast material (PMMA) in the pulmonary arteries of the right upper, middle, and lower lobes. At the same time, a string of PMMA could be seen that reached from the fourth lumbar vertebra to the inferior vena cava at the level of the left renal vein. During the CT scan, the patient developed pulseless electrical activity but could be successfully resuscitated within 10 min. Cardiopulmonary variables normalized within 48 h; however, the patient did not regain consciousness over the following 9 days. Several bilateral occipitotemporal infarctions were found on a cranial CT scan. Therefore, therapy was withdrawn, and the patient died within a few hours thereafter. At autopsy, the findings of the thoracoabdominal CT scan were confirmed; PMMA strings were found in the right pulmonary artery (Fig. 1), and a PMMA string exited the lumbar venous plexus and continued through the inferior vena cava (Fig. 2).



Figure 1. Methylmethacrylate string in the right upper and middle lobe arteries at autopsy (large arrow). Arteriosclerotic plaques in the right pulmonary artery as a sign of chronic pulmonary hypertension (small arrow).



Figure 2. Autopsy finding of a polymethylmethacrylate string (broken in two during autopsy) exiting the lumbar venous plexus at L4 and continuing in the inferior vena cava up to the level of the right kidney (arrows).

Discussion

Previous clinical and experimental case reports on PMMA embolization with percutaneous vertebroplasty have mentioned hypotension, bradycardia, hypoxemia, and hypocapnia as major side effects (5,6,8). Conversely, the main symptoms in this case were massive hypercapnia and hypertension, along with hypoxia.

The main cause of hypercapnia was a massive increase in dead space ventilation. An increase of pulmonary arterial pressure may have led to the recruitment of previously nonperfused pulmonary vessels and thebesian veins, resulting in shunting of blood and hypoxemia. Opioid-induced hypoventilation, in contrast, had little effect, because spontaneous minute ventilation was 7 L/min and mechanical ventilation did not improve hypercapnia. Lung function and blood gas analysis at rest were not evaluated before surgery in this patient with severe chronic obstructive pulmonary disease; thus, preexisting hypercapnia cannot be differentiated from changes due to the embolism.

Current medical textbooks typically relate decreases in end-tidal CO_2 during pulmonary embolism to a decrease in cardiac output and an increase of physiologic dead space (9,10). A decrease in arterial Pco_2 may also occur due to hyperventilation caused by hypoxic ventilatory drive or stimulation of airway irritant receptors (10). However, not only hypocapnia, but also hypercapnia, has previously been described in clinical and experimental cases of overwhelming pulmonary thromboembolism (11,12). Detection of hypercapnia was delayed in this case, because hypertension and loss of consciousness were the only signs of embolism, whereas respiratory distress may have been attenuated by the opioids. An insufficient increase in end-tidal CO_2 has been noted even after

KY 386779

prolonged periods of severe pulmonary embolism (12). Thus, monitoring of end-expiratory CO_2 with a nasal cannula would not have shortened this delay.

Clinical cases of massive pulmonary embolism with hypercarbia were associated with severe hemodynamic instability (11). However, hypertension was noted initially in our patient. Cardiac output was not measured during the procedure; however, it must have decreased after this major embolism. Thus, arterial hypertension can be explained only by a massive increase in systemic vascular resistance, possibly because of adrenergic stimulation caused by hypercapnia. After tracheal intubation and positive-pressure ventilation, venous return to the right ventricle may have decreased and pulmonary vascular resistance may have increased. Both decreased right ventricular preload and increased afterload have attenuated right heart function. Hemodynamic collapse occurred only six hours later in the CT suite, when progressive right heart failure developed. Cardiac ischemia as the main cause is unlikely, because troponin levels were only slightly increased, with a maximum of 9.7 U/L 24 hours later (normal limit <0.6 U/L), and after resolution of a temporary right bundle branch block, there were no major ST segment changes in the electrocardiogram. Additionally, at autopsy, there were diffuse atherosclerotic changes in the coronary arteries, but no infarction was found. Furthermore, the foramen ovale was closed, and there were diffuse and massive hypoxemic insults in both hemispheres of the brain, most likely dating from the resuscitation in the CT suite.

Although the procedure was performed under continuous lateral fluoroscopic control, no signs of the impending catastrophe were noted. In fact, the string of PMMA was only 2 mm thick and was invisible during fluoroscopy because of the overlying vertebral body that was already partially filled with PMMA and lying parallel to the radiograph beam. Surgical removal of PMMA from the pulmonary artery under cardiopulmonary bypass, as reported by Tozzi et al. (5), was considered in this case. However, because the cardiopulmonary situation stabilized within hours after resuscitation, and considering the age and comorbidities of the patient, the risk/benefit ratio of this intervention did not seem favorable.

In conclusion, increasing numbers of elderly patients with osteoporotic spine fractures will undergo percutaneous vertebroplasty, which is generally a fast and effective procedure. Hypertension and hypercapnia, along with loss of responsiveness, may be symptoms of severe pulmonary embolism of PMMA during this intervention. Consequently, anesthesiologists may be confronted with similar cases of atypical presentation of cement embolism. Further, in case of suspected leakage of cement, fluoroscopic projection in two levels must be performed.

References

1. Evans AJ, Jensen ME, Kip KE, et al. Vertebral compression fractures: pain reduction and improvement in functional mobility after percutaneous polymethylmethacrylate vertebroplasty—retrospective report of 245 cases. Radiology 2003;226:366–72.
2. Vasconcelos C, Gailloud P, Beauchamp NJ, et al. Is percutaneous vertebroplasty without pretreatment venography safe? Evaluation of 205 consecutive procedures. Am J Neuroradiol 2002;23:913–7.
3. McGraw JK, Lippert JA, Minkus KD, et al. Prospective evaluation of pain relief in 100 patients undergoing percutaneous vertebroplasty: results and follow up. J Vasc Interv Radiol 2002;13:883–6.
4. Kaufmann TJ, Jensen ME, Ford G, et al. Cardiovascular effects of polymethylmethacrylate use in percutaneous vertebroplasty. Am J Neuroradiol 2002;23:601–4.
5. Tozzi P, Abdelmoumene Y, Corno AF, et al. Management of pulmonary embolism during acrylic vertebroplasty. Ann Thorac Surg 2002;74:1706–8.
6. Chen H-L, Wong C-S, Ho S-T, et al. A lethal pulmonary embolism during percutaneous vertebroplasty. Anesth Analg 2002;95:1060–2.
7. Scroop R, Eskridge J, Britz GW. Paradoxical cerebral arterial embolization of cement during intraoperative vertebroplasty. Am J Neuroradiol 2002;23:868–70.
8. Aebli N, Krebs J, Davis G, et al. Fat embolism and acute hypotension during vertebroplasty: an experimental study in sheep. Spine 2002;27:460–6.
9. Joris JL. Anesthesia for laparoscopic surgery. In: Miller RD, ed. Anesthesia. 5th ed. Philadelphia: Churchill Livingstone, 2000:2003–23.
10. Stoelting RK, Dierdorf SF. Anesthesia and co-existing disease. 4th ed. New York: Churchill Livingstone, 2002.
11. Goldberg SK, Lipschutz JB, Fein AM, Lippmann ML. Hypercapnia complicating massive pulmonary embolism. Crit Care Med 1984;12:686–8.
12. Breen PH, Mazumdar B, Skinner SC. How does experimental pulmonary embolism decrease CO_2 elimination? Respir Physiol 1996;105:217–24.

E-12

AJNR Am J Neuroradiol 20:375–377, March 1999

Case Report

Pulmonary Embolism Caused by Acrylic Cement: A Rare Complication of Percutaneous Vertebroplasty

Bernard Padovani, Olivier Kasriel, Philippe Brunner, and Paula Peretti-Viton

Summary: A pulmonary embolus of acrylic cement was present in a 41-year-old woman with Langerhans' cell vertebral histiocytosis (LCH) after percutaneous vertebroplasty. Chest radiograph and CT confirmed pulmonary infarction and the presence of cement in the pulmonary arteries. She was treated with anticoagulants, and responded favorably. This rare complication occurred because perivertebral venous migration was not recognized during vertebroplasty. Adequate preparation of cement and biplane fluoroscopy are recommended for vertebroplasty.

Percutaneous vertebroplasty involves an injection of acrylic cement (polymethylmethacrylate [PMMA]) into a diseased vertebral body for partial vertebral body remodeling and lumbar pain relief (1). Complications are infrequent, and consist of local processes such as infection or cement leakage into the spinal canal or the perivertebral venous system (2, 3). Other complications usually are related to the initial vertebral disease rather than to the vertebroplasty technique itself (2–4). One case of lethal pulmonary embolism has been reported in the immediate postoperative period (4). In that case, pulmonary embolism was not related to the performance of vertebroplasty (no cement was evident on chest radiograph). We report a case of symptomatic pulmonary embolism caused by cement after percutaneous vertebroplasty.

Case Report

A 41-year-old woman was hospitalized for pain in the right lower chest, tachypnea, tachycardia, and hemoptysis. The chest pain started immediately after percutaneous vertebroplasty of L3 performed 10 days earlier for chronic lumbar pain and osteolysis secondary to LCH. Diagnosis of LCH was made 2 years earlier by surgical biopsy. Dyspnea did not develop until the third postoperative day, after the patient already had been discharged from the hospital.

Vertebroplasty was performed under general anesthesia by a unilateral transpedicular approach with a 10-gauge needle. The acrylic cement (Surgical Simplex [How Medica International Inc.; Shannon, Ireland]) had been prepared at room temperature (20° C) and opacified with 1 g of tungsten powder. Eight cc was injected under lateral fluoroscopic guidance.

Blood gas analysis revealed hypoxia (76 mm Hg oxygen) and hypocapnia (36 mm Hg pCO_2). A chest radiograph revealed a consolidation in contact with the pleural surface in the middle lobe, associated with a right pleural effusion. Multiple tubular opacities corresponding to the course of vessels were also depicted opposite the opacity in the middle lobe (Fig 1A).

Ventilation perfusion scanning revealed multiple perfusion defects in the right lung, predominantly in the middle and lower lobes. Doppler sonography of the legs was unremarkable. Thoracic CT revealed the characteristic appearance of pulmonary infarction of the middle lobe (Fig 1B). The presence of cement in the pulmonary arteries of the middle lobe and several segmental arteries of the superior and lower lobes confirmed a pulmonary embolism caused by cement (Fig 1C). CT showed the origin of the leak arose at the level of the vertebroplasty, revealing cement in a right lateroverterbral vein draining into the inferior vena cava (Fig 1D). A small asymptomatic epidural leak was also observed. The patient was treated with anticoagulants and responded favorably, with regression of dyspnea and tachycardia and normalization of blood gases. Follow-up CT 1 month later revealed progressive resolution of the middle lobe infarction (Fig 1E).

Discussion

Although percutaneous vertebroplasty is considered only minimally invasive, complications can occur during the procedure. Cement leaks into the external vertebral venous plexuses have frequently been described. There is also a potential risk of cement migration into the inferior vena cava (4) and pulmonary embolism. Nevertheless, we failed to find any documented report of symptomatic pulmonary embolism caused by acrylic cement. This is probably because of the extremely rapid polymerization of the PMMA before it reaches the vena cava. Jensen et al (5) reported two patients with presumed embolization to the lungs that did not evince respiratory changes. Venous leaks can also occur toward the internal vertebral venous plexuses resulting in cord or nerve root compression (3). The great majority of these leaks are asymptomatic. Such leaks can be explained by the fluid consistency of the PMMA at the moment of injection. More extensive leaks may occur if the needle is positioned incorrectly, especially if the tip lies in a basivertebral vein. Gangi et al (6) recommended that the technique be performed under both CT and fluoroscopic guidance to verify needle positioning.

The pulmonary embolism in our patient may have been caused by insufficient polymerization of the PMMA at the time of injection, which allowed

Received in original form May 11, 1998; accepted after revision July 20, 1998.

From the Department of Radiology (B.P., O.K., P.B.), Hôpital Pasteur, Nice, France, and the Department of Neuroradiology (P. P.-V.), Hôpital de la Timone, Marseille, France.

Address reprint requests to B. Padovani, Department of Radiology, Hôpital Pasteur, BP 69 06002 Nice, Cedex 1, France.

© American Society of Neuroradiology

KY 386805

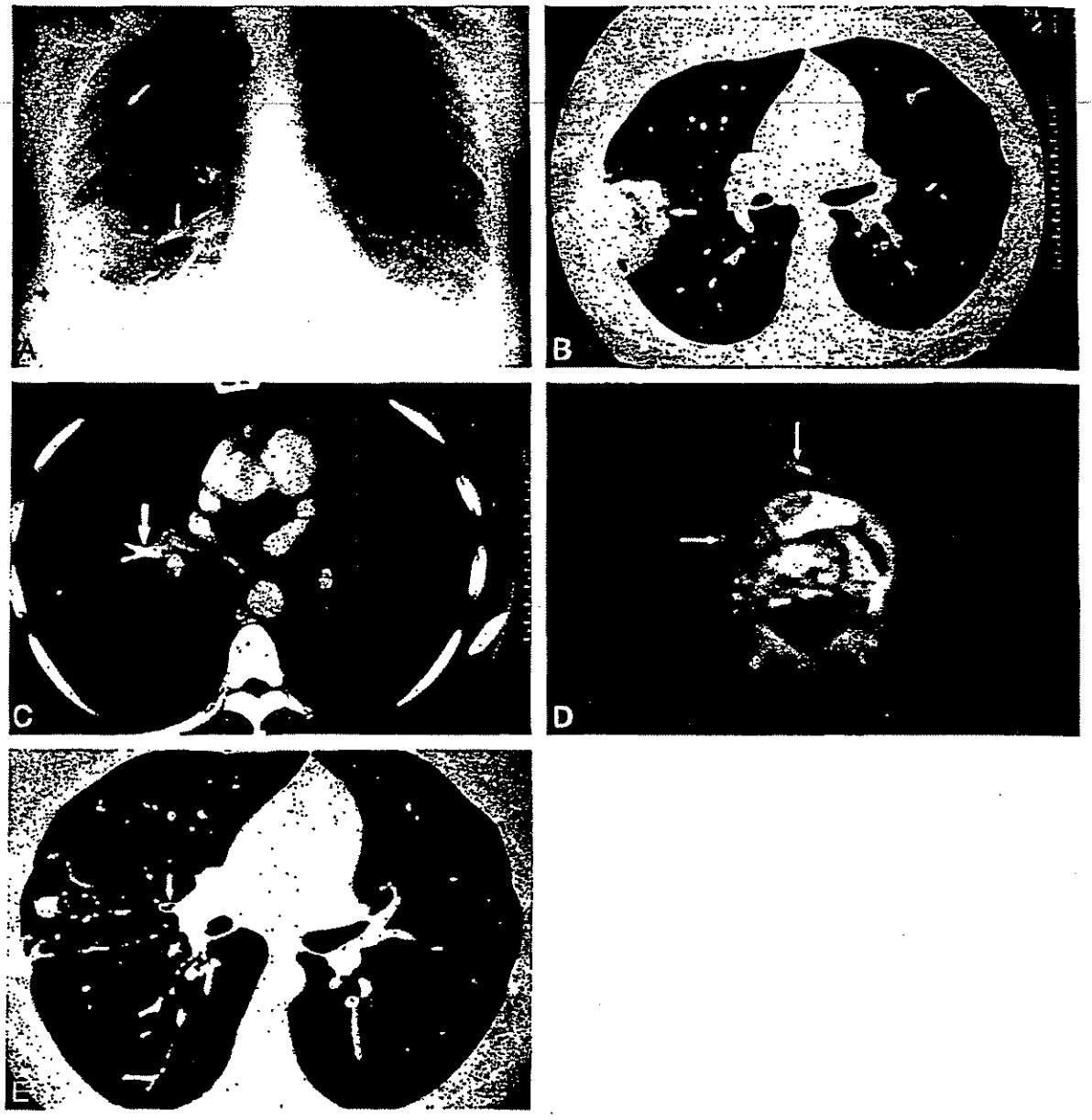

FIG 1. Chest radiograph and CT of 41-year-old woman with LCH after percutaneous vertebroplasty.

A, Chest radiograph shows pleural-based consolidation in the middle-lobe (*arrow-head*). Multiple high-density tubular opacities outlining pulmonary vessels (*white arrows*). Note a right pleural effusion (*black arrow*).

B, Chest CT scan at the level of bronchus intermedius shows characteristic appearance of pulmonary infarct in the middle lobe and pleural-based truncated cone consolidation (*white arrow*) between major and minor fissures.

C, Chest CT scan with soft tissue window settings. High-density intra-luminal cement (*arrow*) outlining the pulmonary artery and its bifurcation.

D, CT scan with bone settings at the level of vertebroplasty (L3) shows cement in right latero-vertebral vein draining in the vena cava (*arrows*).

E, Follow-up chest CT 1 month after vertebroplasty. Comparison with Fig. 1B shows partial resolution of the pulmonary infarct in the middle lobe and persistence of cement in pulmonary artery (*arrow*).

migration into the inferior vena cava and the pulmonary arteries. For this reason, the acrylic cement must be mixed to the consistency of paste (i.e. a stage of advanced polymerization) before injection so that the several difficult-to-evaluate factors that affect the polymerization rate (e.g. room temperature) can be better controlled. Good-quality lateral fluoroscopy is essential during injection. Detection of even minimal cement leakage into the perivertebral veins or behind the line of the posterior wall should be indications to halt the procedure immediately. In our case, pulmonary embolism occurred because perivertebral venous migration was not recognized. The cement was opacified only with tungsten powder. Jensen et al (5) recommend a barium/tungsten combination for adequate visualiza-

tion of needle positioning and venous flow during fluoroscopy. Moreover, real-time detection of latero-vertebral leakage remains difficult owing to overlap of the intravertebral cement. Biplane fluoroscopy or intermittent anteroposterior fluoroscopy could overcome this problem (5). The value of performing prior vertebral venography through the vertebroplasty needle is controversial. Jensen el al (5) found vertebrography to be of great use because it confirmed the needle position in the trabecular space and outlined the venous outflow pattern, showing where to look for PMMA migration. Some European authors (4, 6) have not performed vertebrography prior to vertebroplasty. Results appear doubtful to them because iodinated contrast agents have different physicochemical properties than PMMA, and nearly always diffuse into the venous plexuses. In addition, persistence of intravertebral opacifications could interfere with vertebroplasty.

Venous leaks are most frequent with highly vascular lesions (metastases of thyroid cancer, renal carcinoma, or vertebral angiomas). The main indications for vertebroplasty are osteolytic metastases, osteoporotic compression fractures, and vertebral hemangiomas. There are few reports in the literature of vertebroplasty for the treatment of LCH (7). These bone lesions are not histologically hypervascular, and it therefore seems difficult to attribute the lesion itself to the venous leak in our patient.

Nonetheless the literature does contain a report of a lethal pulmonary thromboembolism (4). A chest radiograph obtained in that case did not reveal any cement in the pulmonary arteries. By contrast, an acrylic cement embolism has been reported after hip replacement arthroplasty (8), although much more cement is used during arthroplasty than is required for vertebroplasty. In this study, however, these emboli detected by transesophageal sonography remained asymptomatic.

Interestingly, the vascular leak in our patient was not identified during the procedure, and diagnosis of pulmonary cement embolism was delayed. The lower chest pain felt immediately after the procedure was attributed to the vertebroplasty. It is not uncommon for patients to complain of local-regional pain 48 hours postoperatively, but discomfort usually subsides after nonsteroidal antiinflammatory drug administration. Misinterpretation of this patient's pain accounts for delay in diagnosis. Presence of chest pain should have suggested either a rib fracture or a pulmonary embolism, and a chest radiograph should have been taken immediately. The delayed onset of dyspnea that occurred after the patient had been discharged from the hospital may also explain the diagnostic delay. Furthermore, the embolism would probably have been diagnosed immediately if the patient had not been treated under general anesthesia. Several authors perform vertebroplasty under local anesthesia (3) or neuroanalgesia (5).

Anticoagulants appear to have been effective on the pulmonary infarction and clinical course of our patient, although it would be imprudent to recommend any therapeutic approach based on a single case. It would be interesting to perform a study with systematic chest radiographs after vertebroplasty in order to determine the incidence of pulmonary embolism caused by cement leakage and its impact on lung tissue.

References

1. Deramont H, Galibert R, Debussche-Depriester C. **Percutaneous vertebroplasty with methylmethacrylate: technique, method, results.** Abstract from the Radiological Society of North America, Chicago, 1990
2. Cotten A, Dewatre F, Cortet B, et al. **Percutaneous vertebroplasty for osteolytic metastases and myeloma: effects of the percentage of lesion filling and the leakage of methyl methacrylate at clinical follow-up.** *Radiology* 1996;200:525–530
3. Chiras J, Depriester C, Weill A, Sola-Martinez MT, Deramond H. **Vertébroplasties percutanées.** *J Neuroradiol* 1997;24:45–59
4. Weill A, Chiras J, Simon JM, Rose M, Sola-Martinez T, Enkaoua E. **Spinal metastases: indications for and results of percutaneous injection of acrylic surgical cement.** *Radiology* 1996;99: 241–247
5. Jensen ME, Avery JE, Mathis JM, Kallmes DF, Cloft HJ, Dion JE. **Percutaneous polymethylmethacrylate vertebroplasty in the treatment of osteoporotic vertebral body compression fractures: technical aspects.** *AJNR Am J Neuroradiol* 1997;18:1897–1904
6. Gangi A, Kastler BA, Dietemann JL. **Percutaneous vertebroplasty guided by a combination of CT and fluoroscopy.** *AJNR Am J Neuroradiol* 1994;15:83–86
7. Cardon T, Hachulla E, Flipo RM, et al. **Percutaneous vertebroplasty with acrylic cement in the treatment of a Langerhans cell vertebral histiocytosis.** *Clin Rheumatol* 1994;13:518–521
8. Propst JW, Siegel LC, Schmitger I, Foppiano L, Goodman SB, Brock-Utne JG. **Segmental wall motion abnormalities in patients undergoing total hip replacement: correlations with intraoperative events.** *Anesth Analg* 1993;77:743–749

F

5108404

PATENT APR 28 1992 PATENT NUMBER 5108404

FILING DATE	CLASS	SUBCLASS	L. NO.	GROUP ART UNIT	EXAMINER
08/15/90	128 606	94		3351	Rooney

EN: FREMONT, CA; MARK A. REILEY, OAKLAND, CA.

ING DATA**********
D: THIS APPLN IS A CIP OF 07/308,724 02/09/89 Patent No. 4,969,888

Certificate
DEC 0 2 2003
of Correction

FOREIGN/PCT APPLICATIONS******** None
VERIFIED:
KGF

04/09/89

FOREIGN FILING LICENSE GRANTED 08/28/90 ***** SMALL ENTITY *****

Foreign priority claimed 35 USC 119 conditions met	Verified and Acknowledged Examiner's Initials	AS FILED	STATE OR COUNTRY	SHEETS DRWGS.	TOTAL CLAIMS	INDEP. CLAIMS	FILING FEE RECEIVED	ATTORNEY'S DOCKET NO.
☐yes ☑no ☐yes ☐no	KGF		CA	11	45	3	$ 335.00	12727-2-1

ADDRESS
TOWNSEND & AND TOWNSEND
STEUART STREET TOWER
ONE MARKET PLAZA
SAN FRANCISCO, CA 94105

TITLE
SURGICAL PROTOCOL FOR FIXATION OF BONE USING INFLATABLE DEVICE

U.S. DEPT. of COMM.-Pat. & TM Office—PTO-436L (rev. 10-78)

PARTS OF APPLICATION FILED SEPARATELY

NOTICE OF ALLOWANCE MAILED	PREPARED FOR ISSUE	CLAIMS ALLOWED	
10-22-91	KEVIN G. ROONEY Assistant Examiner; Docket Clerk	Total Claims 29	Print Claim 1

ISSUE FEE		DRAWING		
Amount Due	Date Paid	Sheets Drwg.	Figs. Drwg.	Print Fig.
$525.00	1-24-92 BT	11	38	28 A-E

ROBERT A. HAFER
S.P.E.
ART UNIT 331 Primary Examiner

FORM PTO-1257-U.S. DEPT. OF COMMERCE (REV. 8-78) PAT. & TM OFF.
DISCLAIMER LABEL

SERIAL NO.	FILING DATE
07/567862	08/15/90

A terminal disclaimer has been entered and recorded under 35 U.S.C. 253 in this file by Patent Issue Division.

DO NOT DESTROY

Form PTO-436
Rev. 5/89

ISSUE CLASSIFICATION		ISSUE BATCH NUMBER
es 606	Subclass 94	U06

RNING: The information disclosed herein may be restricted. Unauthorized disclosure may be prohibited by the United States Code Title 35, Sections 122, 181 and 368. Possession outside the U.S. Patent & Trademark Office is restricted to authorized employees and contractors only.

KY 228908

MAIL ROOM AUG 15 1990 PATENT & TRADEMARK OFFICE
PATENT & TRADEMARK OFFICE RECEIVED NOV 09 1990 CERTIFICATE OF CORRECTION BR.

Attorney Docket No. 12727-2-1

I hereby certify that this is being deposited with the United States Postal Service "Express Mail Post Office to Addressee on the date indicated above and is addressed to: Commissioner of Patents and Trademarks, Washington, D.C. 20231, on August 15, 1990.

TOWNSEND AND TOWNSEND

By: *John Quintanilla*
John Quintanilla

IN THE UNITED STATES PATENT AND TRADEMARK OFFICE

In re CIP application of)
ARIE SCHOLTEN ET AL)
Serial No. FILED HEREWITH)
Filed: HEREWITH)
For: SURGICAL PROTOCOL FOR FIXATION OF BONE USING INFLATABLE DEVICE)

Examiner: ~~K. Rodney~~
Art Unit No. ~~831~~ 335

TERMINAL DISCLAIMER

San Francisco, California 94105

Dated: August 15, 1990

Honorable Commissioner of
Patents and Trademarks
Washington, D.C. 20231

RECEIVED SEP 05 1990 APPLICATION DIVISION

Sir:

Your petitioners, ARIE SCHOLTEN and MARK A. REILLY, residing at 4175 Tamayo Street, Fremont, California 94536 and 333 63rd Street, Oakland, California 94610, respectively, represent that they are the applicants and owners of the above continuation-in-part patent application filed herewith, for SURGICAL PROTOCOL FOR FIXATION OF BONE USING INFLATABLE DEVICE. Your petitioners hereby disclaim the terminal part of any patent granted on the above-identified continuation-in-part application, which would extend beyond the full statutory term of a United States patent issuing from U.S. Patent Application Serial No. 07/308,724, filed February 9, 1989, and hereby agree that

any patent so granted on the above-identified continuation-in-part application shall be enforceable only for and during such period that the legal title to said patent shall be the same as the legal title to a United States patent issuing from U.S. Patent Application Serial No. 07/308,724, filed February 9, 1989, this agreement to run with any patent granted on the above-identified continuation-in-part application and to be binding upon the grantees, their successors or assigns.

Petitioners do not disclaim any terminal part of any patent granted on the above-identified continuation-in-part application prior to the expiration date of the full statutory term of a United States patent issuing from U.S. Patent Application Serial No. 07/308,724 filed February 9, 1989 in the event that it later: expires for failure to pay a maintenance fee, is held unenforceable, is found invalid, is statutorily disclaimed in whole or terminally disclaimed under 37 CFR 1.321(a), has all claims cancelled by a reexamination certificate, or is otherwise terminated prior to the expiration of its statutory term, except for the separation of legal title stated above.

PETITIONER

Arie Scholten

Date: 8/14/90

PETITIONER

Mark A. Reiley

Date: 8/6/90

G



07/308724	PATENT DATE NOV 06 1990	ENT ER

AL NUMBER	FILING DATE	CLASS	SUBCLASS	GROUP ART UNIT	EXAMINER
7/308,724	02/09/89	128	92	~~330~~ 331	Looney

RIE SCHOLTEN, FREMONT, CA; MARK A. REILEY, OAKLAND, CA.

CONTINUING DATA******** None
VERIFIED
KGR

FOREIGN/PCT APPLICATIONS******** None
VERIFIED
KGR

EIGN FILING LICENSE GRANTED 02/28/89 ***** SMALL ENTITY *****

gn priority claimed ☐yes ☒no / USC 119 conditions met ☐yes ☐no	AS FILED	STATE OR COUNTRY	SHEETS DRWGS.	TOTAL CLAIMS	INDEP. CLAIMS	FILING FEE RECEIVED	ATTORNEY'S DOCKET NO.
rified and Acknowledged KGR Examiner's Initials	→	CA	11	45	3	$ 320.00	127272

TOWNSEND AND TOWNSEND
STEUART STREET TOWER, ONE MARKET PLAZA
SAN FRANCISCO, CA 94105

SURGICAL PROTOCOL FOR FIXATION OF OSTEOPOROTIC BONE USING INFLATABLE DEVICE

U.S. DEPT. of COMM.-Pat. & TM Office — PTO-436L (rev. 10-78)

SK

RTS OF APPLICATION
ED SEPARATELY 3-12

ITICE OF ALLOWANCE MAILED	PREPARED FOR ISSUE	CLAIMS ALLOWED
3-15-90	KEVIN G. Looney / Assistant Examiner KGR; E. Cochet / Docket Clerk	Total Claims 28; Print Claim 1

ISSUE FEE		
ount Due	Date Paid	
310.00	6-18-90	

ROBERT A. [illegible] S.P.E. ART UNIT 331 / Primary Examiner

DRAWING

Sheets Drwg.	Figs. Drwg.	Print Fig.
11	38	28A-E

ISSUE CLASSIFICATION

Class	Subclass
606	94

ISSUE BATCH NUMBER D81

Label Area

WARNING: The information disclosed herein may be restricted. Unauthorized disclosure may be prohibited by the United States Code Title 35, Sections 122, 181 and 368. Possession outside the U.S. Patent & Trademark Office is restricted to authorized employees and contractors only.

PTO-436

KY 228787

MAIL ROOM DEC 1 1989 PATENT & TRADE MARK OFF.

Attorney Docket No. 12727-2

I hereby certify that this is being deposited with the United States Postal Service on the date indicated above and is addressed to the Commissioner of Patents and Trademarks, Washington, D.C. 20231, on November 28, 1989.

By: Jeanette L. Taplin

IN THE UNITED STATES PATENT AND TRADEMARK OFFICE

In re application of

ARIE SCHOLTEN ET AL.

Serial No. 07/308,724

Filed: February 9, 1989

For: SURGICAL PROTOCOL FOR FIXATION OF OSTEOPOROTIC BONE USING INFLATABLE DEVICE

Examiner: K. Rooney

Art Unit: 331

AMENDMENT

San Francisco, CA 94105
California 94105

Dated: November 28, 1989

Honorable Commissioner of
Patents and Trademarks
Washington, D.C. 20231

Sir:

In response to the Office Action of August 30, 1989, please amend the above application as follows:

IN THE SPECIFICATION:

Page 7, line 28, erase "no" and insert --not--.

Page 9, line 8, erase "30" and insert --31--. Line 14, erase "30" and insert --31--.

Page 12, line 14, after "device" insert --or chambered bladder--. Line 23, after "shaped" insert --or cylindrically shaped device of--.

IN THE CLAIMS:

Cancel Claims 7, 34 and 40.

Claim 3, line 2, erase "increasing" and insert --compacting--.

Claim 4, line 2, erase "compacting" and insert --directing--. Line 4, after "fracture" insert --or impending fracture--.

Claim 6, line 2, erase "bone" and insert --passage--.

Claim 9, line 2, before "into" insert --through--. Line 3, before "bone" insert --proximate cortical--. Line 3, after "bone" insert --marrow--.

Claim 10, line 1, erase "7" and insert --8--.

Claim 17, line 2, after "a" insert --chambered bladder--.

Claim 18, line 2, after "a" insert --chambered bladder--. Line 3, erase "checker-shaped" and insert --generally cylindrical--.

Claim 22, line 2, erase "increasing" and insert --inflating--.

Claim 23, line 2, erase "forcing" and insert --inflating--.

Claim 24, line 3, erase "is" and insert --its--.

Claim 25, line 2, erase "forming" and insert --drilling--.

Claim 31, line 2, erase "balloon" and insert --chambered bladder--. Same line, erase "sheet".

Claim 32, line 2, erase "checker-shaped" and insert --substantially cylindrical--.

Claim 35, line 2, erase "checker-shaped" and insert --substantially cylindrical--.

Claim 37, line 1, erase "1" and insert --30--.

Rewrite the following Claims 1, 2, 5, 15, 16 and 21.

1. ~~(Amended)~~ A method of fixation of a fracture or impending fracture of an osteoporotic bone having osteoporotic bone marrow therein comprising:

forming a passage in the bone marrow;

[increasing] compacting the bone marrow to increase the volume of said passage and

filling the passage with a flowable material capable of setting to a hardened condition.

2. ~~(Amended)~~ A method as set forth in claim 1, wherein said [increasing] compacting step includes [compacting] forcing the osteoporotic bone marrow [in the bone] outwardly and against the site of the fracture or impending fracture.

5. A method as set forth in Claim 1, wherein said [increasing] compacting step includes inflating an inflatable device in said [bone to compact] passage to urge the osteoporotic bone marrow therein.

14 ~~15~~. (Amended) A method as set forth in Claim 1, wherein said flowable material is selected from the group consisting of liquid synthetic bone [or] and methyl methacrylate cement.

15 ~~16~~. (Amended) A method of fixation of an osteoporotic fracture of a bone containing osteoporotic bone marrow therein comprising:

drilling said bone to form a passage therein;

inserting an inflatable device in said [passage] recess;

inflating the device in the passage to increase the volume thereof and to force the osteoporotic bone marrow outwardly of the passage and against the bone to form a void in the bone; and

filling the void in the bone with a flowable material capable of setting to a hardened condition.

21. (Amended) A method as set forth in Claim 16, wherein said inflating step includes compacting the osteoporotic bone marrow [in] against the bone at the fracture site thereof.

REMARKS

Claim 1-6, 8-39 and 41-45 remain in this application.

Claim 1 has been amended to recite the step of compacting the bone marrow to increase the volume of the recess, and then filling the recess with a flowable material capable of setting to a hardened condition. Claim 1 as amended is allowable under 35 U.S.C. 102(b) over Lee et al.

Lee shows an inflatable device 32 for closing or sealing one end of a hollow bone 10. However, there is no teaching in Lee of the combination of steps of amended Claim 1 because Lee fails to even remotely suggest the compacting of the bone marrow in the bone to increase the volume of a recess so that the recess can be filled with a flowable material capable of setting to a hardened condition.

Lee shows a balloon or inflatable device through which a tube 34 is passed to inject cement under pressure

KY 228857

into bone 10. The balloon merely forms a closure or seal on the top of the bone which is not fractured so as to compress the cement in the bone. The function of the balloon of the Lee patent is to serve as a plug and not as an expander of a recess containing bone marrow. It does not in any conceivable way compress bone marrow against a cortical bone. Thus, Claim 1 is allowable under 35 U.S.C. 102(b) over Lee et al.

Claim 2-4, 8-10 and 15 depend from allowable Claim 1 and are allowable for the same reasons as the latter over Lee et al. under 35 U.S.C. 102(b).

Claim 1 is allowable under 35 U.S.C. 102(b) over Murray because the claim recites a combination of steps not shown by Murray in the sense of 35 U.S.C. 102(b). Murray shows an expandable pair of end devices which operate as seals in the process of flowing liquid bone cement into the hollow medullary canal of a bone. However, the bone is previously reamed to eliminate the bone marrow therefrom; thus, there is no teaching or suggestion that the expandable devices at the end of the injector device are used for anything other than plugs or seals. They are not used to compact bone marrow against the inner surface of a cortical bone. One of the devices is used is to plug the open bottom of the cavity, the other device is used to plug the opposite open end of the cavity. Thus, Claim 1 is allowable under 35 U.S.C. 102(b) over Murray.

Claims 2-6 and 8-10 depend from allowable Claim 1 and are allowable over Murray under 35 U.S.C. 102(b) for the same reasons as Claim 1.

Claim 16 recites the same combination of elements as allowable Claim 1 and is distinguished over Claim 1 by reciting the step of inserting an inflatable device in the

recess. Claim 16, like Claim 1, recites the step of inflating the device to force the bone marrow outwardly of the recess and against the bone to form a void in the bone. Thus, the bone marrow is not removed from the bone as in the case of Murray, and Murray fails to teach or suggest the combination of steps of Claim 16. Thus, Claim 16 is allowable under 35 U.S.C. 102(b) over Murray.

Claim 17-25 depend from allowable Claim 1 and are allowable under 35 U.S.C. 102(b) over Murray for the same reasons as Claim 1.

Claim 30 recites an inflatable device having an outer surface substantially the same as that of the cortical inner surface of a bone. This is a limitation not shown in Murray who shows end seal devices in a bone for plugging the open ends of a bone against the flow of cement out of the bone. The device used to plug the ends of the bone by Murray do not have substantially the same configuration as the inner surface of the bone. This is clearly shown in Figs. 9-12 of Murray. Thus, Claim 30 and dependent Claims 31-33 are allowable under 35 U.S.C. 102(b) over Murray.

Claim 1 as amended is allowable under 35 U.S.C. 103 over Murray because the claim recites the step of compacting the bone marrow in the bone to increase the volume of a recess formed in the bone so that the recess can be filled with a flowable material capable of setting to a hardened condition. In Murray, there is no teaching or suggestion that the devices at the ends of the bone are nothing more than plugs. They do not operate to compact the bone marrow because the bone marrow has already been removed from the bone when the expandable devices are inserted into the bone at the ends thereof. Thus, one of ordinary skill

in the art with the Murray patent before him would have no teaching or suggestion of the combination of elements of Claim 1 without the benefit of Applicants' own disclosure. Thus, Claim 1 and dependent Claims 11-15 are allowable under 35 U.S.C. 103 over Murray.

Claim 16 recites the same combination of steps as allowable Claim 1 except that Claim 16 includes the further step of inserting an inflatable device in the recess. Thus, Claim 16 is allowable under 35 U.S.C. 103 over Murray because Murray fails to teach the step of inflating a device to force bone marrow outwardly of the recess and against the bone to form a void in the bone so that the void can be filled with a flowable material capable of setting to a hardened condition. The devices at the ends of the bone of Murray do not operate to compact or force the bone marrow outwardly of a recess. Only in light of Applicants' own disclosure would the combination of steps of Claim 16 be obvious to a person of ordinary skill in the art. Thus, Claim 16 and dependent Claims 26-29 are allowable under 35 U.S.C. 103 over Murray.

Claim 30 recites that the inflatable device is used for compacting bone marrow and that the device has a configuration substantially the same as the cortical inner surface of the bone in which it is used. Thus, Claim 30 is allowable under 35 U.S.C. 103 over Murray because Murray merely shows a pair of end plugs which are expandable to close the ends of the bone so that a cement can be forced into the bone between the plugs. No mention or teaching is made in Murray of the fact that the devices at the ends of the bone have configurations substantially the same as that of the cortical inner surface or that the bone marrow can be compacted in a bone. One of ordinary skill in the art with

the Murray patent before him would have no teaching or suggestion of the inflatable device of Claim 30 without the benefit of Applicants' own disclosure. Thus, Claim 30 and dependent Claims 34-45 are allowable under 35 U.S.C. 103 over Murray.

Claim 15 has been amended to avoid the rejection under 35 U.S.C. 112, second paragraph. The terms checker-shaped, gourd-shaped and globe-shaped have been removed from the claims as suggested by the Examiner. The term "oblique" is considered to be appropriate because the dictionary definition of the term is "neither perpendicular nor parallel".

Thus, it is respectfully requested that the rejection against certain claims under 35 U.S.C. 112, second paragraph, be withdrawn.

The secondary references of record which have not been applied against the claims are defective as references against the claims because they fail to teach or suggest the combination of steps and the combination of elements of the remaining claims therein.

Favorable action on the merits of this application is respectfully requested.

Dated: November 28, 1989

Respectfully submitted,

TOWNSEND & TOWNSEND

By: 

John L. McGannon
Registration No. 22,414

Telephone: (415) 324-2600
JLM/jlt

KY 228861

UNITED STATES DEPARTMENT OF COMMERCE
Patent and Trademark Office
Address: COMMISSIONER OF PATENTS AND TRADEMARKS
Washington, D.C. 20231

SERIAL NUMBER	FILING DATE	FIRST NAMED APPLICANT	ATTORNEY DOCKET NO.

TOWNSEND AND TOWNSEND
STEJART STREET TOWER, ONE MARKET PLAZA
SAN FRANCISCO, CA 94105

EXAMINER	
ART UNIT	PAPER NUMBER
	5

DATE MAILED:

EXAMINER INTERVIEW SUMMARY RECORD

All participants (applicant, applicant's representative, PTO personnel):

(1) John McCarron (3) ____

(2) Kevin Kooney (4) ____

Date of interview: 3/6/01

Type: ☒ Telephonic ☐ Personal (copy is given to ☐ applicant ☐ applicant's representative).

Exhibit shown or demonstration conducted: ☐ Yes ☐ No. If yes, brief description: ____

Agreement ☒ was reached with respect to some or all of the claims in question. ☐ was not reached.

Claims discussed: ____

Identification of prior art discussed: ____

Description of the general nature of what was agreed to if an agreement was reached, or any other comments:
Agreed to cancel claims drawn to the device in an Examiner's Amend.

(A fuller description, if necessary, and a copy of the amendments, if available, which the examiner agreed would render the claims allowable must be attached. Also, where no copy of the amendments which would render the claims allowable is available, a summary thereof must be attached.)

Unless the paragraphs below have been checked to indicate to the contrary, A FORMAL WRITTEN RESPONSE TO THE LAST OFFICE ACTION IS NOT WAIVED AND MUST INCLUDE THE SUBSTANCE OF THE INTERVIEW (e.g., items 1–7 on the reverse side of this form). If a response to the last Office action has already been filed, then applicant is given one month from this interview date to provide a statement of the substance of the interview.

☒ It is not necessary for applicant to provide a separate record of the substance of the interview.

☐ Since the examiner's interview summary above (including any attachments) reflects a complete response to each of the objections, rejections and requirements that may be present in the last Office action, and since the claims are now allowable, this completed form is considered to fulfill the response requirements of the last Office action.

K.G. Kooney
Examiner's Signature

PTOL-413 (REV. 1-84)

ORIGINAL FOR INSERTION IN RIGHT HAND FLAP OF FILE WRAPPER

KY 228862

UNITED STATES DEPARTMENT OF COMMERCE
Patent and Trademark Office
Address: COMMISSIONER OF PATENTS AND TRADEMARKS
Washington, D.C. 20231

E. Colbert 3-7-90

SERIAL NUMBER	FILING DATE	FIRST NAMED APPLICANT	ATTORNEY DOCKET NO.
07/293,729	02/09/89	SCHOLTEN A	127272

TOWNSEND AND TOWNSEND
STEUART STREET TOWER, ONE MARKET PLAZA
SAN FRANCISCO, CA 94105

EXAMINER	
ROONEY, K	
ART UNIT	PAPER NUMBER
331	6/8

DATE MAILED: 03/15/90

NOTICE OF ALLOWABILITY

PART I.

1. ☑ This communication is responsive to Amend. A + Exmrs Amend.
2. ☑ All the claims being allowable, PROSECUTION ON THE MERITS IS (OR REMAINS) CLOSED in this application. If not included herewith (or previously mailed), a Notice Of Allowance And Issue Fee Due or other appropriate communication will be sent in due course.
3. ☑ The allowed claims are 1-16, 8-29
4. ☐ The drawings filed on _____ are acceptable.
5. ☐ Acknowledgment is made of the claim for priority under 35 U.S.C. 119. The certified copy has [_] been received. [_] not been received. [_] been filed in parent application Serial No. _____, filed on _____
6. ☑ Note the attached Examiner's Amendment.
7. ☑ Note the attached Examiner Interview Summary Record, PTOL-413.
8. ☐ Note the attached Examiner's Statement of Reasons for Allowance.
9. ☑ Note the attached NOTICE OF REFERENCES CITED, PTO-892.
10. ☑ Note the attached INFORMATION DISCLOSURE CITATION, PTO-1449.

PART II.

A SHORTENED STATUTORY PERIOD FOR RESPONSE to comply with the requirements noted below is set to EXPIRE THREE MONTHS FROM THE "DATE MAILED" indicated on this form. Failure to timely comply will result in the ABANDONMENT of this application. Extensions of time may be obtained under the provisions of 37 CFR 1.136(a).

1. ☐ Note the attached EXAMINER'S AMENDMENT or NOTICE OF INFORMAL APPLICATION, PTO-152, which discloses that the oath or declaration is deficient. A SUBSTITUTE OATH OR DECLARATION IS REQUIRED.
2. ☑ APPLICANT MUST MAKE THE DRAWING CHANGES INDICATED BELOW IN THE MANNER SET FORTH ON THE REVERSE SIDE OF THIS PAPER.
   a. ☑ Drawing informalities are indicated on the NOTICE RE PATENT DRAWINGS, PTO-948, attached hereto or to Paper No. _____. CORRECTION IS REQUIRED.
   b. ☐ The proposed drawing correction filed on _____, has been approved by the examiner. CORRECTION IS REQUIRED.
   c. ☐ Approved drawing corrections are described by the examiner in the attached EXAMINER'S AMENDMENT. CORRECTION IS REQUIRED.
   d. ☑ Formal drawings are now REQUIRED.

Any response to this letter should include in the upper right hand corner, the following information from the NOTICE OF ALLOWANCE AND ISSUE FEE DUE: ISSUE BATCH NUMBER, DATE OF THE NOTICE OF ALLOWANCE, AND SERIAL NUMBER.

Attachments:

- ✓ Examiner's Amendment
- ✓ Examiner Interview Summary Record, PTOL-413
- _ Reasons for Allowance
- ✓ Notice of References Cited, PTO-892
- ✓ Information Disclosure Citation, PTO-1449
- _ Notice of Informal Application, PTO-152
- _ Notice re Patent Drawings, PTO-948
- _ Listing of Bonded Draftsmen
- _ Other

Robert A. Hafer
ROBERT A. HAFER
S.P.E.
ART UNIT 33

PTOL-37 (REV. 11-88) USCOMM-DC 89-0615

KY 228863

An Examiner's Amendment to the record appears below. Should the changes and/or additions be unacceptable to applicant, an amendment may be filed as provided by 37 C.F.R. § 1.312. To ensure consideration of such an amendment, it MUST be submitted no later than the payment of the Issue Fee.

Claims 30-33, 35-39 and 41-45 have been cancelled.

This amendment was necessary to place the case in condition for allowance by cancelling the product claims which were not deemed to be patentable.

Authorization for this Examiner's Amendment was given in a telephone interview with Mr. McGannon on 3/6/90.

KGR
3/7/90

ROBERT A. HAFER
S.P.E.
ART UNIT 331