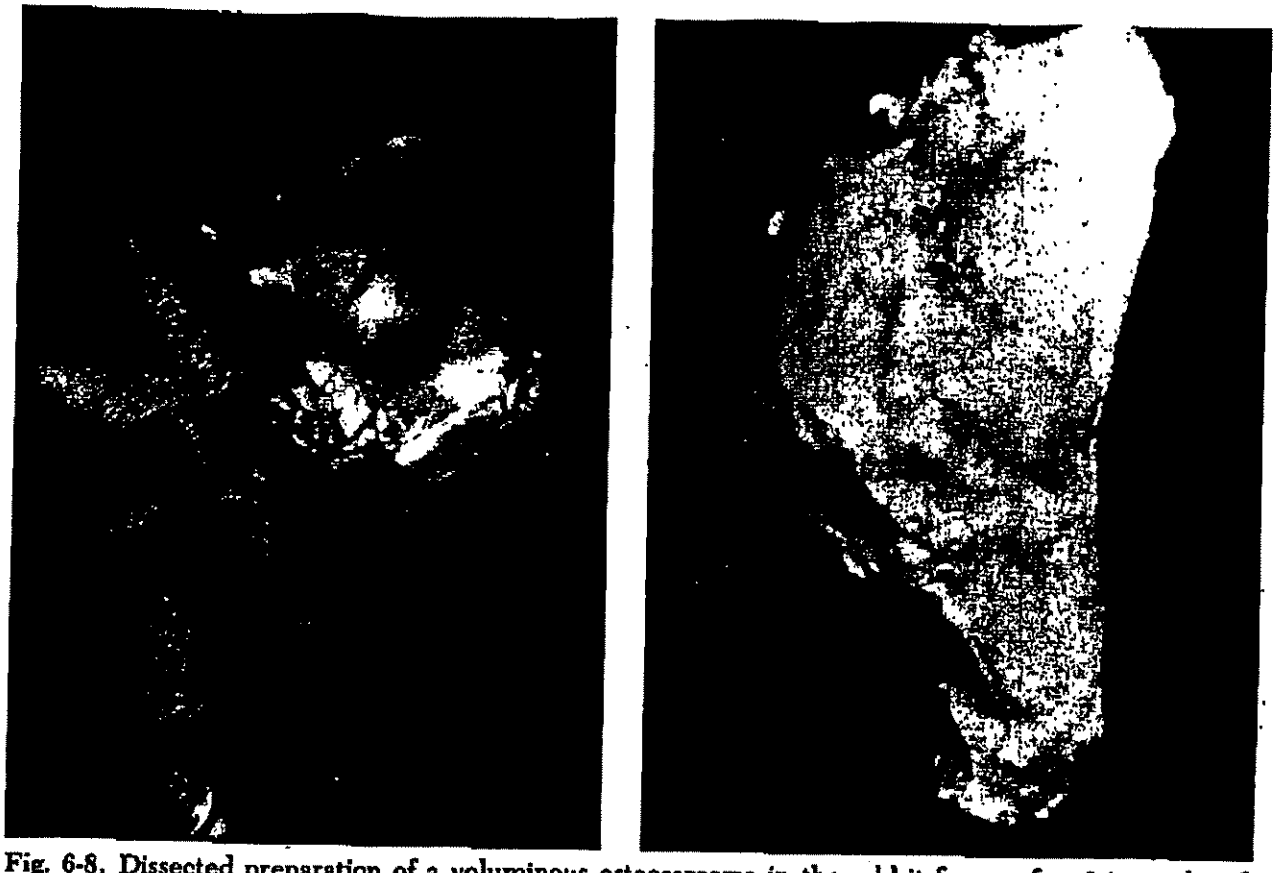

Fig. 6-8. Dissected preparation of a voluminous osteosarcoma in the rabbit femur after 14 months of growth.

Twenty-four hours after the implantation wide necroses are formed in the cement contact area, marked by a hemorrhagic border with accumulation of edema. This border of the sarcomatous stroma reached an average of 2 mm with the small cement plug used here. But even 4 weeks after the cement implantation one could also distinctly see necrotic tumor areas bordering on unaffected sarcoma tissue. The necroses were marked by enlargement of the lacunae of the osteocytes and wasting of the nuclei. After 10 weeks persisting necrotic areas were found with decaying trabeculae, as well as partly well-preserved bone structures. Most of all, one found totally unaffected and newly grown and infiltrating tumor areas. This transition zone with only partially damaged sarcoma tissue or new-grown cells, as well as unaffected areas, was seen an average of 3–5 mm from the cement border.

In Vitro Experiments

In the comparative in vitro experiments the toxicity of the liquid component of methyl methacrylate was tested. It was found in several series using 5,000 suspended mouse lymphoma cells of the type L-51784 that even a minimal concentration (3 μg monomer/L) caused a 90% reduction of the cell growth. To test already hardened bone cement, discs 2 mm thick were laid onto tissue cultures of the following highly susceptible cell systems: human subcutaneous fibroblasts (Fig. 6-14B; embryonic fibroblasts of the umbilical cord (Fig. 6-14A) and HeLa tumor cells (Fig. 6-14C).

The scanning electron microscopic examinations (magnification ×160 to ×7,800) showed that unaffected cells had grown on the cement surface in three cell cultures of several series. No significant



Fig. 6-9. (A–C) Three examples of the first stage of intraosseous growth as a recognizable sign of sarcoma development on radiographs. (D–F) Second stage of sarcoma development: various degrees of parosteal reaction. *(Figure continues.)*

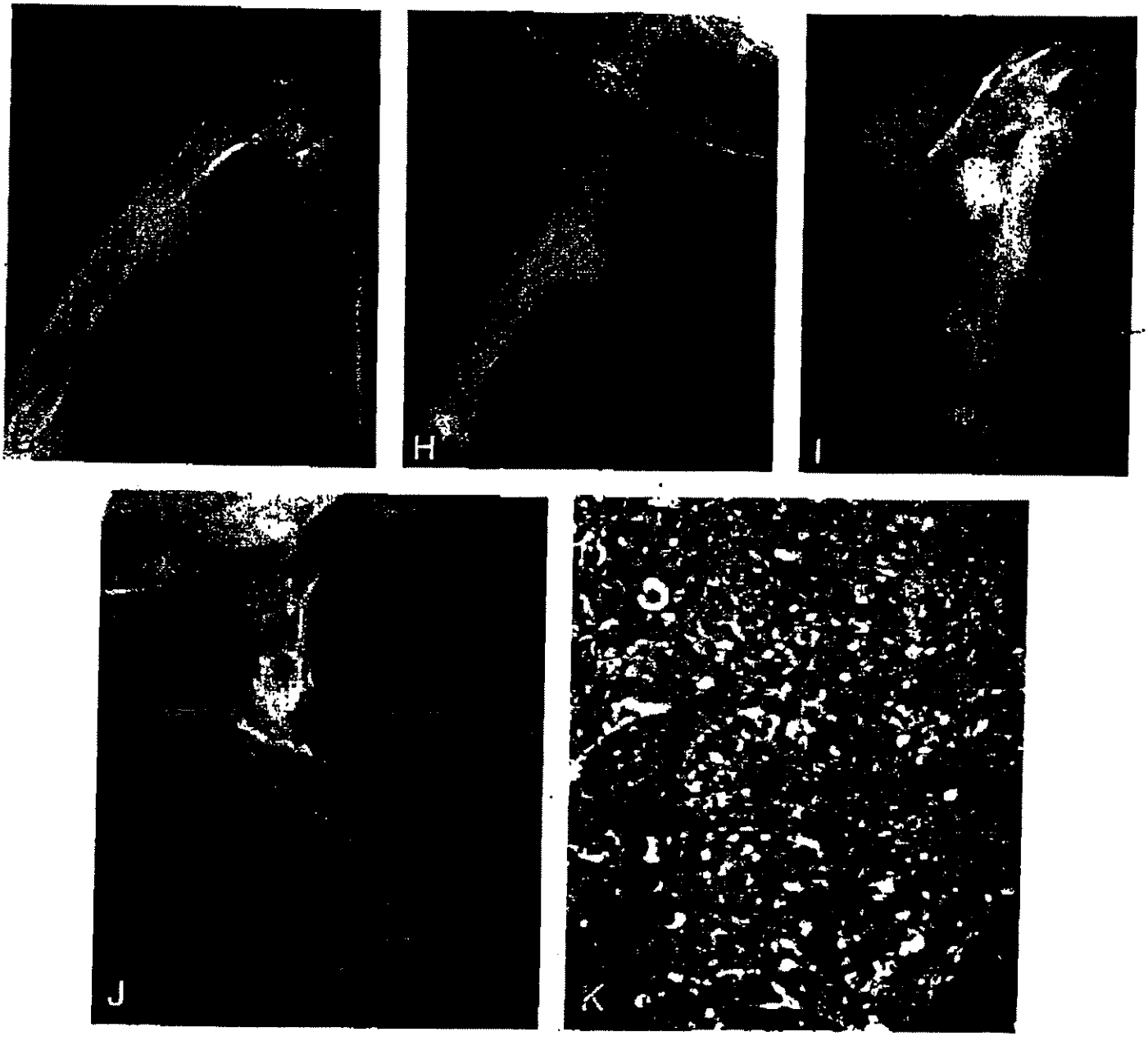

Fig. 6-9 *(Continued).* **(G–I) Progressive soft part infiltration and pathologic fractures form the third stage of sarcoma development. (J,K) Pathologic fracture and corresponding histologic section (original magnification ×80) of a chondrosarcoma 12 months after implantation of carcinogen.**



Fig. 6-10. Scintigram (A) and computed tomogram (B) of an osteosarcoma in the femur shaft after 10 months.

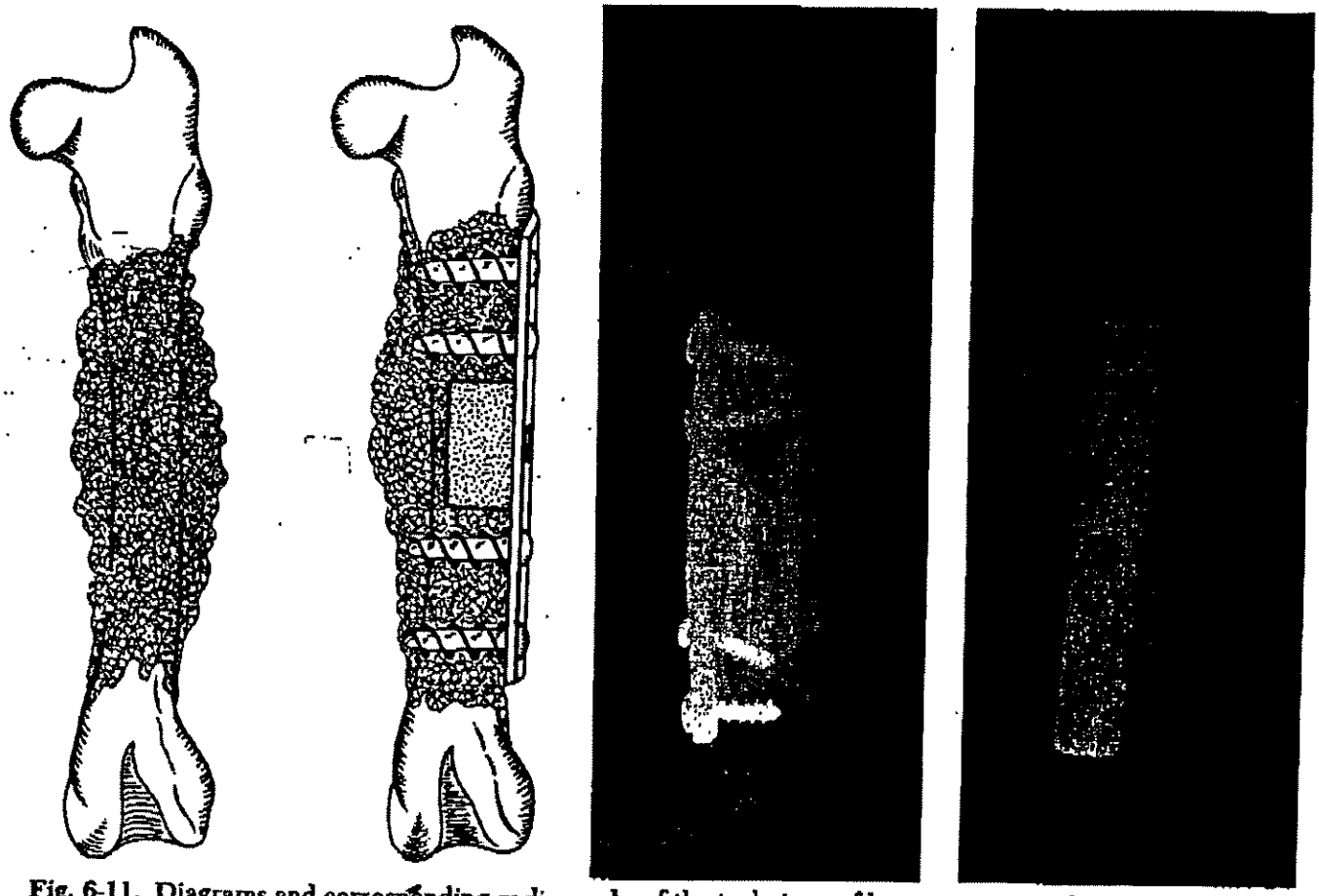

Fig. 6-11. Diagrams and corresponding radiographs of the technique of bone cement implantation using combined osteosynthesis.

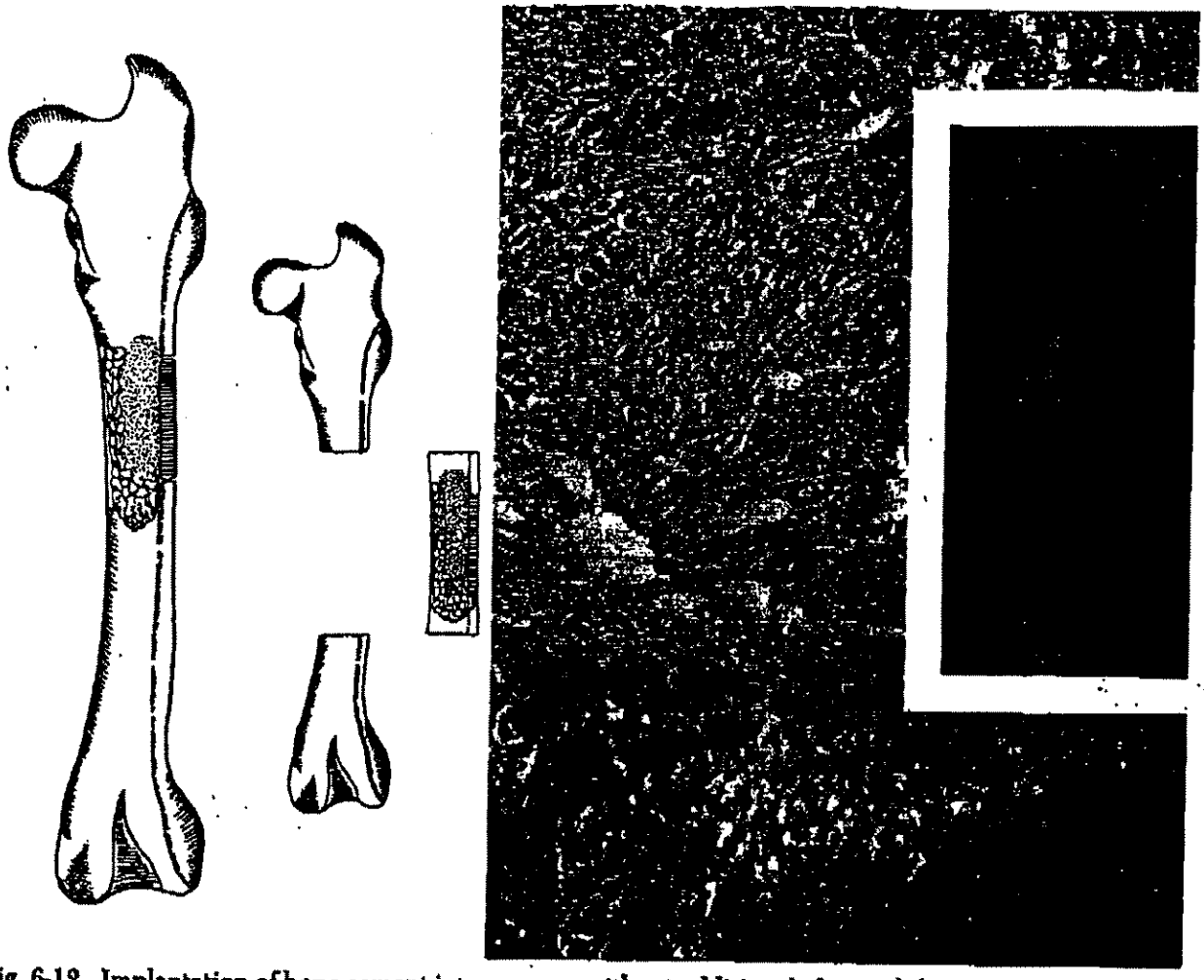

Fig. 6-12. Implantation of bone cement into sarcoma without additional plate stabilization. Histologically, the cement plug is delimited from the fibrosarcoma cells by dark necrotic areas (original magnification ×180).

deviations in the extent of the cell growth could be observed between the different cell groups.

DISCUSSION

How are these results to be interpreted? In our opinion,[5] the primary cause of the destruction of the sarcoma cells in the cement contact area appears to be the polymerization heat, to which tumor tissue is far more sensitive than normal tissue. With the small volume of cement used here, the temperature rose up to 55°C, as we know from thermoprobe measurements taken at different places. The cytotoxic effect of the monomer could also be responsible for the direct and succeeding lesion of bone tumor cells.[7]

The lysis of tumor cells at a greater distance from the implant presumably result from reduced oxygen supply due to damage of the intramedullary vessels and a mechanical alteration due to the preparation of the implant bed. This oxygen deficiency is significant in connection with the coincident polymerization hyperthermia, which is critical for the tumor cell metabolism.[6] Duration and penetration of this reaction on the tumor tissue, however, are too short and too low to be able to destroy all tumor cells securely and durably.

For this purpose, a special "tumor cement" with a higher polymerization temperature and a longer

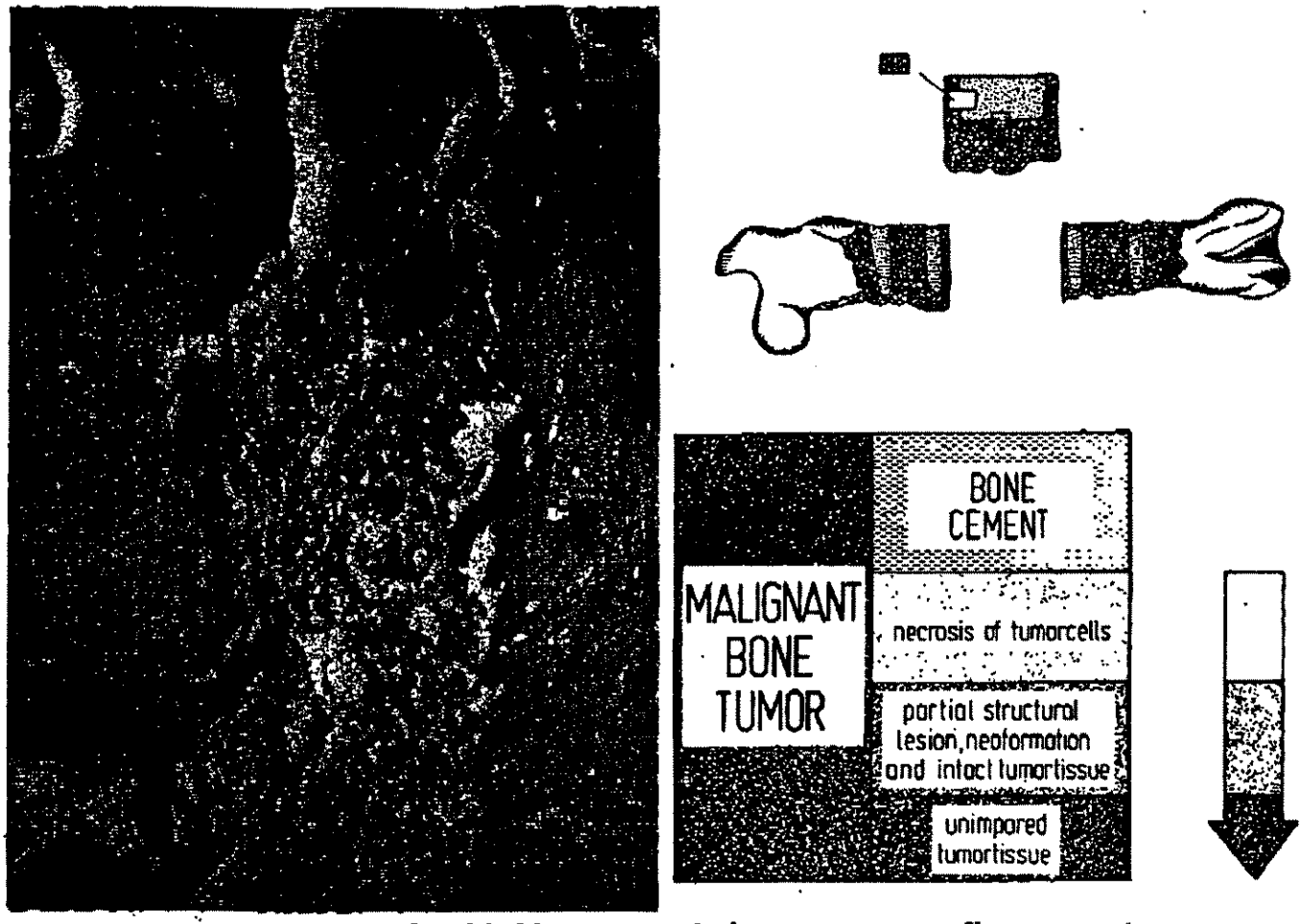

Fig. 6-13. Histologic section and model of the primary and subsequent reactions of bone cement in sarcoma tissue (×180).

and stronger action of the cytotoxic monomer would be suitable. What final consequences result from our researches into the range of application of bone cement in the operative treatment not only of bone metastases but also of primary malignant bone tumors? The different brands of bone cement currently used still chiefly have the function of a filling and supporting another substance due to their good tissue tolerance in the hardened state.[5,9] This is the case especially with neoplastic bone lesions in which pathologic fractures are a threat (Fig. 6-15A) or have occurred (Fig. 6-15B).

The polymerization effect of bone cement and the additional intramedullary damage of blood supply and oxygen reduction sometimes cause only a short and not deeply penetrating tumor-damaging effect. However, no effects are capable of stopping the neoplastic growth over the long term.

Therefore bone cement is considered in primary malignant bone tumors (according to their histology and location) only for certain exceptional situations to bridge defects of the resection zone. It would be indicated if other radical, and especially amputative, procedures are rejected or as a temporary procedure until the exact histologic classification is available. The danger of recurrence, however, is great when radical surgery is not performed, chiefly for tumors near the knee-joint, when joint-saving treatment is intended.

For so-called low-grade malignant tumors however, a temporary cement implantation is considered as a relative indication and an alternative to resection. The same applies to solitary osteolytic metastases of slow-growing organ primaries with a tendency to metastasize late, such as hypernephroma.

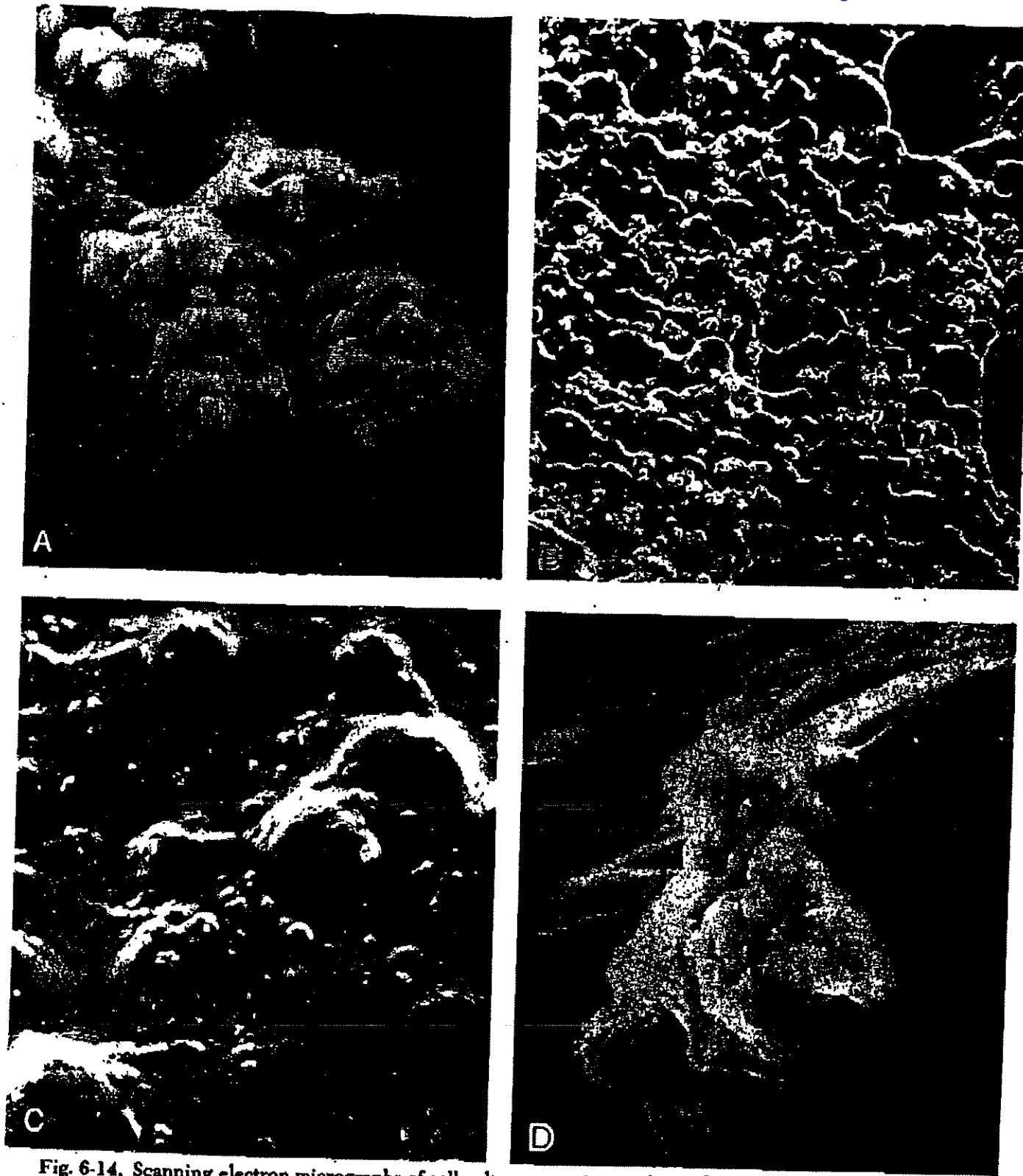

Fig. 6-14. Scanning electron micrographs of cell cultures growing on the surface of Palacos bone cement. (A) Groups of human embryonic fibroblasts from umbilical cord. The cells are closely aggregated and have grown firmly onto the cement surface. (B) Human fibroblasts from subcutis. The cells are growing in regularly distributed, small groups on the paving-stone-like cement surface. (C) Groups of HeLa tumor cells. Unaffected cells can be seen in close contact with the cement surface. (D) HeLa cell aggregate at higher magnification, showing numerous bulges on the cement surface. (Original magnifications: A ×2,400; B ×160; C ×160; D ×4,000.)

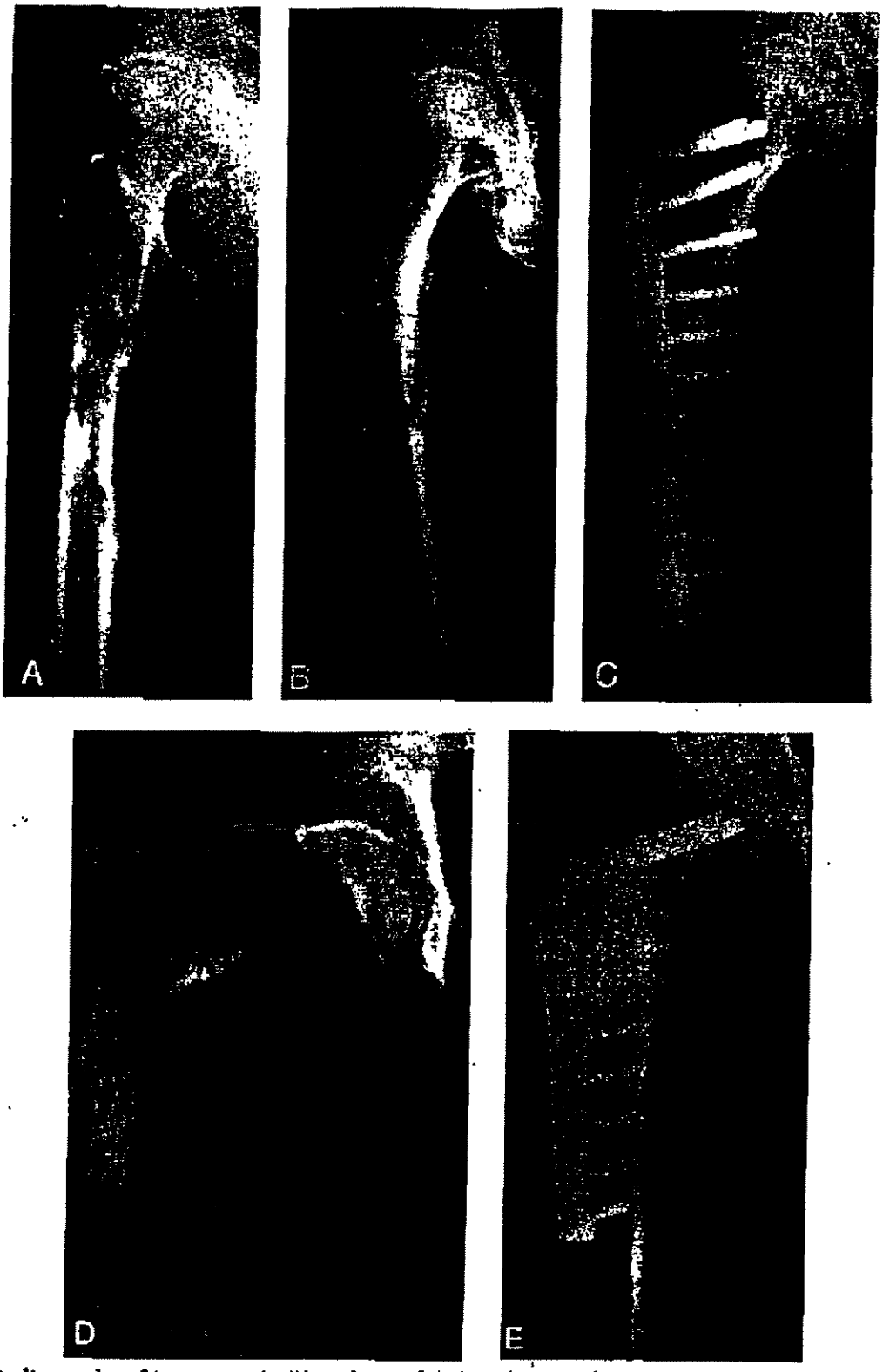

Fig. 6-15. Radiographs of imminent (A,B) and actual (D) pathologic fractures, and of the stabilization of both kinds (C,E) by combined osteosynthesis with an angle plate.

Semimalignant bone tumors, in which it is difficult to estimate the malignancy, have special indications for temporary cement implantation. These include giant-cell tumors in which the malignancy increases with multiple recurrences. Here the procedure with a so-called "temporary cement plug" has proven satisfactory.[10,11] This procedure has the following advantages compared to direct grafting with spongiosa: guaranty of the histologic diagnosis since there is no time pressure for further operative measures; early stability for function and physical strain, especially with the lower extremities; exact radiographic controls to allow early recognition of recurrence at the bone–cement border; finally, the possibility of a repeated histologic examination ("second look biopsy") at the postponed cement exchange.[12]

We should like to draw attention to the possibility of adding cytostatic drugs to the bone cement. This has been successfully practiced for a long time with certain antibiotics. Such preparations likewise might be locally effective, but need not be metabolized. After polymerization of the bone cement mixture, the thermostable cytostatic drug is released continuously and chemically unchanged for a long time into the internal environment.

Promising studies were carried out with test substances added to the bone cement Palacos, which was placed in serum at 37°C (personal communication, H. Wahlig and E. Dingeldein). Of all the tested cytostatic drugs, methotrexate proved most suitable for incorporation in bone cement. It was released continuously but at a variable rate, depending on the behavior of the cement surface available for diffusion. The rate of elution of the cytostatic out of the cement could be changed by using different filling substances. Depending on further studies, the problems described with the use of bone cement in the treatment of bone sarcomas and perhaps malignant soft tissue tumors as well as metastases should be discussed from different points of view. The main problem until then will be to find a model of malignant bone tumors (e.g., in dogs) in which it will be possible to study such bone cements more easily than in the rabbit model described here.

REFERENCES

1. Strube, H-D, Ritter G: Die Verbundosteosynthese. Unfallchirurgie 88:53, 1985
2. Komitowski D: Experimental bone tumors as models of human bone tumors. Pathol Res Pract 166:72, 1979
3. Moritani M, Kajino G: Intramedullary implantation of 7,12-dimethylbenz(*a*)-anthracene induced fibrosarcoma. Jpn J Orthop Traumatol 17:58, 1974
4. Müller WEG, Seibert, G: Effect of cordycepin on nucleic acid metabolism in L 5178 y cell and on acid synthesising enzyme systems. Cancer Res 37:3824, 1977
5. Strube H-D: Kunststoffzement in der Behandlung maligner Knochentumoren. Fortschr Med 20:946, 1982
6. Overgaard J: Effect of hyperthermia on malignant cells in vivo. Cancer 39:2637, 1977
7. Treon JF, Sigmon H, Wright H: The toxicity of methyl- and ethyl-acrylate. J Ind Hygiene 31:317, 1949
8. Hulliger L: Untersuchungen über die Wirkung von Kunstharzen (Palacos und Ostamer) in Gewebekulturen. Arch Orthop Unfallchir 54:581, 1962
9. Salzer M, Zwerina H: Operative Möglichkeiten bei Skelett-metastasen. Wien Med Wochenschr 27:422, 1972
10. Carlson D, Adams R: The use of methacrylate in repair of neoplastic lesions in bone. Radiology 112:43, 1974
11. Willert H-G, Enderle A: Temporäre Zementplombe bei Knochentumoren fraglicher Dignität. Z Orthop 117:224, 1979

Morphology of the Tissue Surrounding a Temporary Bone Cement Plug

A. Enderle, H.-G. Willert, and L. Zichner

In 1972 we introduced the temporary bone cement plug as a treatment to preserve the function and stability of a limb after curetting benign bone tumors that have a high recurrence rate, or tumors with a doubtful biologic behavior, and tumorlike lesions.[1–4] Unlike with cemented artificial joints, this cement plug is not subject to the immediate influence of mechanical stress. Even if the plug is situated directly on the cartilage of the adjacent joint, the load transmission through the bone–cement interface is relatively low. Because of this different mechanical conditioning factor, it is interesting to compare the tissue reaction to cemented prostheses and temporary cement plugs. Furthermore, it is worthwhile knowing whether the cement has a devitalizing effect on the surrounding tissue.

MATERIAL AND METHODS

If no recurrence occurred after an adequate length of clinical and radiographic observation, we removed the cement plug and refilled the cavity with bone grafts. The plug was removed by chiseling out the cement and the wall of the cavity was cleaned by curettage and lavage. We gained curetted material from 17 cases containing the implant bed of the cement for histologic investigation. The curetted material was composed of soft tissue membranes, including small particles of bone and acrylic cement. The histologic examination is difficult because the orientation of the single tissue particle is not always easy. We examined only such particles in which the tissue was in contact with the cement. Though the cement is dissolved by the histologic preparation, the point of contact is discernible by the partly preserved contrast medium originally mixed with the cement.

The decalcified and paraffin-embedded material was stained with hematoxylin and eosin and van Gieson's stain. In some cases we also had undecalcified methyl-methacrylate-embedded sections with Goldner staining.

To compare the histologic features of the implantation bed in these cases with those of total hip arthroplasties, 18 previous published autopsy and biopsy cases were used.[5] In all cases with the temporary cement plug a radiologic follow-up examination was performed.

RESULTS

The mean implantation time for the 17 temporary cement plugs amounted to 11.3 months (Fig. 6-16). In nearly all cases, except those with a very short implantation time, a narrow translucent zone was seen radiologically between the acrylic cement and bone. The marginal bone adjacent to this radiolucent line was sclerotic (Fig. 6-17). Both translucency and sclerosis were increased in width in most of the cases. In three cases the implant was stabilized by internal fixation with an AO plate. Based on the retention time of the cement plug, our cases can be classified into three groups.

Group 1

These three cases had a very short implantation time. The plug had to be removed abruptly because histologic study revealed a malignant process, which required a change in the subsequent proce-

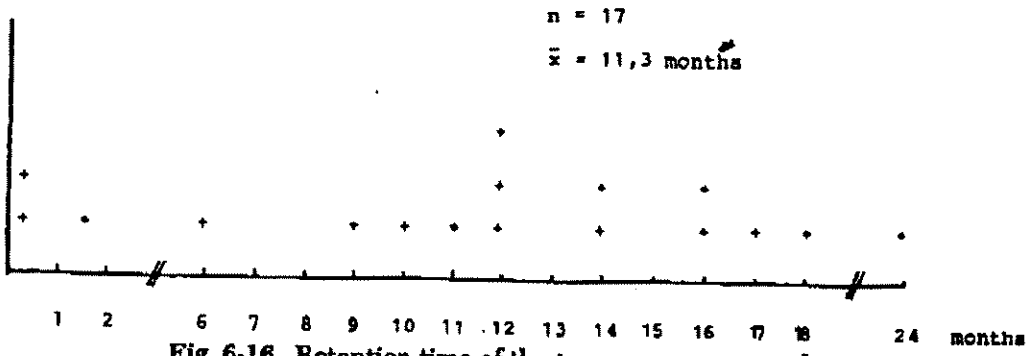

Fig. 6-16. Retention time of the temporary cement plugs.

dure. In one of these cases histologic examination showed tumorous chondrosarcoma tissue with viable tumor cells at the immediate border of the cement. In the other two cases, with the diagnosis of osteosarcoma and chondrosarcoma, no tumorous tissue could be found but the bone and marrow adjacent to the cement was necrotic in several places.

Group 2

In these two cases the cement plug was in place for a much longer interval. Reoperation to remove the plug was necessary because the radiologic examination indicated a recurrence. Recurrence was confirmed by histologic study showing viable giant-cell tumor tissue.

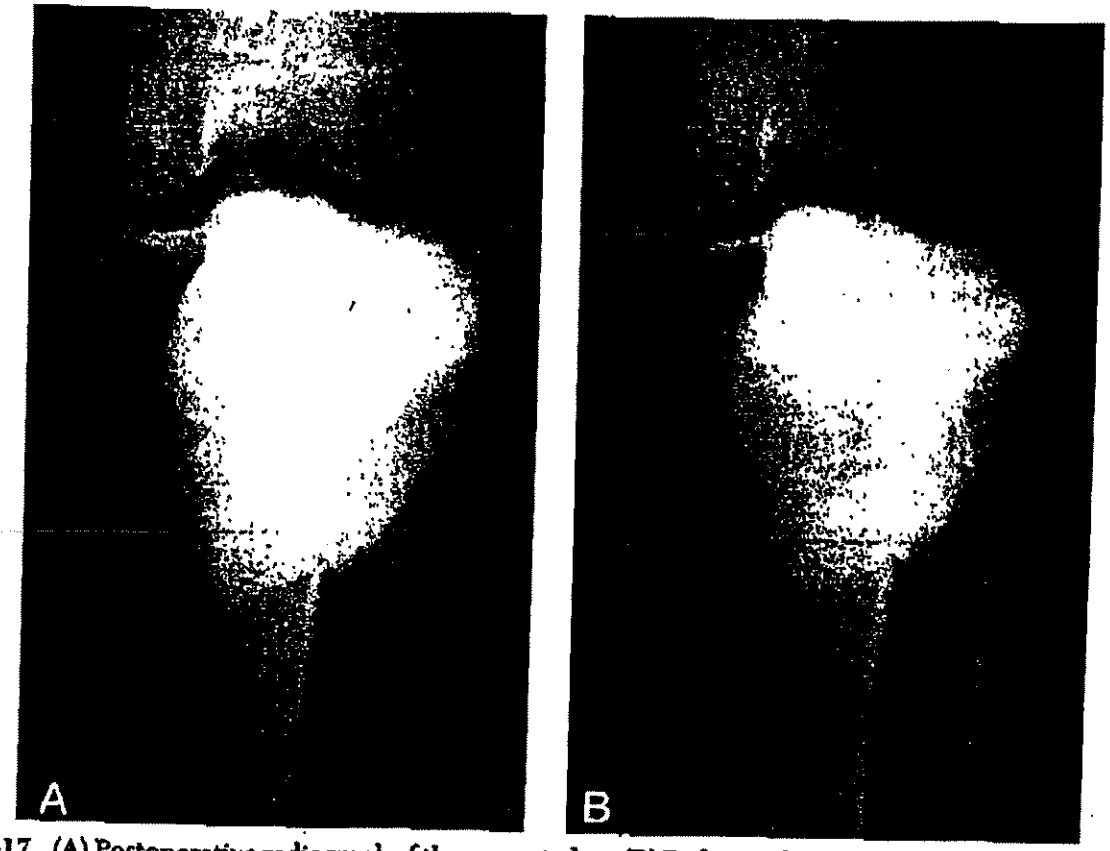

Fig. 6-17. (A) Postoperative radiograph of the cement plug. (B) Radiograph 9 months after operation shows development of a progressive translucent zone and sclerosis around the plug.

Group 3

In the 12 remaining cases, in which the plug was in place longest, histologic examination of the curetted material from the bone–cement interface showed no tumorous tissue. A fibrous membrane, mostly without any cellular lining, was visible. Sometimes a synovial-like layer of lining cells at the side of the cement surface was evident. These cells formed a layer one or two cells thick without a basement membrane (Fig. 6-18). A fibrinoid surface coating existed focally. Occasionally a few multinucleate giant cells were mixed with the lining cells. Contiguous to this cell layer a loose fibrovascular tissue was visible, infiltrated with a few histiocytes and mononuclear round cells. Sometimes the surface lining formed papillary folds. Cement pearls were frequently embedded in the membrane, surrounded by only a few foreign body giant cells (Fig. 6-19). In other areas of the membrane, metaplasia of cartilage was evident at the implant side, but woven bone formation was the exception (Fig. 6-20). New bone formation, however, was the rule at the bone side of the membrane corresponding to the sclerosis on the x-ray study.

In some areas the bone adjacent to the cement was necrotic, with lacunae empty of osteocytes and acellular or fibrous marrow.

Direct contact between bone and cement could almost never be seen. Usually they were separated by a connective tissue membrane, even though the membrane was sometimes very thin. In the rare case of an immediate contact the bone was transformed into cartilage at this point. In the few cases in which we had undecalcified sections, sometimes the bone near the cement showed osteoid seams without any osteoblastic activity.



Fig. 6-19. Cement pearls with scanty multinucleate giant cells (original magnification ×200).

DISCUSSION

According to the histomorphologic classification of our three cases with the short implantation time of the cement plug, we may assume that the acrylic



Fig. 6-18. Synovial-like membrane at the surface of the acrylic cement with lymphocytic and plasmacellular infiltrates (original magnification ×200).



Fig. 6-20. Metaplasia of cartilage at the contact area with the acrylic cement (original magnification ×80).

Table 6-14. Types of Tissue at the Bone–Cement Interface in 17 Cases

Type of Tissue	*No. Cases*
Connective tissue membrane	15
Synovial-like lining cells	6
Cement pearls in the membrane or bone marrow	14
Foreign body giant cells around cement pearls	6
Foreign body giant cells at the surface of the membrane	2
Histiocytes in the membrane	2
Fibrocartilage	6
Bone necrosis	11

cement can cause necrosis in its immediate environment. This has validity at least for normal bone and marrow. Whether there is a natural resistance to the cement in chondrosarcomas we cannot answer definitively based on our own investigations.

In the cases with an implantation time of 6 months and more, comparison of the histologic findings at the bone–cement interface of the temporary cement plugs with those of cemented prostheses showed the same pattern, which corresponds to the time-dependent phases of reparation and stabilization, according to Willert and Puls[6] (Table 6-14). Quantitatively, however, the composition of the histologic pattern was different. In the cement plug the connective tissue membrane is thicker, but the cement pearls, the giant cells around the pearls and at the surface of the membrane, and the histiocytes are scarce compared with the artificial hip joints (Table 6-15). This means that the tissue reaction in the temporary cement plug is less than that in cemented prostheses. We did not expect this feature but it would justify the procedure used by some other authors, who do not remove the cement.

The features of the synovial-like membrane have also been observed at the bone–cement interface in loose total hip replacements by Goldring et al.[7] In our material there was no clinical evidence that the cement plug could have loosened; it was always hard to get the plug out of the bone. Moreover, there was no correlation between the radiologic appearance of the width of the translucent zone (which is said to be a sign of loosening[8]) and the existence of a synovial-like membrane. Also no relationship could be found between the fixed plugs with internal fixation or the direct subchondral position of the plug and the width of the radiolucent and sclerotic zone. This means that the synovial-like membrane at the bone–cement interface in temporary cement plugs is not related to gross loosening, but probably to a micromovement. Tiny motions at the bone–cement interface must be assumed because of the occasional cartilage formation at the contact area between bone and cement. The osteoid seams without osteoblastic activity in the neighborhood of the cement are interesting findings. This has been already observed by Willert and Puls[6] in total hip prostheses and was interpreted recently by Lintner et al.[9] and Delling et al.[10] as toxic disturbance in mineralization caused by the free acrylic monomer. This could be a legitimate reason for removing the plug. However, Ulmansky et al.[11] observed a primary mineralization in the interface between bone and polymethyl methacrylate implants in the rat and therefore concluded that there is a favorable relationship between bone and the implant material.

Table 6-15. Findings at Bone–Cement Interface

Finding	*Bone–Cement Interface*	
	Cemented Prostheses	*Temporary Cement Plug*
Width of membrane	++	+++
Incidence of		
Cement pearls	+++	++
Foreign body giant cells	+++	+
Synovial-like lining cells	++	++
Bone contact at the cement	++	(+)
Metaplasia of cartilage	++	++

REFERENCES

1. Willert H-G, Enderle A, Fergenbauer G: Zur Diagnostik und Therapie von Knochentumoren aus orthopädischer Sicht. Arch Orthop Unfallchir 90:41, 1977
2. Willert H-G, Enderle A: Temporäre Zementplombe bei Knochentumoren fraglicher Dignität. Acta Facult Med Brunensis 64:263, 1979
3. Willert H-G, Enderle A: Temporäre Zementplombe

bei Knochentumoren fraglicher Dignität. Z Orthop 117:224, 1979
4. Willert H-G, Enderle A: Temporary bone cement plug—an alternative treatment of large cystic tumorous bone lesions near the joint, p. 69. In Kotz R (ed): 2nd International Workshop on the Design and Application of Tumor Prostheses for Bone and Joint Reconstruction. Egermann, Vienna, 1983
5. Willert H-G, Ludwig J, Semlitsch M: Reaction of bone to methacrylate after hip arthroplasty. A long-term gross, light microscopic, and scanning electron microscopic study. J Bone Joint Surg 56A:1368, 1974
6. Willert H-G, Puls P: Die Reaktion des Knochens auf Knochenzement bei der Alloarthroplastik der Hüfte. Arch Orthop Unfallchir 72:33, 1972
7. Goldring SR, Schiller AL, Roelke M, et al: The synovial-like membrane at the bone-cement interface in loose total hip replacements and its proposed role in bone lysis. J Bone Joint Surg 65A:575, 1983
8. Gruen TA, McNeice GM, Amstutz HC: "Modes of failure" of cemented stem-type femoral components. Clin Orthop Res 141:17, 1979
9. Lintner F, Bösch P, Brand G: Histologische Untersuchungen über Umbauvorgänge an der Zement-Knochengrenze bei Endoprothesen nach 3- bis 10 jähriger Implantation. Pathol Res Pract 173:376, 1982
10. Delling G, Krumme H, Engelbrecht E, et al: Reaction of bone tissue after long-term implantation of total joint arthroplasty. A morphological study. p. 37. In Kotz R (ed): 2nd International Workshop on the Design and Application of Tumor Prostheses for Bone and Joint Reconstruction. Egermann, Vienna, 1983
11. Ulmansky M, Bab I, Kaznelson D: Primary mineralization in the interface between bone and methylmethacrylate implants in rat mandibles. Arch Orthop Traum Surg 101:171, 1983

Discussion

Dr. Willert: To stimulate the discussion, I would like to ask Dr. Strube, whether he has any personal experience with the mixture of cytostatic drugs and bone cement?

Dr. Strube: No, not yet.

Dr. Willert: I think we do have a gentleman here who did some work on this. Dr. Langendorff, would you like to comment on this please?

Dr. Langendorff: Thank you very much, Mr. Chairman, for giving me the opportunity to make some remarks on the methotrexate bone cement.

The problem we face is that under certain conditions, complete removal of the local tumor cannot be achieved or is not even indicated, for instance, in palliative stabilizing of bone metastases. When I started to develop methotrexate bone cement, my philosophy was to achieve higher local tissue concentrations of methotrexate to avoid a local recurrence on the one hand and systemic effects on the other organs on the other hand.

The in vitro kinetic studies mentioned by Dr. Strube are out of date now and do not present our current data. By adding certain amounts of acids, methotrexate was delivered from the bone cement in a much higher concentration for over 20 days, and the biomechanical properties of the bone cement did not change.

To prove that this bone cement worked biologically, we transplanted an irradiation-induced osteosarcoma and a mammary carcinoma in mice and put preformed bone cement plugs in the middle of the the tumor. The rate of increase of the tumor was lowered considerably by the methotrexate-containing cement implants, especially in mammary carcinoma, compared with the normal bone cement.

Histologically, normal bone cement had no effect at all on the osteogenic sarcoma, whereas methotrexate bone cement caused considerable necrosis around the plug. More distantly we find the distinct alteration of the tumor cells and only in the periphery viable tumor.

Tissue concentrations in liver, kidney, muscle and plasma, 10 and 18 days after administration, were low so that no systemic effects will be expected. Although a high concentration of methotrexate was found in cortical and cancellous bone, there was little or no effect on the osteogenetic activity of the healthy bone.

These findings encourage us to propose methotrexate bone cement either when radical surgery is not indicated or to give additional safety in prosthesic replacement of malignant bone tumors.

Dr. Willert: I think this opens a very interesting view of the future possibilities for bone cement use.

Dr. Lane: If there is no suggestion from your data that there is micromotion of the cement vis-a-vis the bone, is the cement providing any structural support to the bone? Is there any biomechanical information about the effect of a cement plug in the bone?

Dr. Ederle: We did not perform biomechanical experiments, but the metaplastic formation of cartilage in the neighborhood of the cement is a sign from which you can conclude that there must have been micromotion.

Dr. Lane: We have tried, in an imperfect model in the diaphysis, to put in the cement and see if it has altered the effect. We have difficulty in discerning any difference between an unfilled hole and a hole filled with cement.

Now, of course, it was in the diaphysis, not in the metaphyseal bone. You're usually doing this in the metaphysis. Maybe Dr. Chao or some of the other people have more experience with this.

But part of the beauty of the cement was that it could give you the protection and you would not worry about collapse of the bone. Now I'm not quite sure how much of that bone is being protected.

Dr. Enneking: There is a supplement of the Acta Orthopedica Scandinavica in 1976 (a thesis from Dr. Feith) that documents very clearly in cortical bone the extent of necrosis under various circumstances of polymerization and the amount that he attributed to thermal necrosis. The physical dimensions are pretty clearly specified in that cortical bone.

Doctor Yagi did an experiment with cancellous bone of the metaphysis, again with very clear physical dimensions, where the necrosis may vary anywhere from 5 to 12 mm beyond the end of defect measured by tetracycline marking.

I don't think there's a whole lot of doubt that under certain circumstances you could produce necrosis. Whether it's due to thermal problems or toxic problems that have been demonstrated in tissue cultures, I think is fairly debatable. But then when you start adding things like methotrexate to it and showing histologic studies of necrosis, you have, I think, very little idea whether this is coming from the hole you made with the drill, the heat, the polymerization from the cement, the toxicity of the monomer on the cells, or slow leaching out of methotrexate.

I think it's going to take some very sophisticated and complex experiments to really resolve those issues, each one of which has some clinical significance in terms of what we are doing.

Dr. Wright: Could I ask the second speaker: do you think the translucent zone has anything to do with the shrinkage of the cement? Because you're using rather large masses and the overall shrinkage of this surely would be significant.

Dr. Enderle: I think that translucent zone is represented by the connective tissue membrane. And we know that the cement is shrinking a little bit after polymerization and the gap you get will be the space where the fibrous tissue is growing in.

Dr. Willert: But, the bone cement shrinks just after implantation and the translucent zone will appear only within weeks or months after implantation, so this must have something to do with bone remodeling and new bone formation surrounding the cement.

What I personally found very striking is that we see the same sclerotic lines with a little translucent zone between implant and bone in uncemented prostheses. These are without any doubt due to bone new formation at a certain distance from the implant.

Curettage and Acrylic Cementation in Surgical Treatment of Giant-Cell Bone Tumors

Björn M. Persson, Anders Rydholm, Örjan Berlin, and Björn Gunterberg

Giant-cell tumors of bone are locally aggressive and may exceptionally metastasize to lungs despite a benign histologic picture. They are exceptional also in that intralesional treatment by curettage is possible. Filling the defect with bone chips, however, carries a risk of recurrence of about 40% in most series.

Our first cemented lesion in 1972 was such a recurrent tumor in a patient who refused amputation. Since then 20 giant-cell tumors adjacent to joints have been similarly curetted and reconstructed by filling with acrylic bone cement. All have been observed for more than 2 years (average 7 years, range 2 – 13 years). The largest diameter of an osteolytic lesion preoperatively was between 5 and 13 cm (average 7 cm). Postoperatively, the largest diameter was between 5 and 14 cm (average 8 cm). Histologic reexamination showed a benign aggressive (Enneking grade IIIB) cell pattern. The Enneking stage was T1 in 7 cases and T2 in 13. The method allowed immediate motion and weight-bearing in all cases, and the Enneking rating of function shows Excellent motion in all but 2 patients, Excellent for pain in all but 4, Excellent for stability in all but 1, Excellent for strength in 9, and Good in 11. Psychological acceptance was Excellent in 13, Good in 4, and Fair in 1. Complications were one aggressive local recurrence resulting in above-the-knee amputation, two minor local recurrences resulting in additional cementation, two negative second-look biopsies for pain, two transient postoperative nerve palsies, and one patellar ligament rupture that required surgical repair.

It is thus concluded that thorough curettage with acrylic bone cement is the best method of treatment for giant-cell tumors and for pathologic fracture except when soft tissue involvement is advanced or peripheral function of the extremity is already impaired. Simultaneous with our collection of 20 cases treated by cement, one needed proximal femoral resection with megaprosthesis replacement, one required knee resection with artificial fusion, and one required above-the-knee amputation. Only 2 of the 20 cases showed osteoarthrosis on weight bearing films although a 1 or 2 mm radiolucent zone was seen around the cementation in all cases. The heat does not seem to destroy joint cartilage significantly. It is assumed, based on these results, that filling with bone or using cryosurgical technique does not give as good a result and that radical resection does not give as good function as cementation.

By now 19 of 20 cemented cases have not needed any other treatment and joint motion has not been sacrificed in more than the one that underwent amputation and the one with an artificial knee fusion.

Treatment of Giant-Cell Tumors by Curettage and Acrylic Cementation

A. H. M. Taminiau, and H. W. Wouters

The results of curettage and acrylic cementation for giant-cell tumors of bone are reviewed here based on the experience of the Dutch Committee on Bone Tumors.

From 1969 to 1984, 17 patients were treated this way; 6 were women and 11 were men. The mean age was 27.5 years (range, 12–39). Thirteen giant-cell tumors were located in the knee region (distal femur nine, proximal tibia four). The other localizations were radius two, ilium one, and proximal femur one.

In 12 patients the primary treatment consisted of curettage and cementation. In five cases, cementation was performed after previous curettage and bone grafting for recurrences three and local infection (two cases).

The cementation procedure resulted in only four recurrences: one after inadequate filling of the cavity with cement; two cases with previous surgery, (bone grafting) and infection, before cementation; and a 12-year-old boy had a recurrence in the epiphysis of the tibia by extension through the epiphysial plate.

Three of these four patients were operated on again. After removal of the cement and curettage, additional cementation was performed. All three are free of local recurrence. The young boy underwent amputation because local treatment was refused.

Of all 17 cases to date with a follow-up of 2–17 years (mean, 5.2) 16 patients are disease-free including the one with a resection–arthrodesis for a distal radius tumor and temporary filling with cement, and one amputation.

In eight patients the cement was removed and a bone graft performed. In one of these (the proximal femur lesion) severe arthrosis of the hip was treated by cup arthroplasty.

The functional results after the treatment with cementation appear to be Good. According to the Enneking evaluation form the results are Excellent in 11 and Good in 6.

In conclusion, the low recurrence rate and good functional results in the treatment of giant-cell tumors of bone by curettage and cementation make it our treatment of choice.

Discussion

Dr. Willert: I think we should discuss these three presentations now.

Dr. Lane: Since there are several patients presented by the group who did show the beginnings of osteoarthritis and since most of these people are relatively young, would it be advisable to bone graft all these patients in anticipation that, as they get older, joint replacement may be in mind? Certainly it is easier to put a prosthesis into bone than possibly into a large bed of cement. I would like to hear the comments of the panel.

Dr. Persson: I don't think so. I think that the risk of osteoarthritis still seems to be low.

Dr. Taminiau: We propose to all the patients to have the cement removed, but a few of them resist and after

REFERENCES

1. Baddeley S, Cullen JC: The use of methyl methacrylate in the treatment of giant cell tumors of the proximal tibia. Aust NZ Surg 49:120, 1979
2. Persson BM, Wouters HW: Curettage and acrylic cementation in surgery of giant cell tumors of bone. Clin Orthop 120:125, 1976
3. Ewald FC, Poss R, Pugh J et al: Hip cartilage supported by methacrylate in canine arthroplasty. Clin Orthop 171:273, 1982
4. Manley PA, McKeown DB, Schatzker J et al: Replacement of epiphyseal bone with methyl methacrylate: its effect on articular cartilage. Arch Orthop Trauma Surg 100:3, 1982
5. Radin EL, Orr RB, Kelman JI et al: Effect of prolonged walking on concrete on the knees of sheep. J Biomechanics 157:487, 1982
6. Schatzker J, Horne JG, Sumner-Smith G et al: Methyl methacrylate cement: its curing temperature and effect on articular cartilage. Can J Surg 18:172, 1975
7. Sorenson WG, Bloom JD, Kelly PJ: The effects of intramedullary methyl methacrylate and reaming on the circulation of the tibia after osteotomy and plate fixation in dogs. J Bone Joint Surg 61A:417, 1979
8. Yablon IG: The effect of methyl methacrylate on fracture healing. Clin Orthop 114:358, 1976
9. 'd'Hollander A, Burney F, Monteny E et al: Extraosseous variations of temperature during polymerization of acrylic cement in hip arthroplasties. Acta Orthop Scand 47:186, 1976
10. Linder L: Tissue reaction to methyl methacrylate monomer. Acta Orthop.Scand 47:3, 1976
11. Linder L: Reaction of bone to the acute chemical trauma of bone cement. J Bone Joint Surg 59A:82, 1977
12. Larsson SE, Loretzon R, Boquist L: Giant cell tumor of bone: a demographic, clinical and histopathological study of all cases recorded in the Swedish Cancer Registry for the years 1958–1968. J Bone Joint Surg 57A:167, 1975
13. Reckling FW, Dillon WL: The bone-cement interface temperature during total hip replacement. J Bone Joint Surg 59A:80, 1977
14. Huiskes R: Some fundamental aspects of human joint replacement: analysis of stresses and heat-conduction in bone-prosthesis structures. Acta Scand Orthop Suppl 185:1, 1980

Effect of Cryosurgery and Polymethyl Methacrylate on a Tumor Cavity: Evaluation of Bone Necrosis and Bone Graft Incorporation in a Dog Model

M. M. Malawer, M. Marks, D. McChesney, M. Piasio, S. F. Gunther, and B. M. Shmookler

NOTICE THIS MATERIAL MAY BE PROTECTED BY COPYRIGHT LAW (TITLE 17, U.S. CODE)

The aim of the treatment of bony tumors by curettage and liquid nitrogen (cryosurgery) is to decrease the rate of local recurrence by inducing peripheral necrosis. Marcove first reported his clinical experience with this technique in 1969, and he subsequently has used it to treat several hundred benign and malignant bone tumors with good local control.[1–3] This technique has not gained widespread acceptance, in part due to reported complications, which include secondary fracture and delayed healing. In addition, the basic effect of liquid nitrogen on normal bone and/or the

Case 1:04-cv-00204-JJF Document 160-5 Filed 04/13/2005 Page 19 of 30

normal bony reparative processes is poorly understood. There has been only a rare report of the effect of liquid nitrogen (LN) on bone and none regarding its effect on bone graft incorporation.[4] Recently, polymethyl methacrylate (PMMA) has been used to pack curetted cavities of giant-cell tumors (GCTs); presumably the heat of polymerization induces peripheral necrosis and thus decreases the incidence of local recurrence.[5]

Gage[4] described histologic and radiographic findings of extensive bony necroses in 18 dog femora treated with LN. He used a closed system of latex tubes with LN circulating within and surrounding the diaphysis of the femur. Though it provided needed information, Gage's animal model is markedly different from the clinical situation. First, most tumors treated by cryosurgery are metaphyseal and treatment consists of curettage with a large resultant cavity (e.g., a giant-cell tumor). Second, cryosurgery as described by Marcove uses the "direct-pour" method: liquid nitrogen is poured directly into the cavity (open) rather than through tubes (closed). In Marcove's method the maximum effect of the liquid nitrogen is exerted on the wall of the cavity and adjacent metaphyseal bone, while with Gage's technique the maximum effect is on the cortex. Finally, Gage's study did not use PMMA.

We developed a dog model that simulated a tumor cavity of the distal femur. The purpose of our study was to determine the efficacy of LN and PMMA as surgical adjuvants to curettage. This study also was designed to answer the following specific questions:

1. Does LN or PMMA cause bony necrosis?
2. What is the effect of LN on bone graft incorporation?
3. What is the effect of LN on normal bone formation (osteogenesis)?

MATERIALS AND METHODS

Ten skeletally mature mongrel dogs weighing between 13 and 21.5 kg were used. A 12.5 mm corticocancellous core was removed from the lateral condyle of each femur using a Zimmer stem retractor; the medial cortex was left intact. This simulated a tumor cavity of the femur. The cores (bone graft) were either replaced or discarded according to the protocol. The dogs were treated by the following protocol.

Group I (control): No cryosurgery, no graft vs. no cryosurgery, graft; three dogs
Group II (cryosurgery): Cryosurgery vs. cryosurgery plus graft; three dogs
Group III (PMMA): PMMA vs. cryosurgery plus PMMA; four dogs

Technique of Cryosurgery

The direct-pour technique using a funnel and Gelfoam insulation was performed as described by Marcove. Wide skin flaps were used for exposure and to avoid skin necrosis. A tourniquet was used to decrease the heat-sink effect. A thermocouple was placed approximately 5 mm from the cavity to monitor the freeze. All dogs were treated by a double freeze–thaw cycle (rapid freeze and a spontaneous slow thaw) to maximize necrosis. The duration of the freeze and thaw was 5 minutes each. Monitored temperatures ranged from −20 to −100°C. Cryoprotective agents were not used, and no special protection of the articular cartilage was used. The wound was intermittently irrigated with a warm saline solution; joint irrigation was not performed. All animals received intravenous Keflin (cephalothin sodium) for 4 days after surgery.

The animals were sacrificed at 1, 3, and 7–8 weeks. All animals were given 1 g tetracycline daily for 3 days prior to sacrifice. The entire femur was removed and cut longitudinally in sagittal sections. Gross photographs were taken under natural light and with a Wood's lamp to demonstrate tetracycline fluorescence. Whole-mount histologic sections (stained with hematoxylin and eosin) of the distal femur were prepared. Radiographs were taken immediately after surgery and prior to sacrifice.

Analysis

Twenty femora were available for study. The gross photographs were compared to the fluorescent studies and correlated with the whole mounts

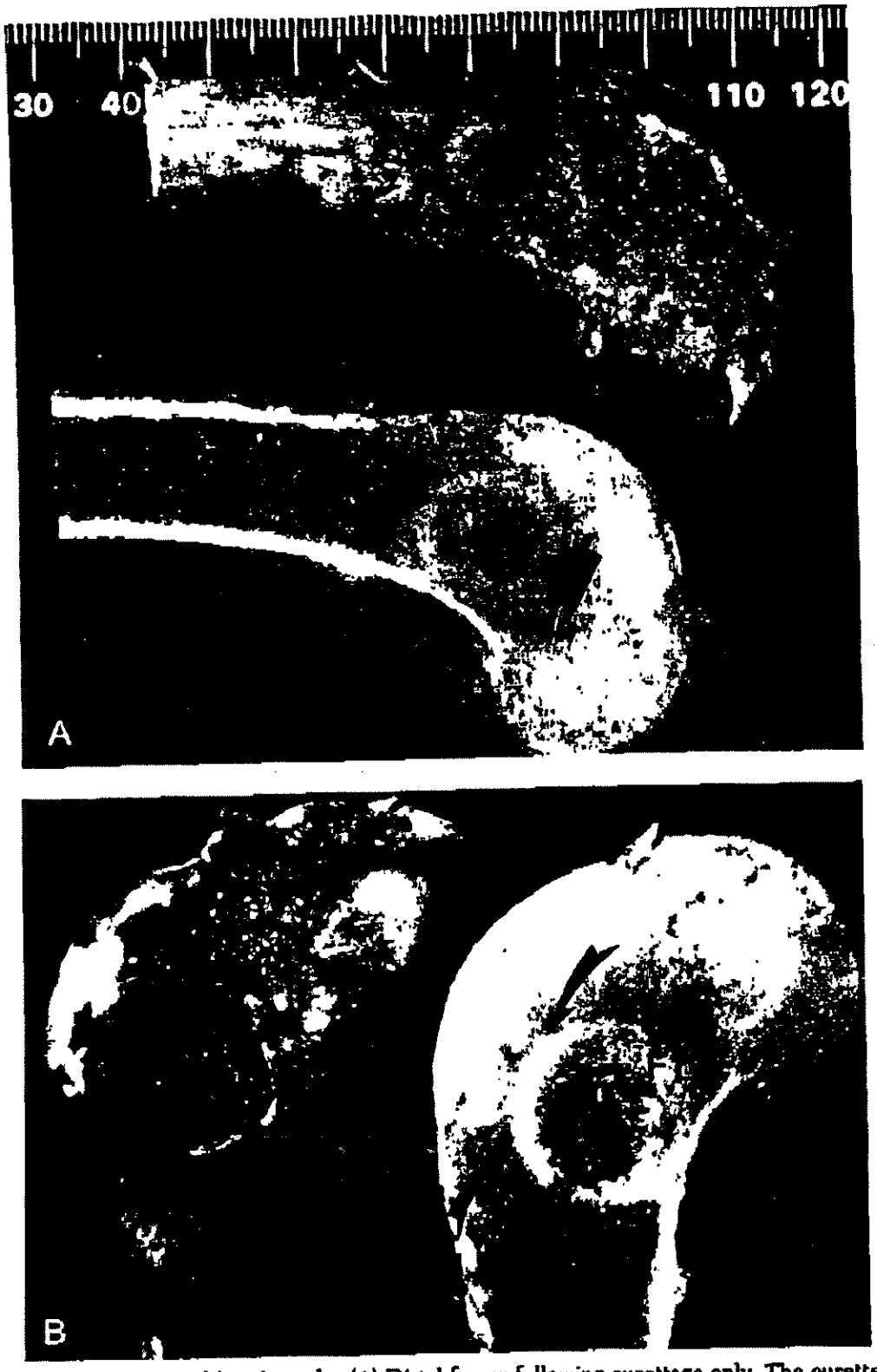

Fig. 6-26. Group I (controls) at 3 weeks. (A) Distal femur following curettage only. The curetted cavity (solid arrows) has filled with early callus. (B) Fluorescence (FL) with tetracycline outlines (curved arrows) the curetted cavity. Note that the fluorescence extends to the edge of the cavity. There was no evidence of peripheral necrosis on microscopic evaluation. *(Figure continues.)*

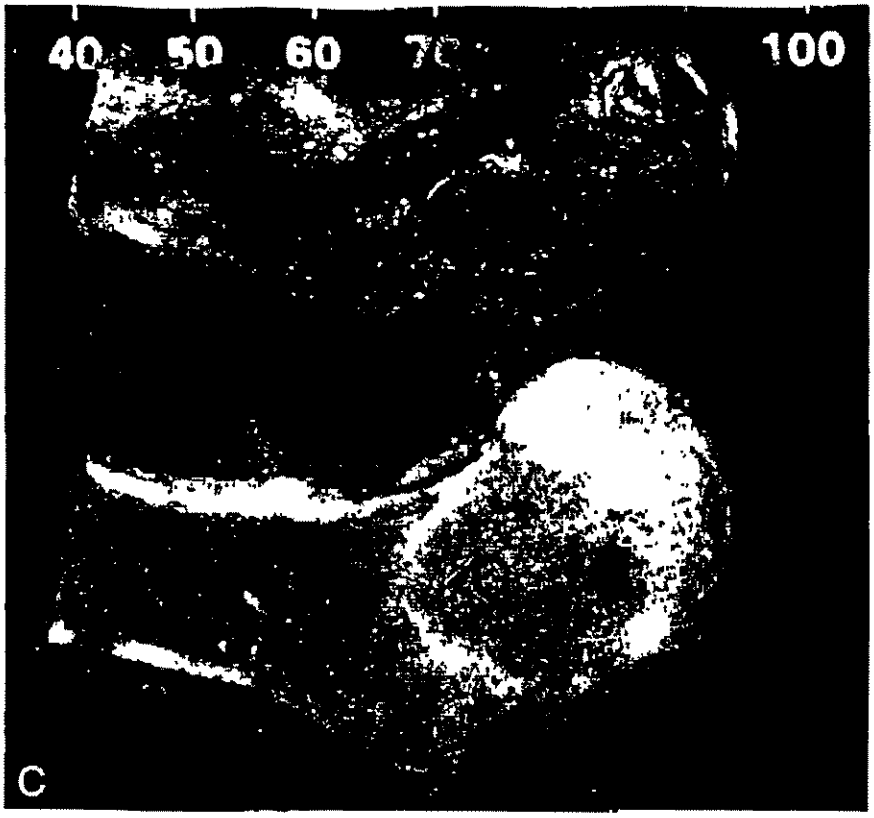



Fig. 6-26 *(Continued)*. (C) The distal femur following curettage and bone graft (G). Grossly the graft is incorporating with no evidence of loosening. (D) Fluorescence (FL) again is seen extending to the edge of the cavity. The reactive rim (arrows) corresponds to new bone formation. Note that there is some fluorescence of the graft.

to determine the amount of necrosis and viable bone, the status of the bone graft and articular cartilage, and the pattern of reossification and/or repair. The plain radiographs were evaluated for the presence or absence of a "cryonecrotic" rim and fracture and correlated with the whole-mount histologic section.

The histologic and fluorescent findings of the 20 femora are summarized here.

Group I (Control)

At 1 week the cavity filled with organizing hematoma; progressive healing was evident at 3 and 7 weeks (Fig. 6-26A,B). The bone graft was readily identifiable at 1 week and united at 3 and 7 weeks (Fig. 6-26C,D). There was viable bone at the rim of the cavity histologically and by fluorescence; no necrosis of the wall was seen. The cavity ossification and bone graft incorporation occurred by means of osteoblastic formation. There was no evidence of increased cartilage production, marrow necrosis, or vascular thrombosis.

Group II (Cryosurgery With or Without Graft)

At 1 and 3 weeks there was marked peripheral necrosis extending 7–12 mm beyond the cavity circumferentially (Fig. 6-27). This area showed no evidence of fluorescence. The cavity showed no evidence of hematoma organization at 1 week and minimal filling at 3 and 7 weeks (Fig. 6-27A,B). The graft was grossly loose and completely necrotic with no evidence of incorporation or new bone formation (Fig. 6-27C,D). The marrow showed a distinct pattern of necrosis, liquefaction with minimal inflammatory component, and no vascular ingrowth (Fig. 6-28); later stages showed progressive marrow fibrosis (Fig. 6-29A). There was evidence of vascular thrombosis with thickened walls. At 7–8 weeks there was some evidence of a reparative attempt at the periphery (Fig. 6-29B); this process consisted of increased marrow calcification and some cartilage production with an attempt at bone formation (enchondral or metaplastic) with apposition to the necrotic trabeculae. Within the previous necrotic zone there was fibrous proliferation and new bone formation from direct fibrous metaplasia in a mosaic pattern. There was minimal osteoblastic activity.

Group III (PMMA With or Without Cryosurgery)

The dogs treated with PMMA alone showed no evidence of bony necrosis based on histologic examination and fluorescence (Fig. 6-30). There was a 1–2 mm rim of fibroblastic reaction without giant cells at the bone–cement interface. With cryosurgery, the findings were similar to those of group II.

Articular Cartilage

Histologic evaluation showed that the articular cartilage was viable in all specimens, even if necrosis extended to the subchondral bone.

Radiographic Evaluation

A slight "cryonecrotic" rim was seen at 3 weeks despite histologic evidence of extensive necrosis. At 7–8 weeks a thickened sclerotic rim (Fig. 6-31) was present radiographically in all four dogs; this corresponded histologically to the areas of marrow calcification, cartilage and enchondral bone formation on necrotic trabeculae. This radiographic zone corresponded to the area of increased fluorescence. Two dogs sustained pathologic fractures in this area. The joint spaces appeared normal in all radiographs.

DISCUSSION

This study was designed to study the effect of LN, PMMA, and both together on bone by simulating a tumor cavity in a dog model. The distal femur was chosen since it is the most common site of many bony tumors treated with curettage and cryosurgery.

Liquid nitrogen had a profound effect on bone viability, new bone formation, and bone graft incorporation. In general, the cavities not treated by LN showed no necrosis and demonstrated early and progressive reossification. Those with bone

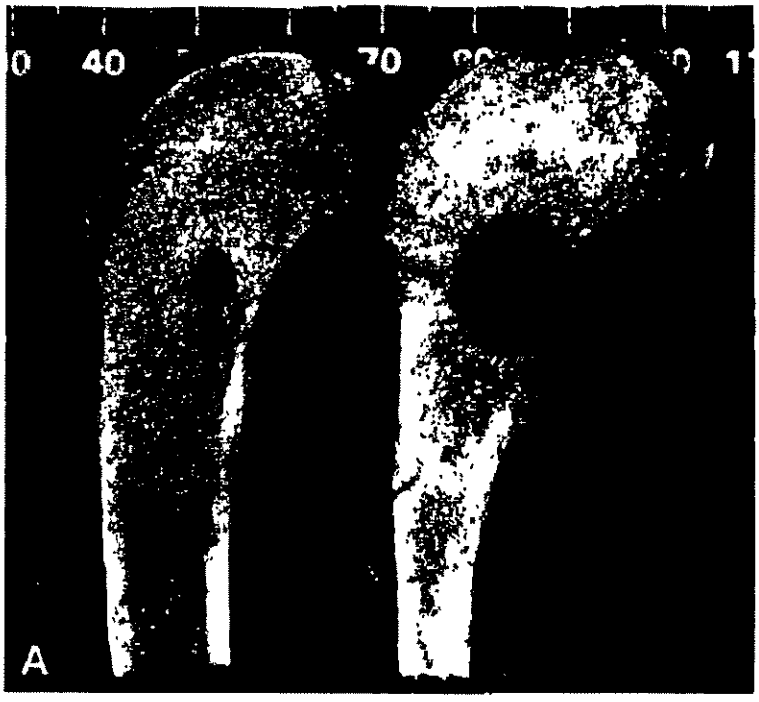



Fig. 6-27. Group II (cryosurgery) at 3 weeks. (A) Distal femur following curettage and double freeze–thaw cycle of cryosurgery. There is no evidence of callus formation. This cavity was filled with necrotic debris. (B) Tetracycline fluorescence demonstrates a circumferential rim (short solid arrows) with no fluorescence around the cavity, with an adjacent area (curved arrows) of fluorescence (FL). The zone of no fluorescence corresponds to the extent of bony necrosis (N), and the zone of fluorescence to attempted bony repair. *(Figure continues.)*



Fig. 6-27 *(Continued)*. (C) The distal femur following curettage and bone graft. The bone graft (C) appears grossly loose in contrast to the controls (see Fig. 6-26C). Microscopically, the graft showed no sign of incorporation. (D) Tetracycline fluorescence of the distal femur. Note the absence of fluorescence adjacent to the frozen cavity and no uptake by the graft. The peripheral rim (solid arrows) of fluorescence (FL) is seen, similarly to B. In general, necrosis extended 8–12 mm beyond the cavity following cryosurgery.

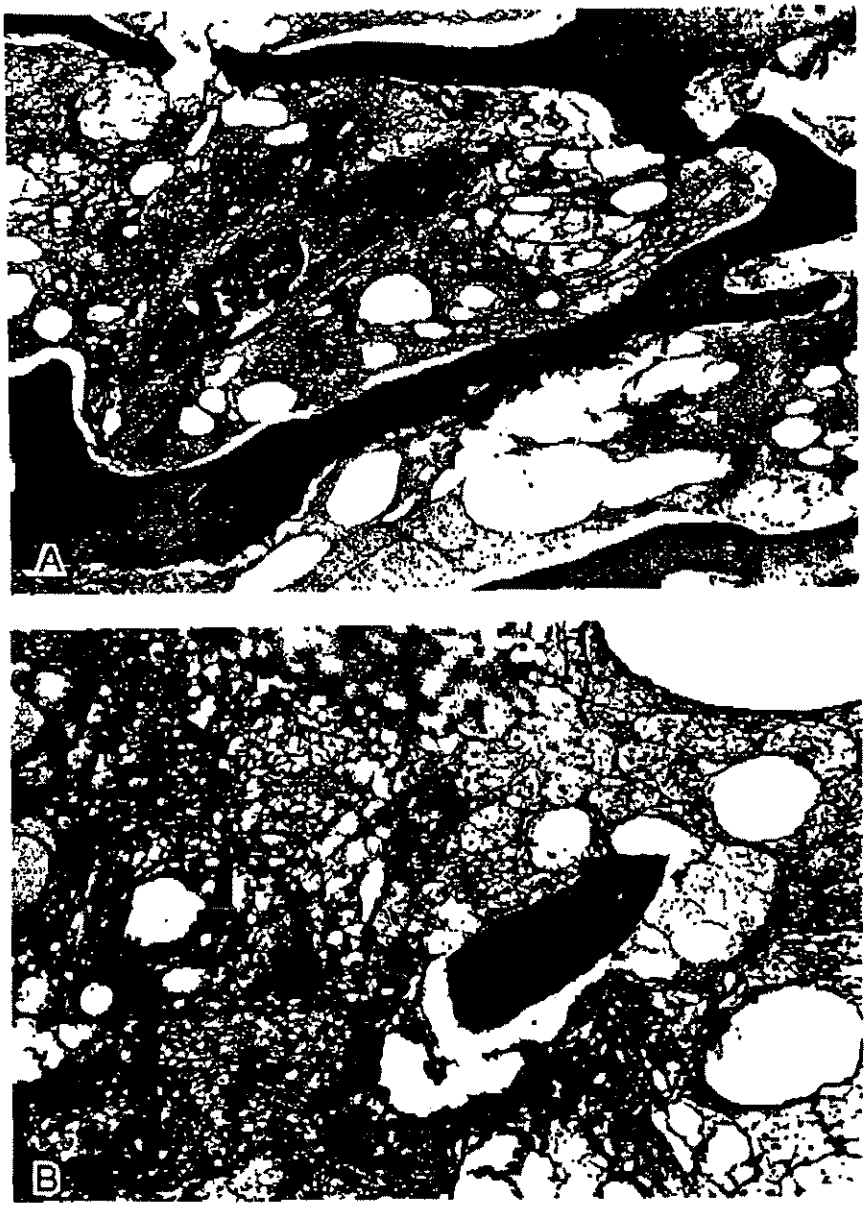

Fig. 6-28. Photomicrographs of the necrotic zone following cryosurgery at 3 weeks. (A) The bone marrow (Bm) typically showed extensive necrosis with necrotic trabeculae (N). There is a minimal inflammatory component. Occasional thickened thrombosed vessels (curved arrows) are seen. Vascular thrombosis is characteristically seen in severe cold injuries. Vascular thrombosis was never seen in the controls or after PMMA alone. (B) High-power photomicrograph demonstrating bone marrow necrosis.

graft but no LN showed viable graft at 1 week and good incorporation at 7 weeks. Conversely, those treated with LN showed no reossification or bone graft incorporation. In addition, those treated with LN demonstrated extensive circumferential necrosis, while those with PMMA showed no necrosis.

The most dramatic effect of LN was on the appearance of the bone marrow. In the control dogs the distal femoral marrow showed marked cellularity, whereas the marrow showed extensive necrosis with a minimal inflammatory response after cryosurgery. The marrow underwent liquefaction with progressive fibrosis. Throughout the frozen zone there was little evidence of neovasculature. Large, thickened, thrombosed vessels were seen occasionally and suggested a microvascular failure. No such vessels were seen in the controls. Gage also described early marrow liquefaction and progressive marrow fibrosis in 18 canine femora treated by cryosurgery.

At the periphery of the frozen zone there was an



Fig. 6-29. Photomicrographs of the necrotic zone following cryosurgery at 8 weeks. (A) Progressive marrow fibrosis (arrow) occurred following bone marrow necrosis. There is some minimal new bone formation (open arrow) on residual necrotic trabeculae (N). Note the absence of osteoblasts. New bone is formed by direct fibrous metaplasia. (B) New bone formation occurred at the periphery and was abnormal. There is calcification (solid arrows) of the necrotic marrow which then undergoes bony metaplasia (open arrow). The amorphous mineralization tends to form bone and/or cartilage slowly upon existing trabeculae (T). This combination of necrotic trabeculae, increased calcification, and metaplastic bone corresponds to the area of increased density ("cryonecrotic" rim) seen on the plain radiographs (see Fig. 6-31).

unusual pattern of large amounts of amorphous calcification and cartilage formation that slowly (at 7 and 8 weeks) showed some tendency to enchondral and/or metaplastic bone formation and apposition to necrotic trabeculae. There was minimal evidence of direct osteoblastic formation. This type of bone formation, which represented the dominant mode of peripheral repair in the dogs treated by LN, was not seen in the controls. In addition, this zone best correlated with the radiographic zone of necrosis and the rim of increased fluorescence on whole mount histologic studies.

It is interesting that the "necrotic" rim seen on the radiograph following cryosurgery corresponds to the area of amorphous calcification and cartilage formation in the periphery of the frozen zone. It appears to be an abortive attempt to repair the necrotic zone. Despite complete histologic necrosis, the radiographs did not demonstrate increased sclerosis until new bone formation oc-

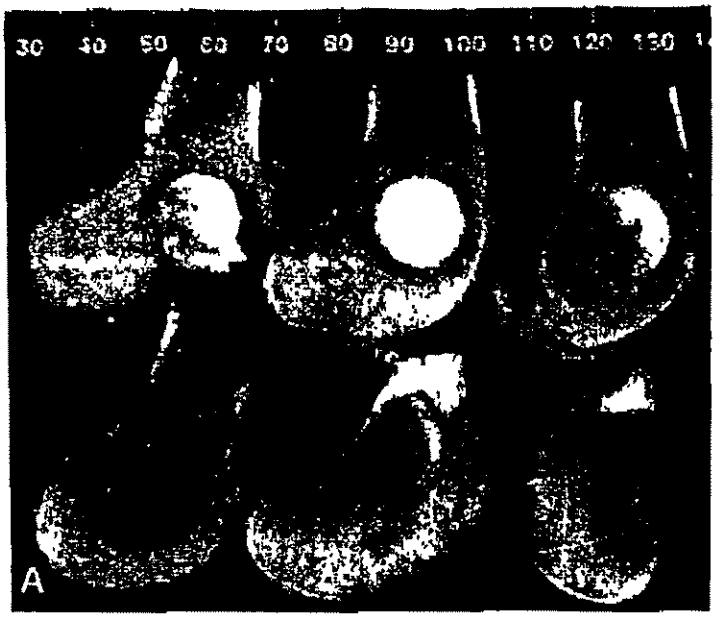

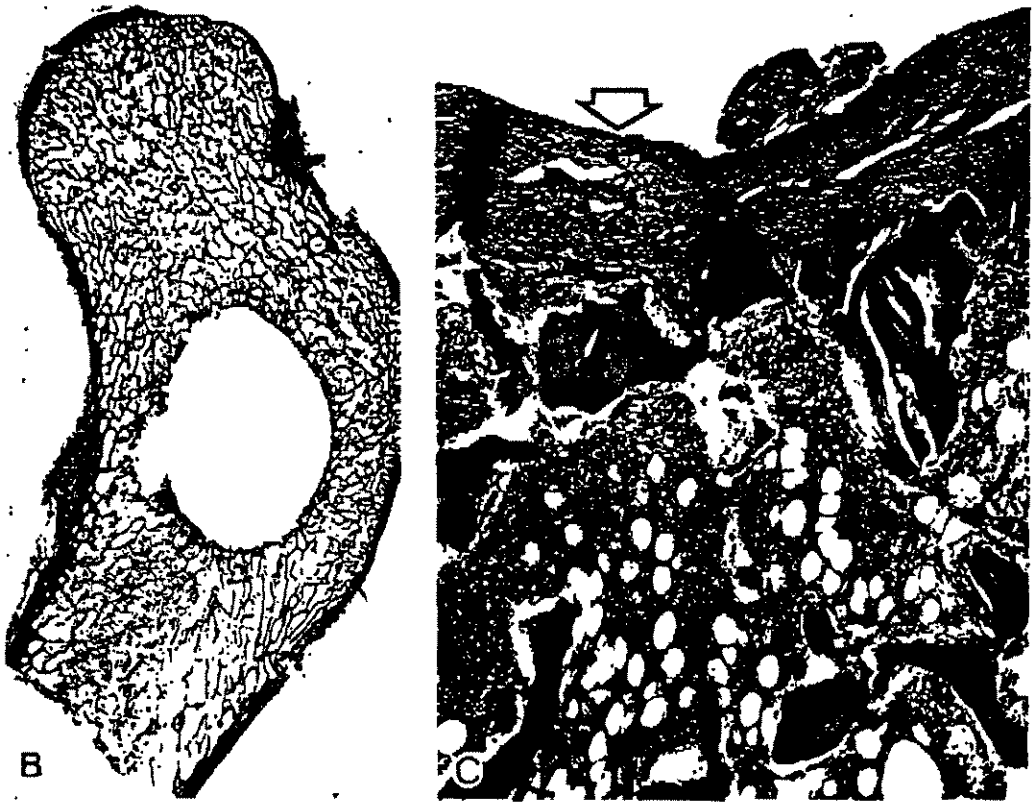

Fig. 6-30. Group III (PMMA). (A) Gross specimen following curettage and PMMA only. (B) Whole mount of distal femur. The PMMA was removed during preparation. The bone appears grossly normal. (C) Photomicrograph of the wall of the cavity. Note the normal bone marrow adjacent to the cavity. There is a narrow vascular fibroblastic interface (arrows) between normal bone and the PMMA and no evidence of trabecular or bone marrow necrosis (hematoxylin and eosin).



Fig. 6-31. Radiograph of a distal femur 8 weeks after cryosurgery. A typical sclerotic ("cryonecrotic") rim is seen (arrows) and represents an area of necrotic bone with superimposed calcified marrow and metaplastic bone. All dogs treated by cryosurgery demonstrated this finding at 7–8 weeks. Similar findings occur in humans after cryosurgery.

curred. This contrasts with the author's clinical experience following second-look biopsies of frozen cavities, which have shown the rim to be completely necrotic *without* new bone formation. The increased "sclerosis" in humans may result from a relative osteoporosis of the normal bone in addition to eventual new bone formation. The dogs did not develop osteoporosis because they were kept ambulatory.

Although we made no attempt to use cryopreservatives or intraarticular irrigation, the articular cartilage appeared normal in all animals despite evidence that the freeze extended to the subchondral bone. This suggests that articular cartilage is somehow protected from the damaging effects of freezing. We hypothesize that the synovial fluid may act as a cryoprotective agent. The extracellular matrix may be first appear to protect the cells, but similar protection was not provided to osteoblasts normally found deep in trabecular matrix. Another possible explanation is the difference in vascularity of articular cartilage cells and trabecular osteoblasts.

Survival of articular cartilage depends on synovial fluid production, whereas osteoblastic survival requires a blood supply. This could explain the difference in survival of these two tissues, if the assumption of microvascular failure is correct. One should not, however, generalize the resistance of cartilage cells to cryotherapy, since malignant cartilage can be killed in human subjects by cryosurgery, as demonstrated in the local control of low-grade chondrosarcomas.[3] This is presumably due to the vascular dependency of intramedullary cartilage tumors in contrast to hyaline cartilage.

This study has demonstrated that the pattern of bone formation following cryosurgery was delayed and abnormal; there was increased chondrogenesis with minimal enchondral ossification and little evidence of the typical pattern of osteoblastic activity as seen in the controls. A localized microvascular failure is suggested by the lack of revascularization

Case 1:04-cv-00204-JJF Document 160-5 Filed 04/13/2005 Page 29 of 30

and the progressive marrow collagenization with increased chondrogenesis in lieu of osteogenesis. It is well known that a low pO_2 (decreased vascularity) favors cartilage production whereas high pO_2 (increased vascularity) favors osteogenesis.[6] This may explain the finding of marrow calcification and increased cartilage. The study suggests that damage to the microvascular circulation is probably responsible for late progressive necrosis after the freeze and for the difficulty in subsequent repair of frozen bone.

Can these defects eventually reossify? We did not attempt to answer that question. Similar studies must be performed over a longer period of time to determine if reossification and graft incorporation occur, but at a decreased rate. Our 8-week specimens suggests that they may.

What are the mechanisms of cellular necrosis? They include thermal shock, dehydration and toxic effects of electrolyte imbalance, denaturation of cellular protein, formation of intracellular crystals, and membrane disruption and microvascular failure.[7-13] In general, the formation of intracellular ice crystals is considered the main mechanism of cellular necrosis. Temperatures between -21 and $-60°C$ are essential for cellular necrosis.[2,6] As the temperature rises during thawing, intracellular crystals coalesce and mechanically disrupt the cell membrane, causing cell death. Other variables include the presence of cryoprotective molecules, the size and temperature of the heat sink (local vasculature), the rate of cooling, the number of freeze–thaw cycles, the rate of thaw, and the duration of the freeze.[8,13-15] In general, a rapid freeze and a slow thaw result in the maximum cellular and tissue necrosis. Repeated freeze–thaw cycles also increase the amount of necrosis. In this study we used a double freeze–thaw cycle without cryoprotective molecules with a tourniquet, all of which were designed to maximize necrosis. Although this study included only 20 femurs and was limited to a relatively short period of time, it demonstrated that liquid nitrogen is a powerful modality in causing bony necrosis. We assume that tumor necrosis will be affected similarly since neoplastic cells are generally even more sensitive to cold temperatures than are normal cells.

We believe cryosurgery, as demonstrated in this study, may play a significant role as a surgical adjunct to curettage. Future studies should aim to modify the technique of cryosurgery to decrease the rate of bony necrosis. The dog model described is a useful investigative technique.

SUMMARY AND CONCLUSIONS

Cryosurgery caused marked trabecular and bone marrow necrosis. PMMA did not cause any bony necrosis. Cryosurgery decreased the rate of bone graft incorporation. The pattern of reossification following cryosurgery was delayed and is abnormal. The collagenized marrow, lack of revascularization with increased chondrogenesis in lieu of osteogenesis, and vascular thrombosis suggest a vascular insult (i.e., ischemic infarction of the bone) as the major cytocidal event.

ACKNOWLEDGMENT

This work was supported by a research grant from the Research Foundation of the Washington Hospital Center, Washington, D.C.

REFERENCES

1. Marcove RC, Lyden JP, Huvos AC, Bullough PB: Giant cell tumors treated by cryosurgery. A report of twenty-five cases. J Bone Joint Surg 55A:1633, 1973
2. Marcove RC, Searfoss RC, Whitmore WF, Grabstald H: Cryosurgery in the treatment of bone metastases from renal cell carcinoma. Clin Orthop 127:220, 1977
3. Marcove RC, Stovell PB, Huvos AC, Bullough PB: The use of cryosurgery in the treatment of low and medium grade chondrosarcomas. A preliminary report. Clin Orthop 122:147, 1977
4. Gage A, Greene GW, Neiders ME, Emmings FG: Freezing bone without excision. An experimental

study of bone cell destruction. JAMA 196:770, 1966
5. Persson BM, Wouters HW: Curettage and acrylic fixation cementation in surgery of giant cell tumor of bone. J Bone Joint Surg 120B:125, 1976
6. Bassett CAL, Herman I: Influence of oxygen concentration and mechanical factors in differentiation of connective tissues in vivo. Nature 190:460, 1961
7. Jennings JW Sr: Production and control of low temperatures in cryosurgery. Assoc Oper Room Nurs 7:41, 1968
8. Harris L, Griffiths J: Relative effects of cooling and warming rates on mammalian cells during the freeze–thaw cycle. Cryobiology 14:662, 1977
9. Karow AR, Webb WR: Tissue freezing, a theory for injury and survival. Cryobiology 2:99, 1965
10. Kreyberg L: Local freezing. Proc R Soc Lond [Biol] 147:546, 1957
11. Luyet BJ, Gehenio MP: Life and Death at Low Temperatures. Biodynamica, Normandy, Missouri, 1940
12. McGann LE, Kruuv J, Frim J, Frey HE: Factors affecting the repair of sublethal freeze-thaw damage in mammalian cells. Suboptimal temperature and hypoxia. Cryobiology 12:530, 1975
13. Miller RH, Mazur P: Survival of frozen–thawed human red cells as a function of cooling and warming velocities. Cryobiology 13:404, 1976
14. Mazur P: Theoretical and experimental effects of cooling and warming velocity on the survival of frozen and thawed cells. Cryobiology 2:181, 1966
15. Mazur P: Cryobiology: the freezing of biological systems. Science 168:939, 1970

NOTICE
THIS MATERIAL MAY BE PROTECTED
BY COPYRIGHT LAW (TITLE 17, U.S. CODE)

Management of Aggressive Benign and Low-Grade Malignant Bone Tumors by Cryosurgery: Analysis of 40 Cases

M. M. Malawer, B. K. Dunham, T. Zaleski, and C. J. Zielinski

Cryosurgery is the use of extreme cold to produce tissue necrosis. Cooper[1] reported the first direct surgical application and effective instrumentation using cryosurgery in 1963. Using a cryoprobe, he treated a patient with Parkinson's disease by selectively destroying a portion of the basal ganglia. This report stimulated the interest of surgeons in this modality. Gage et al.[2] demonstrated in 1966 the effectiveness of cryosurgery in destroying bone both clinically and in a dog model. Basic scientific research into the cellular effect of cryosurgery and the physics of ice crystal formation subsequently led to an increased understanding of this modality.[3–8] Within the past 2 decades cryosurgery has become accepted as an effective therapeutic modality for select benign and malignant lesions in several surgical fields, including gynecology, head and neck surgery, dermatology, and ophthalmology.[9–11]

Cryosurgery has not yet gained widespread acceptance among orthopedic surgeons. One exception is Dr. R. Marcove[12] at Memorial Sloan–Kettering, who has used cryosurgery in the treatment of metastatic and selected benign (aggressive) bone tumors since 1964. He has reported extensively on his experience with the use of cryo-