IN THE UNITED STATES DISTRICT COURT
FOR THE DISTRICT OF DELAWARE

KYPHON, INC., Plaintiff, v. DISC-O-TECH MEDICAL TECHNOLOGIES, LTD. and DISC ORTHOPAEDIC TECHNOLOGIES, INC., Defendants.	Civil Action No. 04-0204-JJF **REDACTED – PUBLIC VERSION**

APPENDIX OF EXHIBITS TO DEFENDANTS DISC-O-TECH MEDICAL TECHNOLOGIES, LTD.'S and DISC ORTHOPAEDIC TECHNOLOGIES, INC.'S CLAIM CONSTRUCTION MEMORANDA AND MOTIONS FOR SUMMARY JUDGMENT OF NON-INFRINGEMENT AND INVALIDITY

VOLUME 4

MORRIS, NICHOLS, ARSHT & TUNNELL
Maryellen Noreika (#3208)
E-mail address: mnoreika@mnat.com
1201 N. Market Street
P. O. Box 1347
Wilmington, DE 19899-1347
(302) 658-9200
Attorneys for Defendants/Counterclaimants
Disc-O-Tech Medical Technologies, Ltd.
and Disc Orthopaedic Technologies, Inc.

OF COUNSEL:

Eric J. Lobenfeld
Jonathan M. Sobel
Hogan & Hartson L.L.P.
875 Third Avenue
New York, NY 10022
(212) 918-3000

April 6, 2005

INDEX TO APPENDIX OF EXHIBITS TO DEFENDANTS DISC-O-TECH MEDICAL TECHNOLOGIES, LTD.'S and DISC ORTHOPAEDIC TECHNOLOGIES, INC.'S CLAIM CONSTRUCTION MEMORANDA AND MOTIONS FOR SUMMARY JUDGMENT OF NON-INFRINGEMENT AND INVALIDITY

Tab and Exhibit Number	*Title*
A	**REDACTED**
A-A	**REDACTED**
A-1	Curriculum Vitae of Michael David Mitchell, MD
A-2	U.S. Patent No. 4,969,888 (" '888 patent")
A-3	U.S. Patent No. 5,108,404 (" '404 patent")
A-4	U.S. Patent No. 6,235,043 (" '043 patent")
A-5	U.S. Patent No. 3,626,949 (" '949 patent")
A-6	U.S. Patent No. 4,878,495 (" '495 patent")
A-7	U.S. Patent No. 4,909,252 (" '252 patent")
A-8	U.S. Patent No. 5,049,132 (" '132 patent")
A-9	Aebi, M., "The internal skeletal fixation system. A new treatment of thoracolumbar fractures and other spinal disorders," Clin. Orthop., Vol. 227, pp. 30-43, 1988 ("Aebi")
A-10	Blauth, M., "Therapeutic Concept and Results of Operative Treatment in Acute Trauma of the Thoracic and Lumbar Spine: The Hannover Experience," J. of Orthop. Trauma, Vol. 1, No. 3, pp. 240–252, 1987 ("Blauth")
A-11	Campbell's Operative Orthopaedics, A.H. Crenshaw, Ed., 7th ed., Chapter 44, pp. 1653–1663, 1987 ("Campbell")
A-12	Carlson, "The Use of Methylmethacrylate in Repair of Neoplastic Lesions in Bone," Radiology, Vol. 112, pp. 43-46, July 1974 ("Carlson")
A-13	Daniaux, H., "Technik und Ergebnisse der transpedikulären Spongiosaplastik bei Kompressionsbrüchen im Lendenwirbelsäulenbereich," Acta Chir. Austr. (Suppl.), Vol. 43, pp. 79-80, 1982 ("Daniaux 1982")

Tab and Exhibit Number	*Title*
A-14	Daniaux, H., "Transpedikuläre Reposition und erste Spongiosaplastik bei Wirbelkörperbrüchen der unteren Brust und Lendenwirbelsäule," Unfallchirurg, Vol. 89, pp. 197-213, 1986 ("Daniaux 1986")
A-15	Dick, W., "Use of the Acetabular Reamer to Harvest Autogeneic Bone Graft Material: A Simple Method for Producing Bone Paste," Arch. Orthop. Trauma Surg., Vol. 105, pp. 235 – 238, 1986 ("Dick 1986")
A-16	Dick, W., "The 'Fixatuer Interne' as versatile implant for spine surgery," Spine, Vol. 12 (9), pp. 882-900, 1987 ("Dick 1987")
A-17	Edeland, H.G., "Open Reduction of Central Compression Fractures of the Tibial Plateau," Acta Orthop. Scand., Vol. 47, pp. 686-689, 1976 ("Edeland")
A-18	Kennedy, W., "Fractures of the Tibial Condyles: A Preliminary Report on Supplementary Fixation with Methylmethacrylate," Clin. Orthop., Vol. 134, pp. 153-157, 1978 ("Kennedy")
A-19	Ma, Yuan-zhang, "Os Calsis Fracture Treated by Percutaneous Poking Reduction and Internal Fixation," Chinese Medical Journal, Vol. 97, No. 2, pp. 105-110, 1984 ("Ma")
A-20	Olerud, S., "Transpedicular Fixation of Thoracolumbar Vertebral Fractures," Clin. Orthop., Vol. 227, pp. 44-51, 1988 ("Olerud")
A-21	Pentelenyi, T., "First Hungarian Neurosurgical Experiences with 'Fixateur Interne' in the Treatment of Thoraco-lumbar Spine Injuries," Acta Neurochir. (Wien), Vol. 93, pp. 104-109, 1988 ("Pentelenyi")
A-22	Schatzker, J., Operative Orthopaedics, M. Chapman, Ed., 1st ed., Ch. 35, pp. 421 – 434, 1988 ("Schatzker")
A-23	Scoville, W., "The Use of Acrylic Plastic for Vertebral Replacement or Fixation in Metastatic Disease of the Spine," J. Neurosurg., Vol. 27: 274-279, Sept. 1967 ("Scoville")
A-24	Record Of Invention -- "Balloon Assisted Fixation of Osteoporotic Fractures" Invention Disclosure Statement, by Arie Scholten and Mark Reiley, dated September 26, 1988
A-25	**REDACTED**

Tab and Exhibit Number	*Title*
A-26	**REDACTED**
A-27	**REDACTED**
A-28	INTENTIONALLY LEFT BLANK
A-29	INTENTIONALLY LEFT BLANK
A-30	Memorandum Opinion, Kyphon Inc. v. Disc-O-Tech Medical Technologies Ltd. and Disc Orthopaedic Technologies, Inc., USDC-D-Del., Civil Action No. 04-204 JJF, dated December 10, 2004
B	**REDACTED**
B-A	Invalidity Charts for the '734 and '054 Patents
B-1	U.S. Patent No. 6,241,734 (" '734 patent")
B-2	U.S. Patent No. 6,613,054 (" '054 patent")
B-3	U.S. Patent No. 4,576,152 (" '152 patent")
B-4	U.S. Patent No. 4,801,263 (" '263 patent")
B-5	U.S. Patent No. 5,108,404 (" '404 patent")
B-6	U.S. Patent No. 5,312,333 (" '333 patent")
B-7	U.S. Patent No. 5,415,631 (" '631 patent")
B-8	U.S. Patent No. 5,741,261 (" '261 patent")
B-9	U.S. Patent No. 5,919,196 (" '196 patent")
B-10	U.S. Patent No. 6,017,348 (" '348 patent")
C	**REDACTED**
C-A	**REDACTED**
D	**REDACTED**
D-A	**REDACTED**
D-1	U.S. Patent No. 6,241,734 B1

Tab and Exhibit Number	*Title*
D-2	U.S. Patent No. 6,613,054 B2
E	**REDACTED**
E-1	**REDACTED**
E-2	Selected articles referring to ceramic calcium phosphate compounds
E-3	U.S. Patent No. 4,518,430
E-4	M. Malawer, M. Marks et al., " Effect of Cryosurgery and PMMA on Tumor Cavity: Evaluation of Bone Necrosis and Bone Graft Incorporation in a Dog Model"
E-5	Limb Salvage Article, bearing production numbers DOTINC 050479-050537
E-6	**REDACTED**
E-7	**REDACTED**
E-8	**REDACTED**
E-9	Mathis, J. M. et al., "Percutaneous Vertebroplasty: A Developing Standard of Care for Vertebral Compression Fractures,"
E-10	Tsai, T. T. et al., "Polymethylmethacrylate Cement Dislodgement Following Percutaneous Vertebroplasty: A case report"
E-11	Stricker, K. et al., "Severe Hypercapnia Due to Pulmonary Embolism of Polymethylmethacrylate During Vertebroplasty,"
E-12	Bernard Padovani et al., "Pulmonary Embolism Cause by Acrylic Cement: A Rare Complication of Percutaneous Vertebroplasty"
F	File History for U.S. Patent No. 5,108,404 bearing production numbers KY 228908- 229043
G	File History for U.S. Patent No. 4,969,888 bearing production numbers KY 228787-228907

Tab and Exhibit Number	*Title*
H	File History for U.S. Patent No. 6,235,043 (B1) bearing production numbers KY 229044-229364
I	Stedman's Medical Dictionary ("Stedmans"), (27th ed.)
J	Medline definitions
K	**REDACTED**
L	**REDACTED**
M	**REDACTED**
N	**REDACTED**
O	Letter from Thomas Halkowski to Judge Poppiti, dated February 9, 2005, and Letter from Jonathan Sobel to Thomas Halkowski, dated February 11, 2005 (re: Kyphon not asserting claims from the '110 Patent)
P	**REDACTED**
Q	**REDACTED**
R	**REDACTED**
S	**REDACTED**
S-A	**REDACTED**
T	**REDACTED**
U	**REDACTED**
V	**REDACTED**
W	Medrad, Inc. v. MRI Devices Corp., 2005 WL 605532 (Fed. Cir. Mar. 16, 2005)
X	**REDACTED**
Y	**REDACTED**
Z	**REDACTED**

Tab and Exhibit Number	*Title*
AA	**REDACTED**

E

REDACTED

E-1

REDACTED

E-2

Acta orthop. scand 48, 150–157, 1977

POROUS CERAMICS AS A BONE SUBSTITUTE IN THE MEDIAL CONDYLE OF THE TIBIA

An Experimental Study in Sheep. Long-Term Observations

P. BENUM, S. LYNG, T. ALM & N. JOHANNESSEN

Surgical Department II, Ullevaal University Hospital, Oslo 1, and Central Institute for Industrial Research, Forskningsveien 1, Oslo 3, Norway.

A recent 3-month implantation study indicated that a new porous ceramic material might be suitable as a bone substitute in regions exposed mainly to compressive forces. The porous ceramics were implanted into the medial condyle of the tibia of sheep. In the present study the implants were left for 10 months in three animals, and 12 months in two. In the two animals with 12 months' observation, the plate which had been used to stabilize the implant was removed at 10 months. The implants and the adjacent bone tissue were studied macroscopically, radiographically and by microradiography and transmitted light microscopy. All the implants were bound to the adjacent bone by ingrowth of bony tissue. The depth of the bony invasion was slightly greater than that observed at 3 months, being maximally 3–4 mm. Some signs of ossification were still seen within the pores. The bony bridges between the implants and the surrounding bone were particularly well developed in regions of maximal stress. This was interpreted as a sign of active adaption of the bone formation to the actual stress to which the shearing surfaces were exposed. It is concluded that the properties of the porous ceramic implants justify a clinical trial in man.

Key words: bone substitute; porous ceramics; tibial condyle fracture

Accepted 17.xii.76

In a previous study (Benum et al. 1976) a new porous ceramic material was tested for possible use as a bone substitute in regions exposed mainly to compressive forces. The porous ceramics which mainly consisted of Al_2O_3 were implanted into the medial condyle of the tibia in sheep and left in position for 3 months. The implants were found to be bound to the adjacent bone by ingrowth of bony tissue. It was concluded that a clinical trial was justified if the results of long-term observations proved equally satisfactory.

In the present investigation we have studied the fate of the implants for up to 12 months and have paid particular attention to the anchorage of the implants to the surrounding bony tissue.

MATERIAL AND METHODS

The implants were similar to those used in the short-term observations. The pore size was 100–1000 μ (Benum et al. 1976).



Figure 1. ... *the implan*... *There is n*...

Animals

Six fem... used. The... epiphyseal... all animal...

Surgical p...

The ope... same man... operative ... et al. 197... disease; t... affected by ...

Investigative pr...

Three animals... operation. In t...

The material on this page was copied from the collection of the National Library of Medicine by a third party and may be protected by U.S. Copyright law.

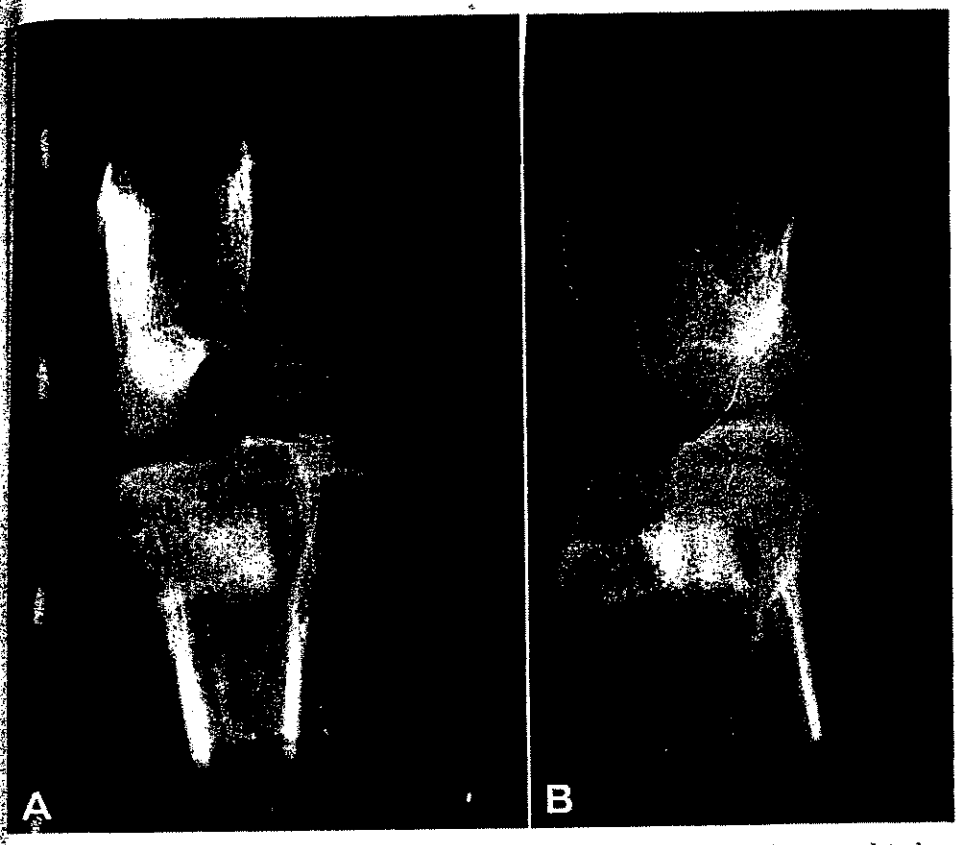

Figure 1. Radiographs of an implant 12 months postoperatively. The plate which was used to keep the implant in position was removed 2 months prior to sacrifice. A. Frontal view. B. Medial view. There is no sign of collapse of the tibial plateau and no sign of osteolysis around the implant.

Animals

Six female sheep, weighing 45–60 kg, were used. Their age varied from 6 to 8 years; epiphyseal fusion of the tibia had occurred in all animals.

Surgical procedure, postoperative regimen

The operations were performed in exactly the same manner as described earlier; the postoperative regimen was also unchanged (Benum et al. 1976). One animal died of intercurrent disease; the five others appeared totally unaffected by the operation.

Investigative procedure

Three animals were sacrificed 10 months after operation. In the remaining two the operated knee was X-rayed at 10 months, the AO-fingerplate was then removed, and the animals allowed to resume their normal activities for another 2 months before they were sacrificed.

After sacrifice the operated knee and the proximal part of the tibia were removed and inspected, the specimens were fixed in formaldehyde, X-rayed and dehydrated in alcohol, and finally embedded in methylmethacrylate as described earlier (Benum et al. 1976).

The subsequent investigative procedure was also similar, except that all sections were cut in the coronal plane.

Contact micro-radiographs were taken of 300 μ thick sections, as described by Jowsey et al. (1965). The sections were then ground down to a thickness of 40–50 μ and stained with Paragon

The material on this page was copied from the collection of the National Library of Medicine by a third party and may be protected by U.S. Copyright law.

1301 ("Paragon PS 1301", Paragon C & Co, 1 nc, Bronx, N.Y., USA).

Both contact micro-radiographs and stained sections were examined by light microscopy.

RESULTS

Function and macroscopic appearance

All the surviving animals recovered normal function after the operation. At sacrifice there were no signs of local infection or reaction around the implants. All the implants appeared firmly anchored to the surrounding bone, and there were no macroscopic signs of fracture of the implants or the tibial condyles.

Radiological examination

No signs of fracture or collapse of the impants or the tibial condyles were seen at sacrifice. There were no signs of resorption of bone above or below the implants. In the two cases where the plate had been removed 2 months prior to sacrifice, no radiographic changes were seen after removal of the plate (Figure 1).

Microradiography

The findings were almost identical in all the animals. In all parts of the implants which were in contact with bone, all surface irregularities and the most peripheral pores appeared to be filled with bone. The invasion of bony tissue was most extensive in the part of the implants which rested upon the supporting peripheral ring of cortical or cancellous bone. The maximal depth to which the pores appeared to be filled with bone was 3–4 mm. The depth of bone invasion was considerably less in the superior surface of the implants. Here the ingrowth of bone appeared most pronounced along the periphery of the implants, in particular medially.

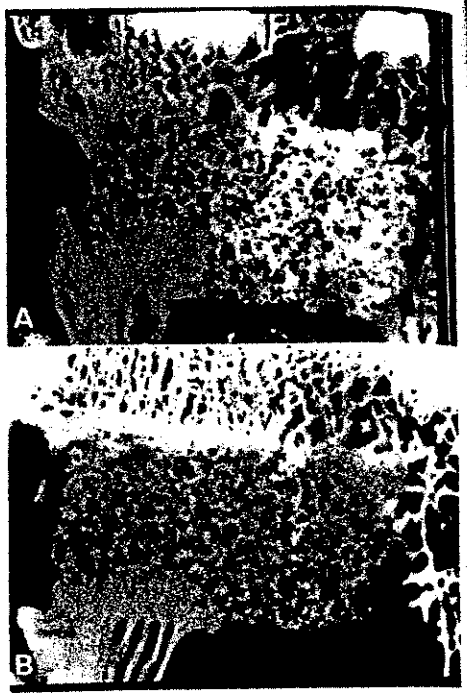

Figure 3. Microradiographs of sections through an implant. Observation period: 10 months. (× 2.5). A. From the transition zone between the anterior and middle third of the implant. B. From the most posterior region. Ingrowth of bone is most extensive in the area corresponding to the supporting peripheral ring of bone. The maximal depth of bone invasion is approximately 4 mm (A). On the superior surface of the implant the bone invasion is also most pronounced medially. In both microradiographs the adjacent bone at the undersurface appears thickened.

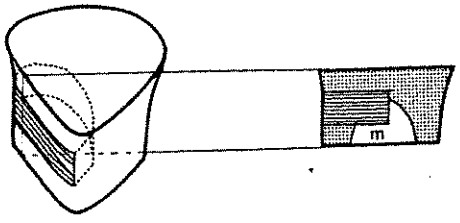

Figure 2. Schematic illustration of a specimen and a section removed from the middle part of the implant. The dotted area represents bony tissue. m.: medullary cavity. (The anterior and posterior regions and also the lateral part of the implant were surrounded by bone).



Figure 4. (× 4). The mi further poster bone is simila There is no in

The material on this page was copied from the collection of the National Library of Medicine by a third party and may be protected by U.S. Copyright law.



Figure 4. Microradiographs of sections of an implant (same implant as Figure 1) at 12 months (× 4). The microradiographs demonstrate the ingrowth of bone in the most anterior part (A), and further posteriorly to the most posterior part (F). The relation of bone invasion to the adjacent bone is similar to that shown in Figure 3 but the extent of the invasion is slightly less pronounced. There is no ingrowth of bone in those parts of the implant which are not in contact with bone.

The material on this page was copied from the collection of the National Library of Medicine by a third party and may be protected by U.S. Copyright law.



Figure 5 A. General view from the lower part of the implant (× 11.5). The picture demonstrates that the pores of the lower part of the implant are filled with bone. The pores of the more central region are filled with connective tissue. (Compare Figure 5, B and C). The lower part of the implant is completely surrounded by bone. The bone trabeculae (t) of the adjacent bone are directly continuous with those of the bone within the pores (details in Figure 5 B).



Figure 5 B. Detail from the lower part of Figure 5 A (× 28).

Figure 5. Photomicrographs of a slide from the anterior part of an implant. The slide was prepared from the section demonstrated microradiographically in Figure 4 A. (Paragon).

The adjacent bone was markedly thickened on the undersurface of the implants, corresponding to the area of maximal invasion. This was particularly true in the supporting peripheral ring of bone (Figures 3 and 4).

Histological examination

The histological examination verified the occurrence and distribution of bony tissue as found by the microradiographic investigation. The most peripheral pores were completely filled with bone in all areas of the implant surrounded by bony tissue, and bony invasion in the deeper pores was found in the area adjacent to the peripheral ring of cortical or cancellous bone. Generally no connective tissue was seen interposed between the bony tissue and the ceramics in these regions. Most parts of the bony tissue appeared trabecular. The trabeculae of the adjacent bone were directly continuous with those of the new bone in the pores (Figure 5, A and B). Occasionally Haversian channels could be observed (Figure 5 D). In the central regions of the implants, and in those parts of the implants which were not adjacent to bone, the pores appeared to be filled with connective tissue (Figure 5 C). Occasionally narrow bone trabeculae surrounded by connective tissue were seen in these regions.

Osteoblasts and osteoid tissue were found on the surface of the bone trabeculae in some pores, indicating appositional bone growth (Figure 5 E). Intramembranous



Figure 5
Figure 5
within
(c) wit
Figure 5



Figure
arrow)
(b). Th
the bon

ossificatior
pores whic
(Figure 5)
served.

The material on this page was copied from the collection of the National Library of Medicine by a third party and may be protected by U.S. Copyright law.

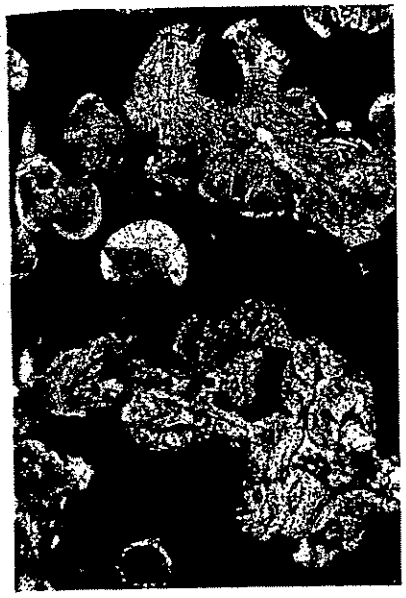

Figure 5 C. Detail from the area demarcated in Figure 5 A (× 28). The occurrence of bone (b) within the lower pores and connective tissue (c) within the overlying pores (details in Figure 5 I) are demonstrated.



Figure 5 D. This picture demonstrates a Haversian channel (indicated by arrow) (× 115).



Figure 5 E. A row of osteoblasts (indicated by arrow) on the surface of the bone trabeculae (b). The dark zone between the osteoblasts and the bone represents osteoid tissue (× 115).



Figure 5 F. Demonstrating intramembranous ossification. Osteoblasts (indicated by arrow) are seen at the border between the connective tissue (c) and the intramembranous bone (b). The dark zone lining the bone represents osteoid tissue (× 115).

ossification was seen within some of the pores which contained connective tissue (Figure 5). Osteoclasts were rarely observed.

The connective tissue within the pores was generally well vascularized and contained fibroblasts (Figure 5, I and J). No special infiltration of round cells or

The material on this page was copied from the collection of the National Library of Medicine by a third party and may be protected by U.S. Copyright law.



Figure 5 G. Detail from the contact area between bone and ceramics. No connective tissue is interposed between the bone (b) and the ceramics (ce). The osteocytes are lying close to the ceramics (× 360).

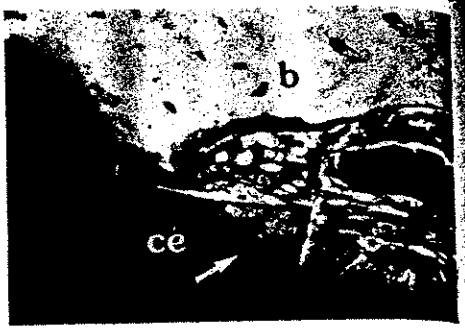

Figure 5 H. Foreign body cells (indicated by arrow) lying between the bone (b) and the ceramics (ce). (The picture is overexposed in order to distinguish the cells from the dark surroundings) (× 360).



Figure 5 I. This picture shows highly vascular connective tissue within a pore (× 15).



Figure 5 J. Detail from Figure 5 I demonstrating that the connective tissue contains a considerable number of fibroblasts (× 360).

leucocytes indicating inflammatory reaction could be observed within the implants. Osteocytes were observed close to the ceramics (Figure 5 G); in some regions, however, some foreign body cells could be observed (Figure 5 H).

There were no changes in the implants observed for 12 months which indicated loosening after removal of the plate.

DISCUSSION

We have previously reported that after 3 months porous ceramic implants were found to be bound to the adjacent bone by ingrowth of bony tissue, in some regions to a depth of 2–3 mm. Some osteoid tissue and signs of osteoblastic activity were still seen (Benum et al. 1976).

In the present study some ossification was still taking place within some pores of the implants. Since osteoclasts were rarely observed, it seems reasonable to assume that the appositional bone formation on the surface of the bone trabeculae leads to an increased bone mass, and not only reflects a process of remodelling. The finding of intramembranous ossification undoubtedly indicates that bony tissue is still being formed within pores previously occupied by connective tissue.

The maximal depth of bone invasion

The material on this page was copied from the collection of the National Library of Medicine by a third party and may be protected by U.S. Copyright law.

Case 1:04-cv-00204-JJF Document 160 Filed 04/13/2005 Page 20 of 47

was only slightly greater at 10 and 12 months, compared with that at 3 months. However, the bone bridges between the host bone and the implants corresponding to the areas of high stress had developed considerably. It seems reasonable to assume that the bone formation within the pores during the earliest period after implantation represents a phase of unorganized callus formation. Remodelling then probably takes place due to the actual mechanical stress on the bone bridges between the bone and the implant. Such remodelling is of the utmost importance, not only if porous ceramics are to be used as a bone substitute, but even more so if this material should be employed in fixation of endoprostheses.

In the present experiments the connective tissue appeared highly active metabolically, being vascular and rich in fibroblasts. Intramembranous bone formation was observed within this tissue and appositional trabecular bone formation was still taking place. It seems unlikely, however, that larger porous ceramic implants would become completely filled with bone, if applied clinically. Hence the strength of such impants cannot be expected to increase significantly with the invasion of bone. According to the specifications of compressive strength given earlier (Benum et al. 1976), it seems unlikely, however, that the porous ceramics should be weaker than the surrounding cancellous bone if used as a bone substitute in regions mainly exposed to compressive forces. The compressive strength of the porous ceramics employed in our studies compares favourably with the strength of cancellous bone in the tibial condyles reported by other investigators (Behrens et al. 1974).

Porous alumina ceramics have previously been found to be chemically inert and it has further been shown that such ceramics do not produce any significant adverse reactions after implantation. (Klawitter et al. 1969, Hulbert et al. 1970, 1972, Rhinelander et al. 1971, Nilles et al. 1973). The findings of the present study, that osteocytes were lying close to the ceramics, without interposition of connective tissue, and furthermore the lack of significant foreign body reactions around or within the implants, confirm that the ceramics possess a high degree of biocompatibility.

Due to the present knowledge of the properties of porous ceramics we feel that a clinical trial of porous ceramics as a bone substitute in regions mainly exposed to compressive forces is justified.

REFERENCES

Behrens, J. C., Walker, P. S. & Shoji, H. (1974) Variations in strength and structure of cancellous bone at the knee. *J. Biomechan.* **7**, 201–207.

Benum, P., Lyng, S., Bø, O., Rafn, I. & Haffner, J. F. W. (1976) Porous ceramics as a bone substitute in the medial condyle of the tibia. *Acta orthop. scand.* **47**, 158–166.

Hulbert, S. F., Morrison, S. J. & Klawitter, J. J. (1972) Tissue reaction to three ceramics of porous and non-porous structures. *J. biomed. Mater. Res.* **6**, 347–374.

Hulbert, S. F., Young, F. A., Mathews, R. S., Klawitter, J. J., Talbert, C. D. & Stelling, F. H. (1970) Potential of ceramic materials as permanently implantable skeletal prostheses. *J. biomed. Mater. Res.* **4**, 433–456.

Jowsey, J., Phil, D., Kelly, P. J., Riggs, B. L., Bianco, A. J., Scholtz, D. A. & Gershou-Cohen, J. (1965) Quantitative microradiographic studies of normal and osteoporotic bone. *J. Bone Jt Surg.* **47-A**, 785–806.

Klawitter, J. J., Hulbert, S. F. & Talbert, C. D. (1969) *Materials of construction for bone gap bridges.* Orthopaedic Surgery Papers of the Duke University Medical Center and Affiliated Hospitals, USA.

Nilles, J. L., Coletti, J. M. Jr. & Wilson, C. (1973) Biomechanical evaluation of bone-porous material interfaces. *J. biomed. Mater. Res.* **7**, 231–251.

Rhinelander, F. W., Rouweyha, M. & Muner, J. C. (1971) Microvascular and histogenic responses to implantation of a porous ceramic into bone. *J. biomed. Mater. Res.* **5**, 81–112.

Correspondence to: P. Benum, Orthopaedic Department, University of Trondheim Hospital, 7000 Trondheim, Norway.

The material on this page was copied from the collection of the National Library of Medicine by a third party and may be protected by U.S. Copyright law.

Ceramic-Plastic Material as a Bone Substitute

LYMAN SMITH, MD
ELGIN, ILL.

Introduction

The era in which we live has been described by engineers as The Materials Age. It is marked by a bewildering variety of materials developed since the turn of the century at an exponential rate. As surgeons, we are familiar with the metallurgical advances which have given us corrosion resistant alloys, as well as the many developments in the chemistry of plastics, which in some instances have been found to be useful in surgery. Another field of materials—ceramics—has also had tremendous growth in the last 20 years. Ceramic materials are now produced which have considerable strength and impact resistance, as well as great chemical resistivity. The latter characteristic is of prime interest to the surgeon, as the most important property of any surgical material is in its inertness in the environment of human tissue. Although strong, these new ceramic materials have the disadvantage of being extremely rigid. Attempts to produce a ductile ceramic material could follow either of two approaches—one being to alter the microstructures; the other being the formation of a combination or alloy of a ceramic with a more ductile substance. The latter approach has been accomplished by producing a ceramic which has a true interconnecting porosity. This ceramic body has then been impregnated with a close-bonding epoxy resin, thus producing a material which retains the hardness and corrosion resistance of ceramics, but also demonstrates resilience and adequate strength.*

Method of Production

A mixture was made consisting of alumina (Al_2O_3), silica (SiO_2), calcium carbonate ($CaCO_3$), and magnesium carbonate ($MgCO_3$). A so-called green body was then formed by a method commonly used in ceramic production, known as slip casting

Submitted for publication March 25, 1963

Assistant Professor of Orthopedic Surgery, Northwestern University Medical School

* The ceramic-plastic material was developed by Joseph F. Estes and Helmut Buchmann of The Haeger Potteries, Inc., Dundee, Ill.; R. J. Cooke of Arthur D. Little, Inc., Cambridge, Mass.; and myself.

This green body was placed in a furnace, and the temperature slowly raised to about 2,000 F for some hours. During this period, the magnesium carbonate decomposed to magnesium oxide and carbon dioxide gas and the calcium carbonate decomposed into calcium oxide and carbon dioxide gas. Since the individual particles of calcium carbonate and magnesium carbonate were small and thoroughly dispersed throughout the green body, the carbon dioxide gas produced by the decomposition thereof upon heating was also thoroughly dispersed and formed small individual cells that were uniformly distributed and of substantially uniform size. As the carbon dioxide gas formed was further heated, it passed from cell to cell and eventually to the surface of the body. Since about one third of the starting materials, on a dry basis, were carbonates, the green body had a high porosity of about 65% thereof by volume. This so-called prefired body was then finally fired at a temperature of about 2,700 F. The final porosity was controlled by controlling the firing temperature: the lower the firing temperature the higher the porosity and the higher the firing temperature the lower the porosity. In other words, with the higher temperatures, the ceramic body shrank more and thus produced the lower porosity. Porosities ranging from 6% to about 65% by volume of the fired ceramic member were achieved.

Four-inch ceramic bars of varying porosity were impregnated with a liquid aromatic epoxy resin of the diepoxide 0 type mixed with a hydroxy-aliphatic amine hardener. A bar was placed in a casting chamber from which air was evacuated by a water aspirator. The liquid resin and hardener were mixed at 50 C and run into the evacuated chamber. After the mixture had flooded the ceramic piece, positive pressure was applied and the part cooled. To insure complete curing of the resin, the bar was finally baked at 120 C for three hours. The method was successful in completely impregnating the ceramic bar as could be calculated by weight changes and by direct observation following destructive tests.

Cured epoxy resins are particularly inert to most chemicals and solvents as compared with other organic plastic materials. Methylene chloride, a halogenated hydrocarbon, is one solvent that slowly attacks the surface of epoxy formulated parts. Before the final temperature cure at 120 C for three hours is applied to the impregnated ceramic, there is a period just after impregnation when the resin is most susceptible to this solvent. It can be applied in various degrees of time and agitation to effect a complete surface removal of the impregnant. Once the resin has been completely cured, contact with the solvent would be necessary for some days. Fig 1 is a specimen which was dipped for three to five minutes in methylene chloride solvent after impregnation and before curing. It demonstrates a leaching away of the surface resin to a depth of 50 to 70 mils.

Examinations of the Material

Flexural Strength and Modulus of Elasticity.—Bars of the impregnated ceramic were prepared measuring 4×½×¼ inch. The bars varied in porosity from 6% to 65% by volume. The bar to be tested was supported at each end and a load applied from



Fig 1.—An impregnated ceramic bar after surface leaching. Reduced 58% from mag ×11.

above at the center on a table model "Instron" machine. The crosshead was lowered at the rate of 0.2 inch per minute, and an automatic recording of the deflection produced in the test bar was made. From the readings obtained, flexural strength in pounds per square inch (psi) was calculated as well as the modulus of elasticity (resistance to bending) for each sample. Both figures varied with the degree of porosity of the sample. A bar of 46% porosity was chosen as ideal because its modulus of elasticity was approximately the same as bone (3.0×10^6 psi) and its flexural strength was 12,000 psi, as compared to an average wet bone sample of 11,000 psi.

Resistance to Aging.—Test bars measuring $4\frac{1}{2} \times \frac{1}{2} \times \frac{1}{4}$ inch were placed in isotonic saline solution in glass tubes, and the tubes were sealed with the volume of air therein equal to the volume of the saline solution. The bars were then aged at elevated temperatures for varying periods of time. Three series of tests were run at 124 C, 149 C, and 180 C. The tubes were opened and a maximum bending stress for each bar expressed in psi was determined, by utilizing the test method described above. The value of flexural strength obtained on each test bar was graphed, and then, by extrapolation, the length of time it would take to reduce the flexural strength of the material to 8,000 psi at body temperature of 37 C (98.6 F) could be calculated. This age life was determined to be about 2×10^8 hours, or 23,000 years.

Abrasion Resistance.—A machine was used that provided a fresh abradent surface with each cycle of movement of a pressure head. A water-proof Carborundum silicone carbide paper was moved at a rate of five inches per minute under a one-fourth-inch diameter abradent head at a pressure of 100 pounds per square inch. The change in thickness due to abrasion was recorded as the movement of an electric displacement sensing device attached to the head of the abrader. The impregnated ceramic was abraded for 10,000 cycles as was a polished piece of Vitallium. The results are graphed in Fig 2 and show that the impregnated ceramic wore

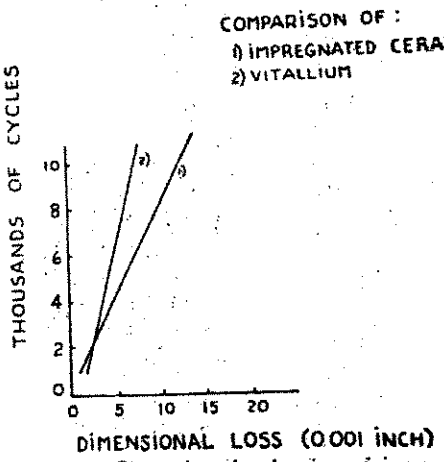

Fig 2.—Comparison in abrasion of impregnated ceramic and Vitallium.

less than the Vitallium for the first 3,000 cycles and was almost equal in continued cycles. As a further test, the abradent paper was removed and a piece of human bone with a hyaline cartilage face cut to one-fourth-inch diameter was mounted for movement against a piece of the impregnated ceramic. The cartilage was wetted every 1,000 cycles with two drops of synovial fluid. After 24,000 cycles, the impregnated ceramic had no change in its surface, while the cartilage sample lost 0.012 inch, most of which was removed during the first 10,000 cycles.

Hardness.—The hardness of an impregnated porous ceramic structure is difficult to define. Considered as a continuous surface structure rather than as each of two components, it was thought best to test the hardness by methods ordinarily used on metal. A Wilson-Rockwell instrument was used to test the material using a one-eighth-inch and a one-sixteenth-inch ball penetrator. The superficial hardness was found to vary inversely in accordance with the degree of porosity. The ceramic alone retained a hardness of 94 to 97 up to 28% porosity, as compared to a finding of 99 on Vitallium sample. The impregnated ceramic in the 50% porosity range showed a value of 83.

Pore Size.—Microscopic studies have shown the pores in a 46% porosity body to average 18μ in diameter with some up to 25μ (Fig 3).



Fig. 3.—Pore size and distribution in a ceramic body of 46% porosity. Reduced 58% from mag. × 210.

Fatigue.—Fatigue studies are being made on the material. The early results are good within the range of failure of the material. It is known that Vitallium will fatigue at about 40% of its failure strength; stainless steels fatigue at 45% to 50% of their failure strength. On the basis of preliminary data, it appears that the impregnated ceramic fatigues at 50% to 55% of its failure strength, although it should be realized that the failure strength of this material is well below that of metal.

Compression.—An Eicher type stainless steel hip prosthesis was duplicated out of this material. The stainless steel prosthesis weighed 1 lb 2 oz; the ceramic-plastic prosthesis weighed 11 oz. Each prosthesis was placed under compression in a universal tensile-testing machine. The stainless steel prosthesis failed by plastic deformation at approximately 550 lb; the impregnated ceramic failed by fracture at 608 lb. The results are graphed in Fig. 4.

Resistance to Chemicals.—The impregnated ceramic has been tested by immersing a piece in aqua regia for 24 hours at room temperature. No weight loss was recorded, and the same lack of reaction was found when the material was placed in 50% sodium hydroxide at body temperature for 48 hours.

Animal Studies

Methods.—Forty-two White Satin rabbits weighing an average of nine pounds have been used.† At irregular intervals, implants of the epoxy resin, the porous ceramic, and the impregnated ceramic have been placed in subcutaneous tissues, skeletal muscle, and knee joints. Operations were done under pentobarbital sodium (Nembutal) anesthesia plus 1% procaine locally.

† This work was aided by a grant from the Committee for the Advancement of Research, Sherman Hospital, Elgin, Ill.

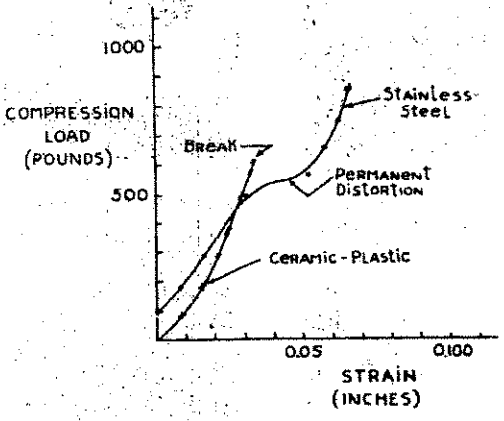

Fig. 4.—Compression test on stainless steel and ceramic-plastic hip prostheses (Eicher type).



Fig 5.—Prosthesis used to replace the superior articular surface of the femoral condyles.

Fig 5 is a photograph of a ceramic-plastic prosthesis shaped for insertion into the knee joint replacing the anterior portion of the femoral condyles in articulation with the patella. At operation, the knee joint was approached from the lateral aspect, and the patella and its tendinous attachments were dislocated medially. The anterior portion of the femoral condyles was removed by an oscillating saw to a point just short of the weight-bearing area and the prosthesis loosely laid into the cavity, the stem being pushed proximally up the medullary canal. The patella was then reduced into apposition with the prosthesis (Fig 6), and the wound was closed in layers after irrigation with saline solution. Some of the prostheses were surface leached of the plastic before insertion; others were not. The rabbits were kept out of doors in narrow cages 20 feet long with food and water at alternate ends to encourage activity. They were sacrificed at irregular intervals.

Results.—Three anesthetic deaths were encountered. Three postoperative deaths occurred at various times due to pneumonia, and three knee joints were grossly infected. Six fractured femurs into and proximal to the prosthesis were seen.

Fig 7 is a photograph of a transverse section taken through a prosthesis and femur three weeks after operation. The prosthesis was found tight in its bed, held so by cancellous bone and fibrous tissue grown in firm apposition to it. It was removed from the femur by chiseling. This firm apposition of bone to prosthesis has been a constant feature of all knees examined. Fig 8 shows the adherence of bone and fibrous tissue to a 40-day implant. The bone was allowed to dry and shrink away from the prosthesis, but close adherence is demonstrated even though in this prosthesis the epoxy had not been leached from its surface.

To date, six months have been the longest a leached prosthesis has been in place before autopsy. The knee of that rabbit showed no limitation of motion. On opening the joint, there was no increase in synovial fluid, the capsule was not bound down, and there were no intra-articular adhesions. The articular



Fig 6.—The prosthesis has been laid loosely in place and the patella reduced in apposition to it.



Fig 7.—Transverse section through femur and prosthesis three weeks after operation.

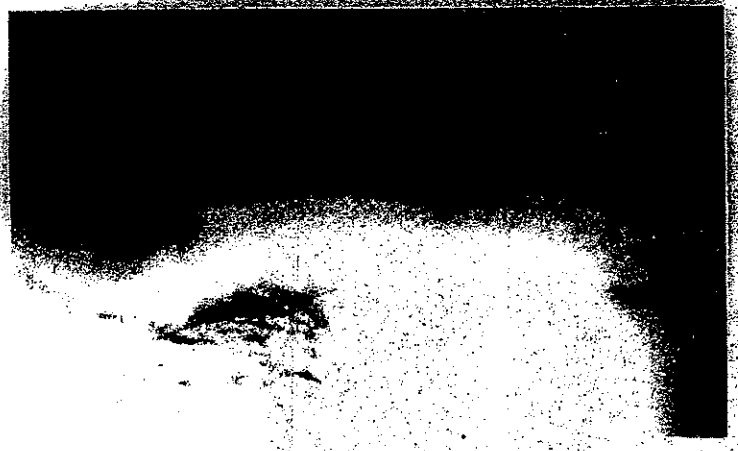

Fig 8.—Adherence of tissue to a 40-day implant. Reduced 11% from mag ×36.



Fig 9.—Section from bed beneath an implant in place six months. Reduced 11% from mag ×100.



Fig 10.—Articular cartilage of patella after six months apposition to the prosthesis. Reduced 11% from mag. ×100

cartilage was everywhere shiny and glistening. The prosthesis was firmly held in its bed by new bone and could not be removed until the femur was decalcified. Fig 9 is a section taken through a corner of the bed showing dense, relatively acellular fibrous tissue merging with osteoid and orderly trabeculae of lamellar bone. Fig 10 is a section through the articular cartilage of the patella showing no surface reaction to wear against the prosthesis. Fig 11 is the x-ray appearance of the knee at the time of insertion of the prosthesis, and Fig 12 is the same knee six months later. There is considerable endosteal calcification in the medullary canal about the peg of the prosthesis, and the bone trabeculae of the host appear to be interwoven with the substance of the prosthesis.

Fig 11.—Lateral view of knee joint a few hours after insertion of a prosthesis.





Fig 12.—The same knee joint as in Fig 11 six months later.

Fig 13 is a section from tissue immediately adjacent to a seven-week subcutaneous implant of epoxy resin. The implant was approximately the size of a shirt button and was freely movable. The section shows a thin layer of mesothelial cells overlying a loose areolar tissue. There are no giant cells or collection of polymorphonuclear leukocytes indicating an inflammatory reaction.

The pieces of the porous ceramic and the impregnated ceramic after leaching, which had been embedded in skeletal muscle, were examined after three to nine weeks. They were found to be tightly bound in place by



Fig 10.—Articular cartilage of patella after six months apposition to the prosthesis. Reduced 11% from ×300

cartilage was everywhere shiny and glistening. The prosthesis was firmly held in its bed by new bone and could not be removed until the femur was decalcified. Fig 9 is a section taken through a corner of the bed showing dense, relatively acellular fibrous tissue merging with osteoid and orderly trabeculae of lamellar bone. Fig 10 is a section through the articular cartilage of the patella showing no surface reaction to wear against the prosthesis. Fig 11 is the x-ray appearance of the knee at the time of insertion of the prosthesis, and Fig 12 is the same knee six months later. There is considerable endosteal calcification in the cancellary canal about the peg of the prosthesis, and the bone trabeculae of the host appear to be interwoven with the substance of the prosthesis.

Fig 11.—Lateral view of knee joint a few hours after insertion of a prosthesis.





Fig 12.—The same knee joint as in Fig 11 six months later

Fig 13 is a section from tissue immediately adjacent to a seven-week subcutaneous implant of epoxy resin. The implant was approximately the size of a shirt button and was freely movable. The section shows a thin layer of mesothelial cells overlying loose areolar tissue. There are no giant cells or collection of polymorphonuclear leukocytes indicating an inflammatory response.

The pieces of the porous [illegible] impregnated ceramic after [illegible] had been embedded in skeletal [illegible] were examined after three to nine weeks. They were found to be tightly bound [illegible]



Fig. 13.—Tissue surrounding a subcutaneous implant of epoxy resin after seven weeks. Reduced 14% from mag × 100.

fibrous tissue and normally colored muscle fibers in contrast to the synovial-like sheath found around similarly embedded inert metal alloys. In these instances, and in the case of the closely bound knee prosthesis, it has been assumed that fibrous tissue and perhaps bone had invaded the open pore structure. Such ingrowth has been demonstrated with polyvinyl sponge implants.[4] The ceramic is too hard to cut with the microtome, so thin sections have been prepared by grinding on sandpaper. Examination of these sections has been disappointing in that no fibrous tissue or bone has been seen. However, it is possible that soft tissues have been pulled out of the pores in the grinding process. Other methods of preparation are being attempted.

Comment

This material has been developed in the belief that it may act as a better substitute for bone than the metal alloys in common use. These alloys are almost ten times as strong and approximately ten times as stiff as the bone they are called upon to replace or to immobilize. On bending, there is a relative movement between the flexible bone and the rigid alloy which sets up high localized stresses on certain areas, and at these points bone is absorbed. The impregnated ceramic of 40% porosity has the same modulus of elasticity as bone and will bend symmetrically with it, thus avoiding such stresses.

The prime reason the 18-8 stainless steel and the cobalt-chromium molybdenum alloys have been used in surgery is their relative resistance to corrosion. Macrocorrosion is common with stainless steels,[1] and microcorrosion is seen with all types of metal alloys, including Vitallium.[2] This latter type consists in the deposition of metallic elements in the tissues around implants, but its significance is not known. Galvanic corrosion of alloys in the body, an electrochemical phenomena, is not seen in ceramic and plastic materials, which is the reason for their common use in industry for insulation. Some alloys and metals protect themselves from chemical corrosion by the formation of a thin layer of oxides on their surfaces; ceramic materials are commonly oxides, and could be loosely stated to have "already corroded." The epoxy resin used to impregnate the porous ceramic is also chemically inert. The structure of this class of polymers suggests that ether linkages are the only bonds other than the carbon to carbon. Ether linkages are among the most stable known to organic chemists so it follows that these resins are highly resistant to attack by various solvents, acids, and alkalis.

Epoxy shares its chemical inertness with other types of plastics, but was chosen over them because of its unique ability to bond tightly to the ceramic. Most plastics would only act as fillers in the void cavities of the ceramic, contributing little to the flexural strength of the material. The resistance-to-aging test showed that this tight bond between the epoxy and the ceramic would not materially deteriorate with time and temperature.

Some chemically inert plastics have been found to be toxic in tissues, due to remnants of catalysts or to unreacted molecules of the components of the plastics themselves. The completely cured epoxies have been found nondeleterious to health by medical investigators of the major resin manufacturers. Regardless of the type of curing agent used, the cross-linked epoxy apparently does no harm when powdered and fed to rats in massive doses over long periods.[3] However, dermatitis has been reported in workers handling the liquid amine hardeners used in preparation of the plastic.

The impregnated ceramic is far weaker than the metal alloys but equal with the strength of bone. Its strength should be adequate as a substitute for bone if used in sufficient mass and properly engineered. It is hoped that this material will be re-enforced by the growth of soft tissue and bone into the surfaces which have been leached of epoxy.

Summary

A material developed for use as a bone substitute is described. It is a porous ceramic composed of the high-temperature reaction products of alumina, silica, and the oxides of magnesium and calcium. The honeycomb structure of the ceramic is impregnated with a close-bonding epoxy resin. The resultant material is as strong as bone and has the same modulus of elasticity, is light in weight, inert in rabbit tissues, resilient, hard, difficult to abrade, and is highly resistant to acids and alkalis.

Lyman Smith, MD, 1185 Dundee Ave, Elgin, Ill.

REFERENCES

1. Cohen, J., and Hammond, G.: Corrosion in a Device for Fracture Fixation, J Bone Joint Surg 41A:524-534, 1959.

2. Ferguson, A. B.; Laing, P. G.; and Hodge, E. S.: The Ionization of Metal Implants in Living Tissues, J Bone Joint Surg 42A:77-90, 1960.

3. Skeist, I.: Epoxy Resins, New York: Reinhold Publishing Corporation, 1960.

4. Strnliers, A. M.: An Experimental Study of Polyvinyl Sponge as a Substitute for Bone, Plast Reconstr Surg 15:274-289, 1955.

0030-5898/87 $0.00+.20

Hydroxyapatite and Tricalcium Phosphate Bone Graft Substitutes

Robert W. Bucholz, MD, Ann Carlton, RPT,† and Ralph E. Holmes, MD‡*

The search for useful bone graft substitutes historically has focused on biologic alternatives. Allografts and xenografts from various sources have been processed using a number of different techniques and, indeed, have been effective in clinical practice. Their application, however, remains restricted because of limitations in the volume of material readily available at most institutions and problems with immunologic reaction to the foreign tissue. These volumetric and immunologic concerns with biologic implants have stimulated interest in the potential for synthetic, bioinert materials as bone graft substitutes.

Porous minerals of calcium and phosphate are an obvious choice for synthetic graft substitutes. They are biocompatible, easily fabricated into any size or shape, and offer a chemical environment and surface conducive to new bone formation.[10] Most current investigations involve hydroxyapatite, tricalcium phosphate (TCP), or combinations of these two minerals.

POROUS HYDROXYAPATITE

Background

A hydroxyapatite material that has received much attention in the last decade is derived from South Pacific coral. Coral is the limestone skeleton of various species of marine invertebrates. Its porous structure and dimensions are genus-specific. One scleractinian coral subtype (genus *Goniopora*) possesses a macroscopic architecture similar to human cancellous bone.[20] A simple hydrothermal exchange method of converting coral carbonate into pure hydroxyapatite ($Ca_{10}[PO_4]_6[OH]_2$) was developed at the Materials Research Laboratory of Pennsylvania State University[16] (Fig. 1). The unique coralline architecture remains unaltered during the chemical conversion, and the resultant porous hydroxyapatite material is devoid of any residual organic matter.

The *Goniopora* implant has pores of 500 to 600 μm width, with pore interconnec-

Portions of this material were presented to the Orthopaedic Research Society in Atlanta, Georgia, on February 8, 1984; to the Second World Congress on Biomaterials in Washington, DC, on April 29, 1984; to the Plastic Surgery Research Council in Detroit, Michigan, on April 4, 1984; and to the American Academy of Orthopaedic Surgeons in New Orleans, Louisiana, on February 24, 1986

*Associate Professor of Orthopaedic Surgery, University of Texas Southwestern Medical School, Dallas, Texas
†Orthopaedic Research Coordinator, University of Texas Southwestern Medical School, Dallas, Texas
‡Associate Clinical Professor, Division of Plastic Surgery, University of California San Diego Medical Center, San Diego, California

The material on this page was copied from the collection of the National Library of Medicine by a third party and may be protected by U.S. Copyright law.

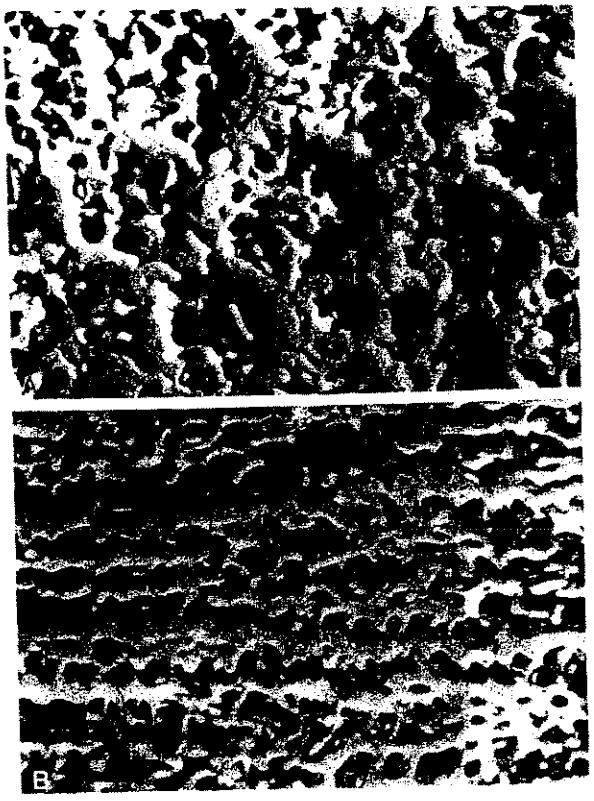

Figure 1. Cross section (*A*) and longitudinal section (*B*) of interporous hydroxyapatite derived from *Goniopora* coral (original magnification ×3). Bar length equals 1 mm.

tions of 220 to 260 μm. The trabeculae average 130 μm in thickness.

Animal Studies with Coralline Implants

The first experimentation with the coral-derived hydroxyapatite material commenced a decade ago. Chiroff[3] found that a cylinder 1 × 5 mm placed in the cancellous bone of the distal femur and proximal tibia of the dog filled with new bone. New bone invasion into other porous ceramic implants was limited to 2 mm or less. This quantitative difference was attributed to the unique interconnecting fenestrations of the coral implants, which permitted enhanced vascular and nutritional supply to the regenerating bone mass.

Subsequent animal models have compared various coral-derived hydroxyapatite implants with autogenous cancellous controls in dog mandibles,[5] dog lumbar spines,[6] dog tibial plateaus,[7] dog radial diaphyses,[8] dog calvaria (Holmes R, unpublished data), and a number of rabbit long-bone models.[19] The cancellous defect model of the dog proximal tibia approximates most closely how the implant has been used in human investigations. Through the medial cortex of the dog proximal tibial metaphysis 1 cm below the joint surface, a 1.25 × 1 × 1 cm defect was created bilaterally. The 1.25-cm dimension corresponded to the depth of the defect so that the 1.25-cm length of the implant was apposed to 1.0 cm of cancellous bone in the medullary canal and 0.25 cm of compact bone of the medial cortex. A 1.25 × 1 × 1 cm corticocancellous autograft was inserted in a similar press fit manner into the contralateral tibia.

Dog tibiae were harvested at 2, 4, 6, and 12 months after implantation. Microradiographs and histology confirmed complete implant and autograft incorporation at all

The material on this page was copied from the collection of the National Library of Medicine by a third party and may be protected by U.S. Copyright law.

Case 1:04-cv-00204-JJF Document 160 Filed 04/13/2005 Page 33 of 47

time intervals (Fig. 2). A morphologic gradient was evident, with more osteonic-type regenerated bone within the implant pores along the cortical margin and trabecular-type bone within the medullary portion of the implant. The bond between the regenerated bone and hydroxyapatite was intimate, with no fibrous tissue or inflammatory cells. This suggested bioincompatibility. Histomorphometric quantitation of bone regeneration demonstrated a regenerated bone volume fraction of 13.0 per cent, implant fraction of 35.1 per cent, and soft tissue fraction of 51.9 per cent. The fraction of implant plus bone exceeded that of the bone on the normal side, but the fraction of implant bone ingrowth alone was less than that of bone on the normal side. These fractions were fairly constant throughout all time intervals.[7]

A separate series of biomechanical tests using this proximal tibial model have been performed.[6] In its unimplanted state, porous hydroxyapatite from *Goniopora* coral is significantly weaker than cancellous bone. Its ultimate strength and energy absorption capacity depend upon the orientation of its channels in relation to the applied load. When the load is applied parallel to its channel axis, it has an ultimate strength of only 55 per cent of cancellous bone. Because of the lack of any collagen matrix, it does not exhibit any plastic behavior. After implantation in the tibial metaphysis for 6 months, the hydroxyapatite, together with its regenerated bone, exhibits significantly different mechanical properties. The average ultimate strength of 2500 N/cm² is three times greater than that of cancellous bone and 50 per cent greater than that of cancellous bone that has been implanted in the dog proximal tibia for 6 months. These changes in mechanical strength are probably secondary to the overlay of new bone on the trabeculae of the graft and implant material, rendering it a more dense structure.

The results of the experimental models disclosed two requisites for the successful use of synthetic hydroxyapatite in long bone defects. Rigid stabilization of all major bone fragments and close apposition of the implant to viable bone were critical if extensive bone ingrowth was to occur.



Figure 2. Microradiograph from a 12-month specimen. The porous architecture of the implant is preserved and bone incorporation is evident (× 1). Bar length equals 1 mm.

Clinical Trials

Food and Drug Administration approval for human investigation of porous hydroxyapatite in traumatic defects of long bones was obtained in 1982. Initial use was limited to small osseous defects but, as success with the technique accrued, larger volume defects were filled with the implant. Both metaphyseal and diaphyseal defects have been treated.

Technique in Metaphyseal Fractures. The basic principles of anatomic open reduction and rigid internal fixation are observed in all cases of comminuted intra-articular fractures. Split/compression fractures of the tibial plateau represent the single most common pattern of metaphyseal fracture necessitating the use of porous hydroxyapatite. Following adequate exposure of all components of the fracture through standard surgical incisions, the depressed osteochondral fragments of the plateau are elevated carefully. Osteotomes are em-

The material on this page was copied from the collection of the National Library of Medicine by a third party and may be protected by U.S. Copyright law.

ployed to maximize the thickness of subchondral cancellous bone attached to the articular fragments. Once the articular congruity has been precisely restored, the dimension of the resultant metaphyseal cancellous defect is measured.

An oversized block of gas-sterilized hydroxyapatite is contoured using rongeurs and scalpels to fill the proximal tibial defect. The attainment of a press fit of the hydroxyapatite with the surrounding cancellous bone is critical both for adequate buttressing of the articular fragment and for rapid ingrowth of regenerated bone. Any remaining small recesses or defects in the metaphysis should be filled with variable-sized granules of the hydroxyapatite. The major cortical fracture fragments are then reduced, thereby enhancing the press fit of the implant. Standard ASIF interfragmental screw and plate fixation complete the stabilization procedure. Preceding wound closure, the stability of the osteochondral fragments is tested by manual compression of the articular surface. Radiographs prior to closure confirm complete filling of the entire defect (Fig. 3).

All limbs are immediately placed in a constant passive motion apparatus for a period of 5 to 7 days and then protected in a cast brace or knee orthosis for an additional 2 to 3 months. Partial weight-bearing progressing gradually to full weight-bearing is begun at 2 months. All other aspects of preoperative, intraoperative, and postoperative care are identical with those of tibial plateau and other metaphyseal fractures managed with autogenous bone graft.

Technique in Diaphyseal Fractures. Long-bone fractures with comminution involving greater than one third of the diaphyseal circumference are included in the clinical trials. After anatomic alignment of the major proximal and distal fracture fragments, rigid stabilization is accomplished with an appropriate length compression plate or, less frequently, intramedullary nail. Minor fracture fragments too small for interfragmental fixation are left displaced with care to avoid devitalizing their soft tissue attachments.

The dimensions of the diaphyseal defect dictate the size of hydroxyapatite block selected for contouring. The oversized block is then fashioned with a rongeur or scalpel to fill the entire defect from the opposite intact cortex through the medullary canal to the comminuted cortex. Accurate contouring of the hydroxyapatite lessens the risk of postoperative displacement (Fig. 4). The soft tissues, including any remaining periosteum, are closed tightly over the implant and fracture. The postoperative management varies with the fracture location and stabilization. Lower extremity fractures stabilized with plates require prolonged protection from weight-bearing, while those with intramedullary nails do not. Postoperative follow-up is similar to that for comparable fractures in which autogenous graft is used.

Materials and Results. Forty-six patients have been implanted with hydroxyapatite for traumatic defects of long bones. All patients presenting with osseous defects sufficiently large to warrant bone grafting were offered the alternative of porous hydroxyapatite. Contraindications to the use of hydroxyapatite included open fractures, fractures in children with open physes, pathologic fractures, and active contiguous infections. The mechanism of injury was motor vehicle accidents in 32 cases, falls in 10, and gunshot injuries in 4. There were 25 men and 21 women, with an average age of 34.5 years (range, 17 to 67 years). All operations were performed between 6 hours and 5 days from the time of injury.

Metaphyseal defects arising from axial compression injuries to adjacent joint surfaces constituted 34 of the cases. The location of the defect was tibial plateau in 23, distal tibia in 4, distal radius in 3, and distal femur in 4. All but three cases had displaced osteochondral fragments impacted into the crushed cancellous bone of the metaphysis. Following reduction and rigid internal fixation of all major components of the fracture, the resultant metaphyseal defects varied in volume from 1 to 120 cc (mean, 9.5 cc; median, 2.5 cc). A satisfactory press fit of the block hydroxyapatite was achieved in all cases.

Diaphyseal defects (12) secondary to

The material on this page was copied from the collection of the National Library of Medicine by a third party and may be protected by U.S. Copyright law.

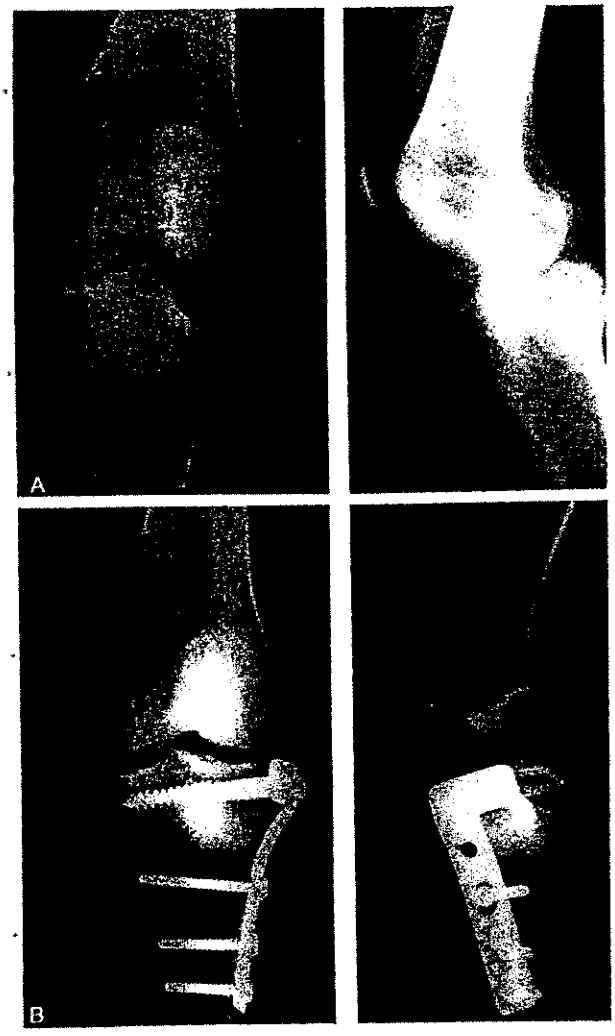

Figure 3. *A*, Anteroposterior and lateral radiographs of a split-compression type of lateral plateau fracture. *B*, Postoperative radiographs demonstrate an anatomic reduction with buttressing of the osteochondral fragments with a large block of radiodense hydroxyapatite.

high-energy bending forces were located in the tibia (3), femur (1), humerus (3), radius (3), and ulna (2). The volume of the cortical defects ranged from 1 cc to 4 cc. Postoperative radiographs demonstrated adequate filling of all defects with the block hydroxyapatite. No supplemental autogenous graft was used in any of the 46 cases.

All patients, except eight who were lost to follow-up, were monitored closely to the completion of their fracture healing. Follow-up periods ranged from 7 to 48 months (average, 26 months).

Fracture union was achieved in all cases. Radiographic evaluation of the amount of bone regeneration and the status of bone repair was difficult. The metaphyseal fractures healed with minimal periosteal reaction. The absence of fracture fragment subsidence and a halo around the hydroxyapatite implant was interpreted as presumptive evidence of bone regeneration. The dense radiographic image of the hydroxyapatite prevented direct quantification of bone ingrowth. In most cases, the adjacent cancellous trabeculae blended into the sides of the implant without evidence of radiolucent lines at the interface. Fracture union, as judged by disappearance of all cortical and cancellous fracture lines, occurred at an average of 28 weeks, identical with that noted in a comparable group of historical autograft controls.

The material on this page was copied from the collection of the National Library of Medicine by a third party and may be protected by U.S. Copyright law.

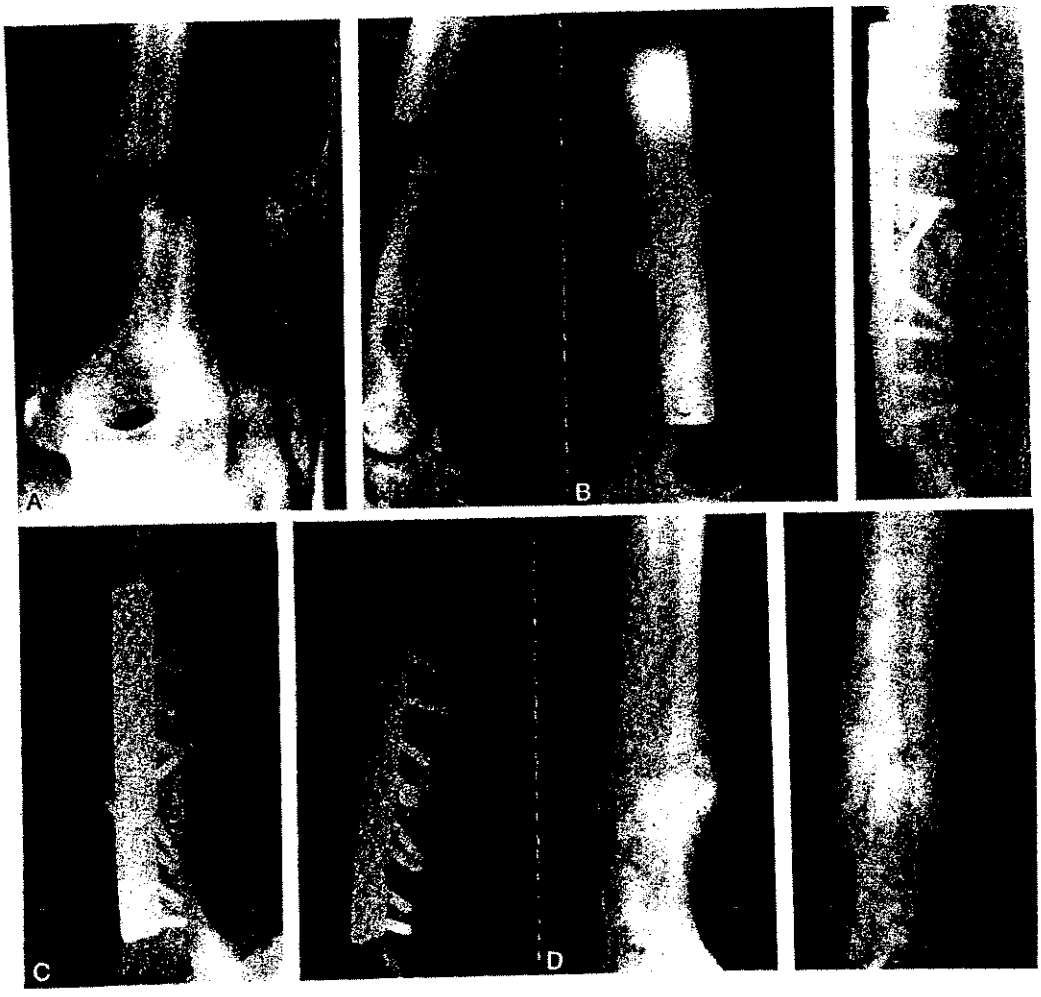

Figure 4. *A*, Anteroposterior and lateral radiographs of a moderated comminuted, unstable, distal humeral shaft fracture. *B*, Fixation was achieved with a posterior, dynamic compression plate. The anterior cortical defect representing more than 50 per cent of the circumference of the diaphysis was filled with hydroxyapatite. *C*, By 6 months, abundant new bone formation engulfed the hydroxyapatite and spanned the fracture defect. *D*, Following plate removal at 15 months, excellent remodeling of the regenerated bone was evident.

Bone regeneration was easier to judge in the diaphyseal defects. Periosteal new bone routinely engulfed the onlay/inlay implant, which remained closely apposed to the underlying cortical and medullary bone. Trabeculae of new bone completely spanning the fracture defect were radiographically evident at an average of 5 months after fracture fixation.

The functional results were comparable to those with historical controls. No adverse reaction to the hydroxyapatite, such as excessive postoperative drainage, erythema, or other wound problems, was witnessed in the immediate postoperative period.

Four major complications occurred in these 46 patients. These included one early loosening of a humeral plate, one soft tissue slough, one contiguous septic arthritis, and one loss of reduction followed by a late-onset infection. None of these complications were attributable to the hydroxyapatite.

Continuing radiographic observations up to 4 years after implantation have not shown

The material on this page was copied from the collection of the National Library of Medicine by a third party and may be protected by U.S. Copyright law.

any irrefutable evidence of biodegradation of the implants.

Histology of Human Biopsies

Noninvasive techniques are currently unavailable for the evaluation of bone ingrowth into porous minerals. The dense radiographic image of the hydroxyapatite precludes any simple radiographic assessment. Densitometric assessment has been used experimentally but is not yet applicable to clinical cases.[17] Biopsy of the implant at the time of elective hardware removal is therefore essential in determining the extent of bone regeneration.

Biopsy of the hydroxyapatite has been taken in 10 patients at the time of elective hardware removal. Care was exercised to minimize the biopsy size and to avoid crushing the biopsy specimen. Fluoroscopic images were used to ensure that the biopsy was taken from the center of the hydroxyapatite implant. Standard hard tissue fixation, embedding, and sectioning were performed.

Patients' ages ranged from 20 to 61 years, and the postimplantation intervals ranged from 7 to 18 months (average, 11 months). The biopsied cases included seven proximal tibial metaphyseal fractures, two distal tibial metaphyseal fractures, and one humeral diaphyseal fracture.

The morphology of the bone ingrowth depended upon the site of biopsy (Fig. 5). The more superficial (cortical) portions of the specimens showed compact bone with regenerated osteons filling the hydroxyapatite pores. The deeper (medullary) sections demonstrated normal-appearing trabeculae in close apposition to the hydroxyapatite. Osteocytes, osteoblasts, and osteoclasts were present in proportions suggesting a normal turnover of new bone. While osteoclasts were occasionally seen along the implant surface, no conclusive evidence of implant biodegradation was apparent. The morphology of the implant trabeculae appeared intact, and no inflammatory cells were evident in any sections.

Histomorphometric quantitation of bone regeneration into the hydroxyapatite revealed an average bone volume fraction of 40.7 per cent, implant volume fraction of 31.8 per cent, and soft tissue volume fraction of 27.5 per cent.

TRICALCIUM PHOSPHATE

Background

Several specially processed ceramic forms of beta-tricalcium phosphate ($Ca_3[PO_4]_2$) have been extensively investigated in dental and orthopedic applications. The synthetic, porous implant used most frequently in long bone defects is produced by homogenizing a tricalcium phosphate powder with naphthalene. Following compaction of the mixture, the naphthalene is removed by sublimation, leaving pores within the ceramic. The pore configuration is maintained by a sintering process. The resultant implant has a 36 per cent porosity and variable pores ranging from 100 to 300 μm in diameter. Either blocks or large granules can be fabricated easily.

Animal Studies with Tricalcium Phosphate

Early studies using tricalcium phosphate demonstrated that TCP elicits little, if any, inflammatory response. The absence of any contaminating proteins ensures its biocompatibility. The breakdown products of TCP are identical with the natural calcium and phosphate ions in the body fluids. Resorption of the material occurs at such a slow rate that increases in blood levels of calcium and phosphate are not detected. The porous scaffolding of the implant permits rapid bone ingrowth. Gradual replacement of the ceramic with mature remodeling bone is noted as bioresorption of the TCP proceeds.

Animal models using TCP have included rat tibia,[1,15] rat femur,[21] rabbit iliac crest,[9] rabbit tibia,[14,19] dog femur,[2] and dog tibia.[13] The rate of bone regeneration into the TCP pores varied depending upon the implant location (metaphyseal versus diaphyseal, cortical versus cancellous), the availability

The material on this page was copied from the collection of the National Library of Medicine by a third party and may be protected by U.S. Copyright law.





B



C



D

Figure 5. *A*, Preoperative, postoperative, and 18-month follow-up radiographs of a split-compression type of lateral plateau fracture. *B*, Low-power histologic appearance of biopsy specimen taken at time of plate removal (original magnification ×4). Bone regeneration throughout the full length of the specimen is seen at 15 months. Bar leugth equals 1 mm. *C*, Intramedullary portion of the implant. The trabeculae of regenerated bone are located in direct apposition to trabeculae of the hydroxyapatite (orginal magnification ×100). Bar length equals 100 μm. *D*, Cortical portion of the implant. Cortical bone fills the pores of the hydroxyapatite (original magnification ×100). Bar length equals 100 μm.

The material on this page was copied from the collection of the National Library of Medicine by a third party and may be protected by U.S. Copyright law.

Case 1:04-cv-00204-JJF Document 160 Filed 04/13/2005 Page 39 of 47

of local osteoprogenitor cells, and the stability of the surrounding bone. Thus, TCP showed little bone ingrowth when placed extraperiosteally or in an unstable mechanical environment. Biodegradation appeared to occur by both passive dissolution and osteoclastic resorption.

In a recent study using a rabbit tibia model, Shimazaki and Mooney compared bone regeneration into coralline hydroxyapatite (HA) and TCP implants.[19] The volume fraction of bone was greater in the coralline HA implants at both 3 and 24 weeks after implantation. This difference was attributed to the high degree of uniformity in pore diameter and interconnecting pores of the coral-derived HA, which permitted rapid vascular invasion and sustained bone ingrowth. The larger pore size of the HA also contributed to the greater bone regeneration. At 24 weeks, an average of 46 per cent of the volume of the TCP implants had biodegraded.

Clinical Trials with Tricalcium Phosphate

Tricalcium phosphate has been implanted as a bone graft substitute in 32 patients. The 20 males and 12 females with an average age of 32.5 years (range, 8 to 86 years) presented with either a post-traumatic bone defect (24 cases) or a benign tumor or cyst (8 cases).

The traumatic defects were managed in an identical fashion to those treated with hydroxyapatite. The fractures were located in the tibia (14), radius (6), ulna (3), and humerus (1). The technique of insertion of the granular or block TCP was similar to that described for the porous hydroxyapatite.

The eight bone tumor or cyst cases included four unicameral bone cysts, two osteoid osteomas, one nonossifying fibroma, and one giant tumor. Following thorough curettage of the entire cyst or en bloc resection of the nidus in cases of osteoid osteoma, the resultant defect was packed with a 1 to 2 mm diameter granular form of the implant. No supplemental autograft was used in any case. Either meticulous periosteal closure or replacement of a cortical window was performed to prevent postoperative extravasation of the granular TCP into the surrounding soft tissues.

With the exception of six patients lost to follow-up, all cases were closely monitored to fracture union or complete bone regeneration within the cyst. The excellent results for the traumatic defects paralleled those obtained with hydroxyapatite. Radiographic evidence of TCP biodegradation was present in many cases, especially where the implant was applied in a diaphyseal onlay fashion. Biopsy specimens have not been obtained.

When used to fill bone cysts, TCP remains radiodense for many months. The TCP-regenerated bone composite blends with the surrounding medullary and cortical bone without a halo of intervening fibrous tissue. The rate of radiographic disappearance of the TCP was variable (Fig. 6). Two unicameral bone cysts have recurred, necessitating further procedures.

FUTURE RESEARCH IN POROUS MINERALS

Porous hydroxyapatite and tricalcium phosphate are promising new biomaterials for the management of peripheral skeletal defects. In their current state, both serve as excellent scaffolds or matrices for the incorporation of connective tissue and, subsequently, regenerated bone in a manner similar to that of autograft. As with other calcium phosphate biomaterials, they have proven to be entirely biocompatible.[10] A direct bond without an intervening fibrous capsule forms between the mineral and the ingrowth bone. However, the clinical usefulness of these biomaterials is limited by their chemical and mechanical properties. Future research to expand the indications should focus on the four areas discussed in the subsequent four sections.

Mineral Composition

Hydroxyapatite and TCP release calcium and phosphate ions during their bioresorp-

The material on this page was copied from the collection of the National Library of Medicine by a third party and may be protected by U.S. Copyright law.

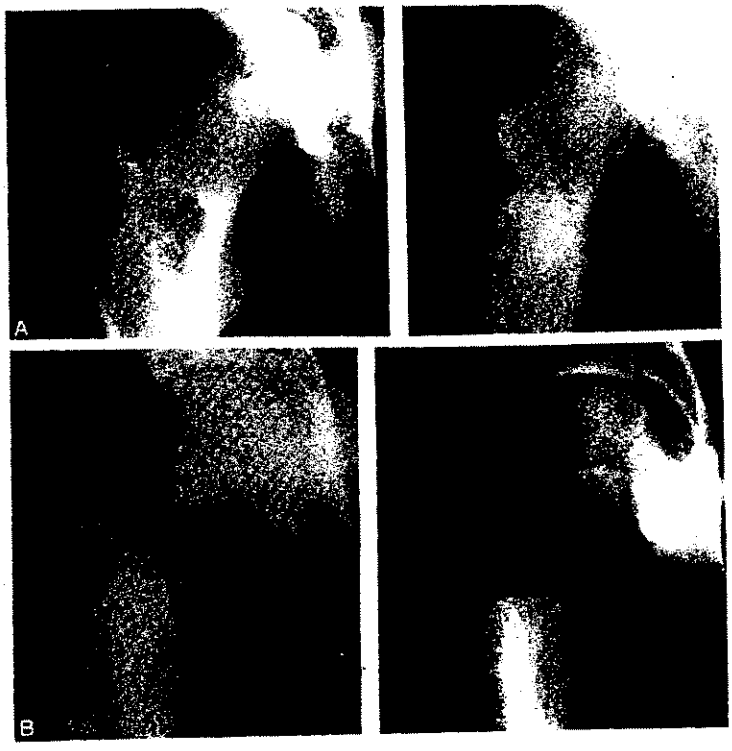

Figure 6. A, Preoperative (*left*) and immediate postoperative radiographs of a recurrent intertrochanteric unicameral bone cyst in a 14-year-old boy. Multiple aspirations and steroid injections had failed to cure this cyst. The cavity has been completely filled with a granular form of tricalcium phosphate following curettage of the cyst wall. *B*, Ten-month (*left*) and 18-month (*right*) follow-up radiographs demonstrate complete osseous filling of the defect with no cyst recurrence.

tion. Degradation of the implants occurs by either simple dissolution or cell-mediated processes (osteoclastic phagocytosis). The rate of biodegradation depends on its crystal/chemical composition, its density, its exposed surface area, and its proximity to soft tissue versus bone. Previous studies suggest that TCP dissolves much more rapidly than hydroxyapatite, especially when it is placed in soft tissues. Our clinical trials confirm this difference (Fig. 7). When quickly filled with regenerated bone, these porous materials appear to resorb at a slower pace.

The rate of bioresorption should ideally correspond to the clinical needs of any given case. The biologic half-life of a calcium phosphate implant would preferably be longer in those settings where some mechanical strength is required and shorter in those situations in which it merely serves as a spacer. Eventually, all implants should completely resorb, thereby permitting gradual remodeling of the ingrowth bone. Unfortunately, none of the currently available implants have standardized chemical and structural properties that allow for precise prediction of their rate of biodegradation. Future techniques in implant fabrication should solve this problem.

Pore Size and Configuration

The preferred pore size of a bone graft substitute remains controversial. Klawitter and Hulbert[11,12] demonstrated that a minimum pore size of 100 μm is required for effective bone growth. Their results suggested that a pore diameter of 150 μm might be optimal, but Flatley[4] recommended a large diameter of approximately 500 μm based on his experimental models. Similarly, the ideal pore configuration (parallel versus random, closed versus fenestrated) is unknown. The coral-derived hydroxyapatite implant, with its uniform pore size, configuration, and interconnecting fenestrations, would seem to have a theoretical advantage of better vascular and osseous ingrowth compared to the synthetic TCP with its random pore structure. Clinical proof

The material on this page was copied from the collection of the National Library of Medicine by a third party and may be protected by U.S. Copyright law.

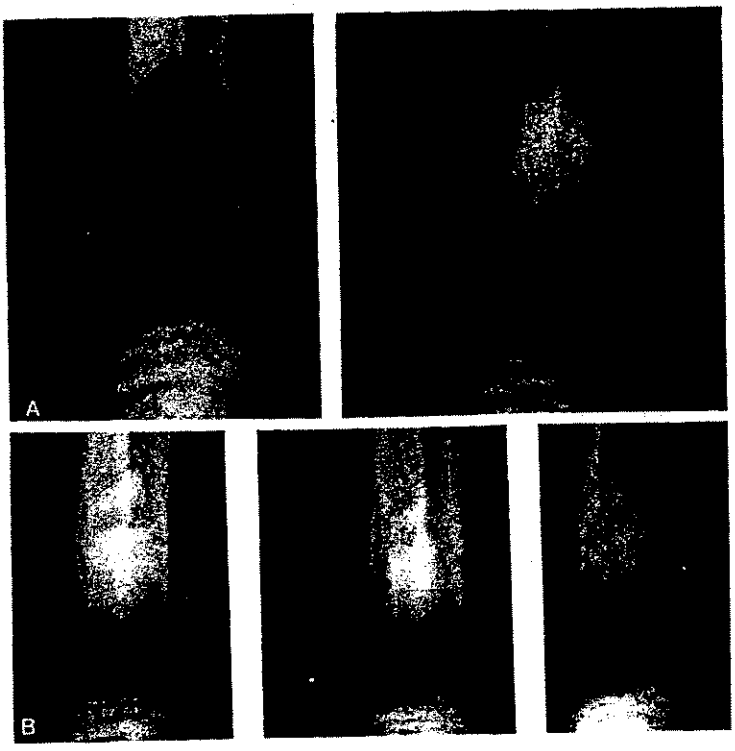

Figure 7. *A*, Preoperative (*left*) and postoperative (*right*) lateral radiographs of a large nonossifying fibroma in a 12-year-old child. Multiple pathologic fractures had occurred through this large lesion, which showed no evidence of spontaneous involution. Curettage and filling with TCP implant were used as definitive treatments. *B*, Follow-up radiographs at 1, 3, and 6 months. Extravasation of a portion of the granular TCP occurred through the cortical window. By 3 months, much of the TCP in the soft tissue had resorbed. Complete bioresorption was evident by 6 months. The cyst cavity healed without further treatment.

substantiating this theory will require additional quantitated biopsy specimens in humans.

The optimal pore diameter probably differs with the location of the defect to be filled. The porous structure of the implant should resemble the morphology of the bone being replaced. Thus, the *Goniopora* coral material should be used for cancellous defects, while TCP or an alternative scleractinian coral, *Porites*, with a 200 to 250 μm diameter pore may be preferred for cortical replacements. Since pore size also directly influences its mechanical properties and rate of bioresorption, the decision making on proper implant selection may be complex.

Mechanical Properties

Because of their brittle ceramic nature, calcium phosphate biomaterials lack substantial mechanical integrity. The surrounding bone must be intact or rigidly stabilized to shield the ceramic from loading during bone ingrowth. While compressive loads are moderately well tolerated,[6] the implants will fragment when subjected to shear forces. Additionally, the material should be tightly interlocked with the adjacent viable bone for optimal bone ingrowth.

The currently available forms of porous calcium phosphate implants are mechanically unsuitable for anterior or posterior spinal fusions, unstable segmental diaphyseal defects, and osteochondral defects.[18] In a metaphyseal defect such as the tibial plateau where osteochondral fragments are buttressed, a block form of porous HA or TCP actually provides better support than the standard cancellous bone chips. More mechanically demanding applications, however, await the development of composites of calcium phosphate with collagen or other materials.

Osteoinduction

There is no conclusive evidence that any of the porous calcium phosphate biomater-

The material on this page was copied from the collection of the National Library of Medicine by a third party and may be protected by U.S. Copyright law.

ials are osteoinductive. Most are considered osteoconductive, that is, allowing for bone ingrowth from an osseous bed. No bone ingrowth will occur if the implant is inserted into muscle or subcutaneous tissue. There also may be a limit to the rate and depth of bone ingrowth when they are inserted into osseous defects.

If these calcium phosphate biomaterials are to serve as more than just osteoconductive scaffolds for bone ingrowth, adjunctive osteoinductive factors must be added. Investigations studying the efficacy of collagen, osteoinductive proteins, bone marrow aspirate, and electrical stimulation in enhancing bone regeneration into porous ceramics are in progress.

SUMMARY

Autografts have consistently outperformed calcium phosphate implants in most experimental models and clinical applications. However, human trials in metaphyseal defects demonstrate comparable results with autograft, hydroxyapatite, and TCP. Diaphyseal fractures and segmental defects represent more challenging problems, with less predictable results achieved with the synthetic bone graft substitutes. Improvements in the pore configuration, mechanical properties, and osteoinductive capacity of these implants should widen their future clinical application.

REFERENCES

1. Bhaskar S, Brady J, Getter L, et al: Biodegradable ceramic implants in bone: Electron and light microscopic analysis. Oral Surg 32:336–346, 1971
2. Cameron H, MacNab I, Pilliar R: Evaluation of a biodegradable ceramic. J Biomed 11:179–186, 1977
3. Chiroff R, White E, Weber J, et al: Tissue ingrowth of replamineform implants. J Biomed Mater Res 6:29, 1975
4. Flatley T, Lynch K, Benson M: Tissue response to implants of calcium phosphate ceramic in the rabbit spine. Clin Orthop 179:246–252, 1983
5. Holmes R: Bone regeneration within a coralline hydroxyapatite implant. Plast Reconstr Surg 63:626–633, 1979
6. Holmes R, Mooney V, Bucholz R, et al: A coralline hydroxyapatite bone graft substitute: Preliminary report. Clin Orthop 188:252–262, 1984
7. Holmes R, Bucholz R, Mooney V: Porous hydroxyapatite as a bone graft substitute in metaphyseal defects: A histometric study. J Bone Joint Surg 68A:904–911, 1986
8. Holmes R, Bucholz R, Mooney V: Porous hydroxyapatite as a bone graft substitute in diaphyseal defects: A histometric study. J Orthop Res (in press)
9. Hubbard W, Hirthe W, Mueller K: Physiological calcium phosphate implants. Proc Ann Conf Engl Med Biol 15:198, 1973
10. Jarcho M: Calcium phosphate ceramics as hard tissue prosthetics. Clin Orthop 157:259–278, 1981
11. Klawitter J: A basic investigation of bone ingrowth into a porous ceramic material (doctoral thesis). Clemson University, South Carolina, 1970
12. Klawitter J, Hulbert S: Application of porous ceramics for the attachment of load bearing orthopedic applications. J Biomed Mater Res 2:161, 1971
13. Koesler K, Heide H, Konig R: Resorbable calcium phosphate ceramics under load. Langenbecks Arch Chir 343:173–181, 1977
14. Lemons J: Response of combined electrical stimulation and biodegradable ceramic: Report #1. NTIS Document AD-AO27 631, 1975
15. Nelson J, Stanford H, Cutright D: Evaluation and comparisons of biodegradable substances as osteogenic agents. Oral Surg 43:836–843, 1977
16. Roy D, Linnehan S: Hydroxyapatite formed from coral skeletal carbonate by hydrothermal exchange. Nature 247:220, 1974
17. Sartoris D, Holmes R, Bucholz R, et al: Coralline hydroxyapatite bone graft substitute in a canine metaphyseal defect model: Radiographic–histometric correlation. Invest Radiol (in press)
18. Shima T, Keller J, Alvira M, et al: Anterior cervical discectomy and interbody fusion: An experimental study using a synthetic tricalcium phosphate. J Neurosurg 51:533, 1979
19. Shimazaki K, Mooney V: Comparative study of porous hydroxyapatite and tricalcium phosphate as bone substitute. J Orthop Res 3:301–310, 1985
20. Weber J, White E: Carbonate materials as precursors to new ceramic and polymer materials for biomedical applications. Min Sci Eng 5:151, 1973
21. Winter M, Griss P, DeGroot K, et al: Comparative histocompatibility testing of seven calcium phosphate ceramics. Biomaterials 2:159–161, 1981

Division of Orthopaedic Surgery
University of Texas Health Science Center at Dallas
5323 Harry Hines Boulevard
Dallas, TX 75235

The material on this page was copied from the collection of the National Library of Medicine by a third party and may be protected by U.S. Copyright law.

Journal of Bioengineering Vol. 1, pp. 93-97

TRI-CALCIUM PHOSPHATE AS A BONE SUBSTITUTE.

Bohumil V. Rejda*, Jan G.J. Peelen+, Klaas de Groot*

*Dept. of Materials Science, Free University, Amsterdam, Netherlands.

+Philips Research Laboratories, Eindhoven, Netherlands.

(Received in Final Form 21 December 1976)

Summary

Strong porous tri-calcium phosphate ceramic has been fabricated, and investigated as a bone implant material. No foreign body reaction was observed, while osteoclastic activity was shown to be involved in biodegradation. Bone mineral was deposited directly onto the surface of the ceramic implant.

Recently, much attention has been paid to biodegradable ceramics, based on calcium phosphate salts. As shown by Karbe et al (1), Köster et al (2) and Bhaskar et al (3), sintering of salts at a CaO/P_2O_5 ratio between 2:1 and 4:1 yields biocompatible materials, the optimum ratio being 3:1 (tri-calcium phosphate). The basic drawback of these ceramics however is their low strength and therefore their clinical application is limited to non-loaded areas. The strongest material reported to date (2) can withstand pressures of several hundred kg/cm^2.

In this communication we report on a much stronger porous biodegradable ceramic based on tri-calcium phosphate which allows rapid bony ingrowth.

Method

Tri-calcium phosphate powder (particle diameter 2-3μ), obtained from Merck, was sintered according to a modified Ryshkewitch (4) procedure. Details, as well as a complete report on the physico-mechanical properties of these ceramics, will be published elsewhere. In this study tri-calcium phosphate samples with a macroporosity of 20% (Fig. 1) (pores >100 μ) and a microporosity (Fig. 2) of 30% (pores ∿1-2μ), are biologically investigated.

The material on this page was copied from the collection of the National Library of Medicine by a third party and may be protected by U.S. Copyright law.

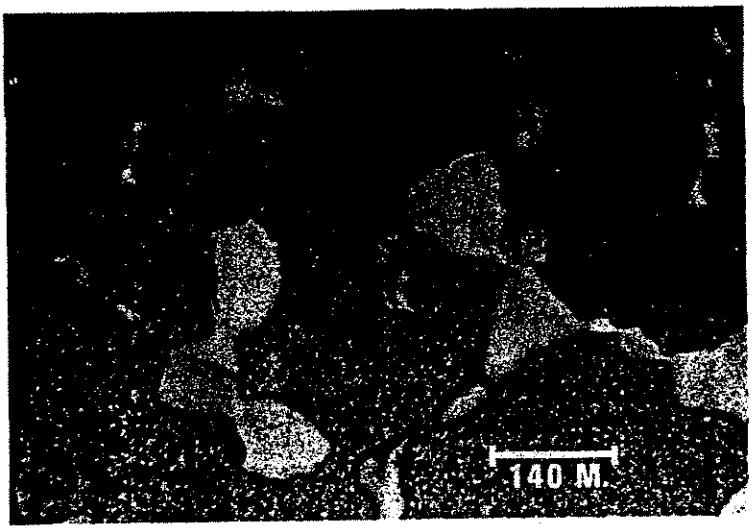

Fig. I. Light microphotograph of sintered calcium-phosphate impregnated with araldite (light areas). (1M ≡ 1μ). Macroporosity 20%, microporosity 30%.



Fig.2. SEM photograph of sintered calcium phosphate shows inside of "large" pore. Macroporosity 20%, microporosity 30%. (1 M ≡ 1 μ)

The material on this page was copied from the collection of the National Library of Medicine by a third party and may be protected by U.S. Copyright law.

As can be seen in Fig. 3, where the ultimate compressive strength is plotted versus total porosity, the compressive strength for samples with a macroporosity of 20% varies from about 2000 kgf/cm^2 (microporosity ∿ 0%) to less than 400 kgf/cm^2 (microporosity > 50%). This compares favorably with that of bony tissues (1600 kgf/cm^2 for cortical bone, 400-600 kgf/cm^2 for cancellous bone).

Cylinderlike samples (diameter 2.5 mm, length 3 mm) were implanted in holes, drilled with a dental bur, in the tibia of 2 month old rabbits. Sacrifice took place at various times up to 2 months post-implantation. The implant with surrounding tissue was then fixed in formalin, embedded in polymethylmethacrylate, and cut in undecalcified section of 5-10 μ thickness.

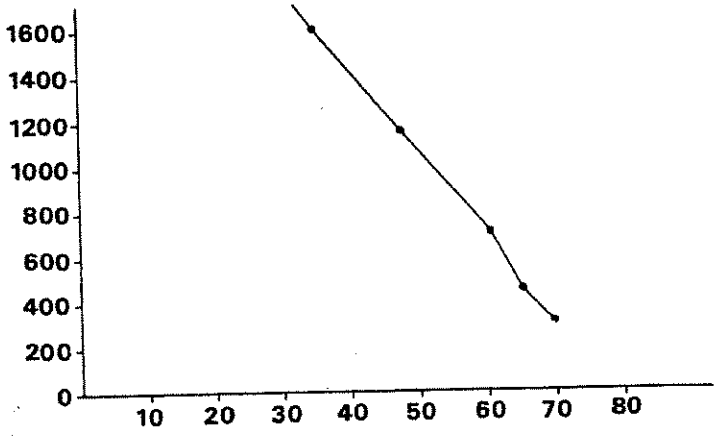

Fig. 3. Ultimate compressive strength of sintered calcium - phosphate as function of total porosity (Macroporosity in all cases 20%). Units: vertical axis: kgf/cm^2,hor; %.

Results and Discussion

Histological inspection of the sacrified animals showed that ingrowth processes in the large pores (> 100 μ) were similar to that reported by other investigators (2): bone tissue was formed directly on the interface ceramic implant-surrounding tissue, and after a certain time, ingrowth had occurred.
Köster et al (2) found this process to last several months, while we found that ingrowth was well under way after a few weeks. This difference in time is probably due to the fact that they experimented with dogs and we with young rabbits, having bone with a much larger biological activity.

After two months, a great deal of resorbtion had taken place. Fig. 4 and 5 show this in detail. Interesting to note is the absence of any foreign body reaction; no fibrous encapsulation

The material on this page was copied from the collection of the National Library of Medicine by a third party and may be protected by U.S. Copyright law.

tissue is found, and the newly found bone has been deposited directly to the ceramic implant material. A major part of the ceramic has been resorbed after two months. Fig. 5 shows in detail the interface between growing bony tissue and degrading ceramic implant: near the interface osteoblasts can be clearly seen within the ceramic pores.

Osteoblasts and other osteoclast-like multinuclear giant cells can be seen in the ceramic material, the osteoclast together with its osteon and a typical blood vessel. In this osteon, osteoblasts can also be seen clearly. (The original interface is hardly visible anymore).



Fig. 4. Overall picture of implant shows no encapsulation at interface I_1, (original interfaces implant-tissue) between newly laid bone (NB) and old bone (B). Also at interface I_2 between new bone and tri-calcium phosphate (C) no encapsulation occurs. Osteoclast-like cells (OC) can be seen, as well as osteon-like newly created pores (OS), complete with a blood vessel. Staining: azan

Thus: large pores in the ceramic (> 100µ) are gradually penetrated by osteoblasts, while osteoclasts create new space within the ceramic. This shows osteoclasts to participate actively in the biodegradation of tri-calcium phosphate sintered materials.

In conclusion:

(1) Porous tricalcium phosphate sintered ceramics can be made with the same compressive strength as bony tissues.
(2) Ingrowth occurs and osteoclasts participate in the biodegradation of these ceramics.

The material on this page was copied from the collection of the National Library of Medicine by a third party and may be protected by U.S. Copyright law.



Fig. 5. A typical area within implant. Resorbtion of tri-calcium phosphate (C) by osteoclasts (OC) and deposition of new bone (NB) can be seen, as well as osteoblasts (OB). Staining: azan (5).

References

1. E. KARBE, K. KÖSTER, H. KRAMER, H. HEIDE, G. KLING, R. KÖNIG, Langenbecks Arch. Chir., 338, 109-116 (1975).
2. K. KÖSTER, E. KARBE, H. KRAMER, H. HEIDE, R. KÖNIG, Langenbecks Arch. Chir., 341, 77-86 (1976).
3. S.N. BHASKAR, J.M. BRADY, L. GETTER, M.F. GROWER, T. DRISKELL, Oral Surg., 32, 336-346 (1971).
4. E. RYSHKEWITCH, J. Amer. Ceram. Soc., 36, 65-68 (1953).
5. B. ROMEIS, Microskopische Technik, p. 368, 16 Ed., R. Oldenburg Verlag, Munchen and Wien, (1968).

The material on this page was copied from the collection of the National Library of Medicine by a third party and may be protected by U.S. Copyright law.