Case 1:04-cv-00204-JJF Document 157-10 Filed 04/13/2005 Page 1 of 20



Fig 13. Fracture – dislocation L1 – L2 with rupture of anterior and posterior longitudinal ligament, rupture of interspinous ligaments and facet joint capsules, complete dissection of canal content and comminuted fracture of body L2 in a 57-year-old woman. In this situation no other posterior system would offer the possibility of restriction of instrumentation area to the neighboring vertebrae and simultaneous stable fixation permitting immediate mobilization of the paraplegic patient. Interbody fusion could be performed through the empty canal and resulted in quick consolidation. Thus treatment was finished 6 months after accident with implant removal resulting in unisegmental interbody fusion L1 – L2, physiologic shape of the spine and mobile lower lumbar segments. (Frankel A: no change.)

ble by an anterior approach, the described procedure is preceded by a slow external reduction: In a first step, the Schanz screws are inserted through the skin into L4 and S1 and connected by an external frame. Over a fortnight, daily distraction combined with tilting the vertical sacrum is performed. After this, the second step follows as reported above (Figure 25).

The technique is demanding and requires familiarity with this kind of deformity and with the FI instrumentation, but offers restoration of the physiologic shape of a freely mobile lumbar spine, with fusion being restricted exclusively to the lumbosacral junction.

NICAL EXPERIENCE

From December 1982 until October 1986, 183 FI instrumentations were performed at the Orthopaedic Department of the University of Basel. Ten surgeons were involved, as it is a teaching hospital. The cases have a follow-up of 6 to 52 months (mean value, 24 months). Indications for instrumentation are listed in Table 1.

Fractures

There were 84 male and 27 female patients with a mean age of 34 years (range: 15 – 76 years). Ten patients showed a second important spine fracture below D1; six times, two adjacent vertebral bodies were broken and could be stabilized by the same instrumentation: four times the fracture sites were separated by a greater distance and were instrumented by two different FI instrumentations (Table 2).

Mean kyphotic deformity in the first 50 consecutive cases before operation was 20.4°, mean residual kyphosis after instrumentation was 5.1°. Mean loss of correction in the vertebral body itself was 1°; the upper disc space, initially widened by the lordosing and distracting forces, narrows before or after implant removal, if no anterior bony bridge exists. This causes a 3 to 4° interbody kyphosis.

In one patient, no consolidation of the fracture occurred; pseudarthrosis was cured later by anterior fusion (see Complications). In all other patients, the fractures are healed.

Recovery of neurologic lesions was similar to other forms of treatment, as it depends on the primary lesion itself, the quality and time of reduction and decompression, and the absence of secondary irritation and dislocation, but is independent of the means by which decompression was achieved (Table 3).

Posttraumatic Instabilities and Deformities

There were ten male and ten female patients; mean age was 28 years (range: 17 – 54 years). In 11 patients, the fracture had been treated conservatively; in 9 patients, the initial operative treatment had failed (4 Harrington distraction instrumentations, 1 Luque segmental sublaminar wiring, 1 Locking-hook – spinal-rod instrumentation, 1 screw fixation of facet joints, and 2 interbody fusions). Indication for all FI instrumentations in this group was severe pain.

Successful intertransverse fusion was achieved in all 20 cases. Pain was relieved in 18 cases; 2 patients continue to complain of pain.

Degenerative Diseases

The seven male and nine female patients had a mean age of 57 years (range: 28 – 82 years). Position of the lower Schanz screws was nine times in the sacral bone, five times in L5 and two times in L4. All patients were fully ambulating within 1 week.

Severe Spondylolisthesis

There were 2 male and 14 female patients. Mean age was 22 years (range: 12 – 48 years). The mean anterior slip of L5 over S1 was 72%



Fig 14. 36-year-old man was referred with persistent luxation D12–L1 after extended laminectomy. Same technique and same stability of FI instrumentation. Insertion of Schanz screws in the remnants of the pedicles even easier than normally because of direct visualization. (Admission: Frankel B; follow up: Frankel C).

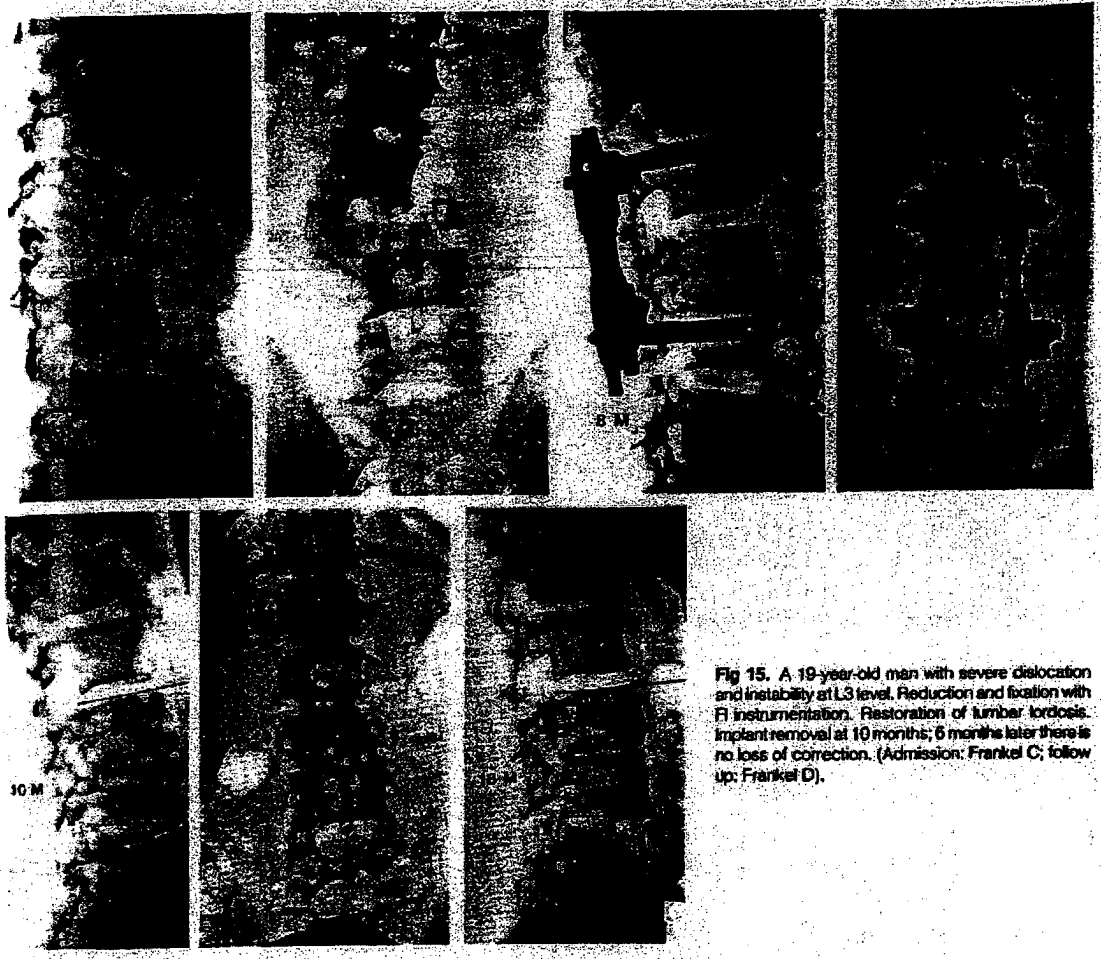

Fig 15. A 19-year-old man with severe dislocation and instability at L3 level. Reduction and fixation with Fi instrumentation. Restoration of lumbar lordosis. Implant removal at 10 months; 6 months later there is no loss of correction. (Admission: Frankel C; follow up: Frankel D).



Fig 16. Example of the transpedicular grafting of the defect in bone stock after reduction in a 27-year-old man. (Admission: Frankel C; follow up: Frankel D.)

Case 1:04-cv-00204-JJF Document 157-10 Filed 04/13/2005 Page 4 of 20

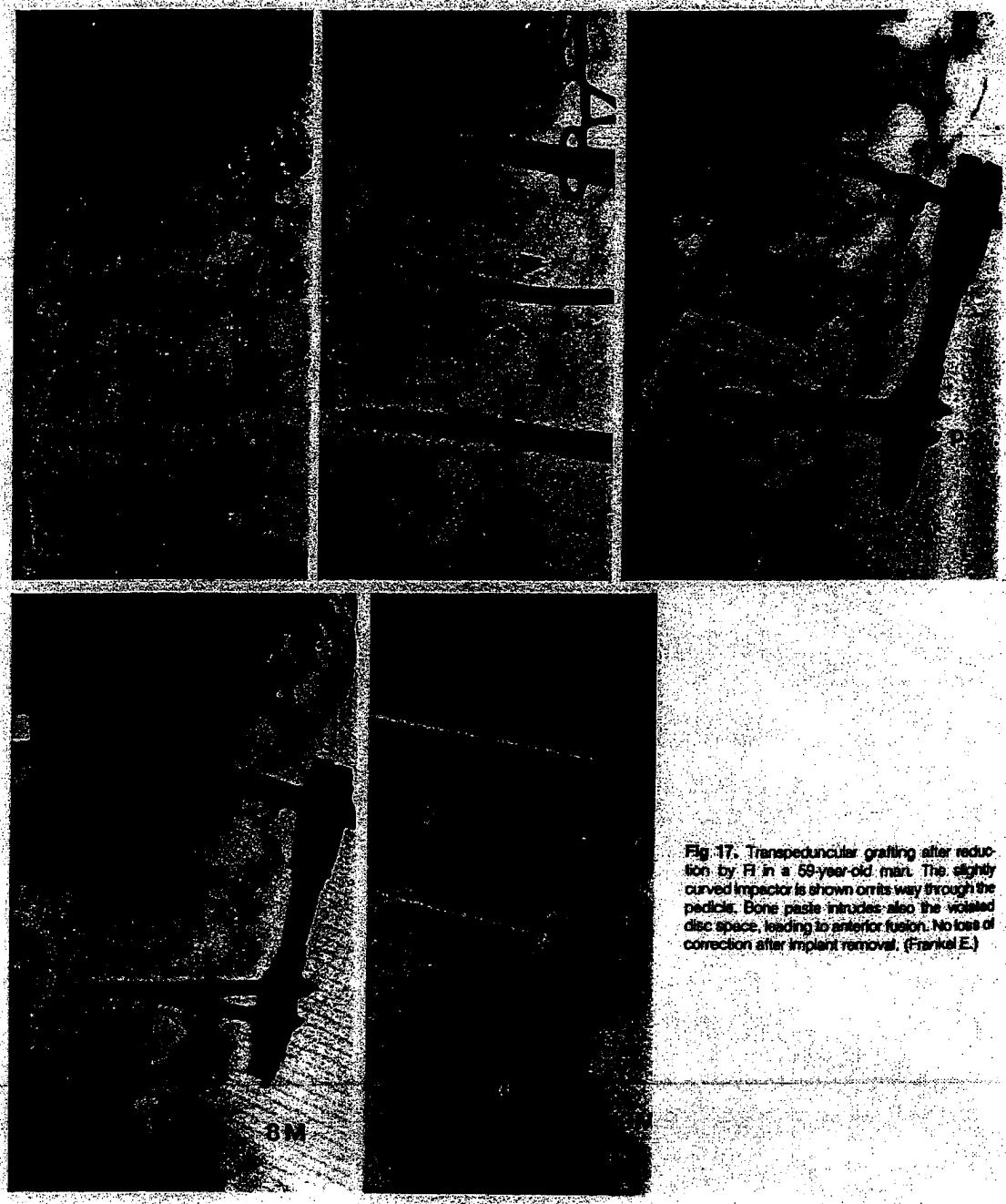

Fig. 17. Transpeduncular grafting after reduction by FI in a 59-year-old man. The slightly curved impactor is shown on its way through the pedicle. Bone paste intrudes also the voided disc space, leading to anterior fusion. No loss of correction after implant removal. (Frankel E.)



Fig 18. Unusual threefold FI instrumentation in a 25-year-old man. Because of dorsal ligamentous instability between L1 and L2 instrumentation is extended caudad to include also this level to permit early mobilization of the patient. (Admission: Frankel A; follow up: Frankel A.)



Fig 19. Reduction, fixation and transpeduncular grafting in a 25-year-old woman within 6 hours from accident without laminectomy. Myelographic control. Postoperative CT scan of L1 shows sufficient decompression. (Admission: Frankel D; follow up: Improved Frankel D.)



Fig 20. By the usual anterior opening osteotomy in this 27-year-old woman, the posttraumatic kyphosis, A, could not be corrected sufficiently, B. Additional PI instrumentation, C, made full correction and early mobilization of patient possible. (No loss of correction after implant removal, D. (Admission: Frankel D; follow up improved Frankel D.)

(range: 45–110%). Mean residual anterior slip after reduction and instrumentation was 31% (range: 1–50%). Mean correction of the vicious kyphotic position L5–S1 by lordosing manipulation of the Schanz screws in L5 and S1 reached 32° (range: 10–65°). All 14 lumbosacral interbody fusions and both posteriolateral fusions show solid bony consolidation.

Malignant Tumors

The nine male and two female patients had a mean age of 55 years (range: 36–74 years). One patient is still living 30 months after resection of a solitary plasmocytoma of L3; the other ten



Fig 22. A 69-year-old woman with severe spinal claudication. Stenosis of the canal was due not only to the degenerative spondylolisthesis L4 L5, but also to obliteration of both lateral recessus by bilaterally herniated disc material and grossly deformation of facet joints. During laminectomy and sequestrectomy both facet joints L4 and L5 had to be resected. As stiffness of the motion segment was poor due to the lack of anterior spondylotic reactions, an important instability resulted. This led to unisegmental stabilization with PI instrumentation and dorsal interbody fusion.



Fig 21. In tumor surgery longer threaded rods can be used depending on the number of vertebrae to be bridged. This 59-year-old man with metastatic disease from a carcinoma of the lung and beginning paraplegia recovered from neurologic signs, survived 9 months and was fully mobile from the seventh postoperative day until 8 months.



Fig 25. Two-stage procedure for reduction of a spondylolisthesis in an 18-year-old girl. In the first step, Schanz screws are percutaneously anchored in L4 and S1 and connected outside with two pairs of FI rods. During 10 days, slow reduction is performed. In the second step the same procedure as described in Fig. 24 follows. The upper Schanz screws are converted to L5 instead of L4. Thus an unisegmental interbody fusion with free lumbar spine, normal sacral inclination and normal lumbar lordosis results.

Table 1. Indications

Thoracolumbar and lumbar spine fractures (acute trauma)	111
Late posttraumatic corrective surgery (instability, deformity, failed other surgery)	20
Degenerative diseases and instabilities after decompressive procedures	16
Severe spondylolisthesis (Meyerding II-V)	16
Tumors	11
Malformation, spondylitis, salvage procedures	9
Total	183

Table 2. Levels of 121 Instrumented Fractures in 111 Patients

Level	*No.*	*Level*	*No.*
D4	1	L1	46
D5	1		
D6	1	L2	16
D7	2	L3	10
D8	1	L4	5
D9	3	L5	1
D10	1		
D11	6		
D12	27		

Table 3. Recovery

Group	*Preop*	*Recovery of at least 1 Frankel group at the end of rehabilitation (mean: 158 days for paraplegics)*
Frankel A	23	5
Frankel B	9	4
Frankel C	29	23
Frankel D	29	Nearly all improved; some minor residuals are found at scrutinized examination in most cases
Frankel E	21	—
Total	111	

No neurologic deterioration occurred postoperatively.

In the spondylolisthesis group, 4 of 16 patients developed numbness or motor weakness in L4 and S1 innervation with late onset (24 to 240 hours after operation). Bradford and Gotfried[8] have reported similar observations. We attribute this to the magnitude of reduction creating tension on the neurologic structures. In two patients, all signs subsided within 3 months; in two patients, recovery was incomplete, as tibialis anterior muscle force remained weak.

Four patients developed a loss of reduction: the secondary kyphosis or lateral redislocation reached between 10° and 20° at the most, twice due to lateral malposition of one Schanz screw and twice due to sinking in of the Schanz screws in the cancellous bone of porotic vertebral bodies. Consolidation in this position was accepted; no treatment was installed.

Six minor superficial wound healing disturbancies did not interfere with normal bone healing, nor with early ambulation. Implants were removed routinely in these cases at 9 months.

As the FI spans one or two elastic disc spaces, with time there may occur metal breakage even after fracture consolidation, if no intertransverse or anterior fusion has been made. At routine implant removal or last follow-up in patients without removal, screw breakage was found in seven cases in solidly healed spines without causing symptoms. In most of our cases, no intertransverse fusion was attempted in order to preserve as much mobility as possible even in the affected motion segments; only transpedicular bone grafting was performed.

DISCUSSION

The functional results of an instrumentation with short fixation area regarding spine mobility and shape are superior to those obtainable with long range fixation systems, since unnecessary fixation of additional healthy motion segments can be avoided. The simultaneous need for reliable stability can be reached in posterior instrumentation with transpedicular fixation of an angle-stable implant. The FI fulfills this requirement and offers a further advantage: the initially long ends of the Schanz screws permit the reduction of a single vertebra by direct means. Thus, the internal fixator proved to be not only a stabilizing system but also a useful tool for spine surgery. Similar devices on the same biomechanical base have been presented recently.[9,12]

The technique of instrumentation is demanding and there is a learning curve. Nevertheless its use is worth of being considered: the difference in function, the subjective reports and the ease of after-treatment in patients in whom we converted Harrington or Luque instrumentations into FI instrumentations are so striking that we have discontinued all multisegmental instrumentations in fracture treatment of the thoracolumbar and lumbar spine since 4 years.

REF
1.
2.
3.
4.
5.
6.
7.
8.
9.
10.
11.
12.
13.
14.
15.
16.
17.
18.
19.
20
21
22
23
24

Case 1:04-cv-00204-JJF Document 157-10 Filed 04/13/2005 Page 8 of 20

REFERENCES

1. Akbarnia BA, Fogarty JP, Tayob AA: Contoured Harrington instrumentation in the treatment of unstable spinal fractures: The effect of supplementary sublaminar wires. Clin Orthop 189:186–194, 1984
2. Arnold W: Operative Frühbehandlung mit dem Fixateur externe bei traumatischer Querschnittslähmung. Beitr Orthop Traumatol 32:6–14, 1985
3. Bedbrook GM: Spinal injuries with tetraplegia and paraplegia. J Bone Joint Surg 61B:267–284, 1979
4. Bohlman HH: Treatment of fractures and dislocations of the thoracic and lumbar spine. J Bone Joint Surg 67A:165–169, 1985
5. Bohlman HH, Cook SS: One-stage decompression and posterolateral and interbody fusion for lumbosacral spondylopathosis through a posterior approach. J Bone Joint Surg 64A:415–418, 1982
6. Boxall D, Bradford DS, Winter RB, Moe JH: Management of severe spondylolisthesis in children and adolescents. J Bone Joint Surg 61A:479–495, 1979
7. Bradford DS, Akbarnia BA, Winter B, Seljeskog EL: Surgical stabilization of fracture dislocations of the thoracic spine. Spine 2:185–196, 1977
8. Bradford DS, Gotfried Y: Staged salvage reconstruction of grade-IV and V spondylolisthesis. J Bone Joint Surg 69A:191–202, 1987
9. Camarr AE, Kaufman AA: A survey of the neurological results of 858 spinal cord injuries: A comparison of patients treated with and without laminectomy. J Neurosurg 13:95–106, 1956
10. Daniaux H: Technik und erste Ergebnisse der transpedikulären Spongiosaplastik bei Kompressionsbrüchen im Lendenwirbelsäulenbereich. Acta Chir Austriaca (Suppl) 43:79, 1982
11. Denis F: Spinal instability as defined by the three-column spine concept in acute spinal trauma. Clin Orthop 189:65–76, 1984
12. Dewald RL, Faut MM, Taddonio RF, Neuwirth MG: Severe lumbo-sacral spondylolisthesis in adolescents and children. J Bone Joint Surg 63A:619–626, 1981
13. Dick W: Innere Fixation von Brust- und Lendenwirbelbrüchen. Second edition. Bern–Stuttgart–Toronto, Hans Huber, 1987
14. Dick W: Osteosynthese schwerer Verletzungen der Brustund Lendenwirbelsäule mit dem Fixateur interne. Langen bocks Arch Chir 364:343–346, 1984
15. Dick W: Use of the acetabular reamer to harvest autogenic bone graft material: A simple method for producing bone paste. Arch Orthop Trauma Surg 105:235–238, 1986
16. Dick W, Kluger P, Magerl F, Woersdörfer O, Zäch G: A new device for internal fixation of thoracolumbar and lumbar spine fractures: the "Fixateur interne". Paraplegia 23:225–232, 1985
17. Dick W, Morscher E: Therapiekonzept für die Spondylolisthesis, Neuroorthopädie 4. Edited by D Hohmann, B Kügelgen, K Liebig. Heidelberg–New York–Tokyo, Springer (In press)
18. Dick W, Wörsdörfer O, Magerl F: Mechanical properties of a new device for internal fixation of spine fractures, The "Fixateur interne". Vol 2, Developments in Biomechanics. Edited by SM Perren, E Schneider, M Nijhoff. The Hague, 1985, pp 501–506
19. Dickson JH, Harrington PR, Erwin WD: Results of reduction and stabilization of the severely fractured thoracic and lumbar spine. J Bone Joint Surg 60A:799–805, 1978
20. Dunn HK: Anterior stabilization of thoracolumbar injuries. Clin Orthop 189:116–124, 1984
21. Ferguson RL: The evolution of segmental spinal instrumentation in the treatment of unstable thoracolumbar spine fractures. J Pediat Orthop 3:124, 1983
22. Flesh JR, Leider LL, Erickson DL, Chou SN, Bradford DS: Harrington instrumentation and spine fusion for unstable fractures and fracture–dislocations of the thoracic and lumbar spine. J Bone Joint Surg 59A:143–153, 1977
23. Frankel HL, Hancock DO, Hyslop G, et al: The value of postural reduction in the initial management of closed injuries of the spine with paraplegia and tetraplegia. Paraplegia 7:179–192, 1969
24. Frederickson BE, Baker D, McHolick WJ, Yuan HA, Lubicky JP: The natural history of spondylolysis and spondylolisthesis. J Bone Joint Surg 66A:699–707, 1984
25. Gaines RW, Breedlove RF, Munson G: Stabilization of thoracic and thoracolumbar fracture–dislocations with Harrington rods and sublaminar wires. Clin Orthop 189:195–203, 1984
26. Gertzbein SD, Macmichael D, Tile M: Harrington instrumentation as a method of fixation in fractures of the spine: A critical analysis of deficiencies. J Bone Joint Surg 64B:526–529, 1982
27. Harms J, Stolze D, Graas M: Operative Behandlung der Spondylolisthese durch dorsale Reposition und ventrale Fusion. Orthop Praxis 12:996–1001, 1985
28. Harrington PR: Instrumentation in spine instability other than scoliosis. S Afr J Surg 5:7–12, 1967
29. Harrington PR, Dickson JH: Spinal instrumentation in the treatment of severe progressive spondylolisthesis. Clin Orthop 117:157–163, 1976
30. Hasday CA, Passoff TL, Perry J: Gait abnormalities arising from iatrogenic loss of lumbar lordosis secondary to Harrington instrumentation in lumbar fractures. Spine 8:501–511, 1983
31. Holdsworth, FW: Fractures, dislocations and fracture–dislocations of the spine. J Bone Joint Surg 52A:1534–1551, 1970
32. Holm S, Nachemson A: Nutritional changes in the canine intervertebral disc after spinal fusion. Clin Orthop 169:243–258, 1982
33. Jacobs RR, Casey M: Surgical management of thoracolumbar spinal injuries. Clin Orthop 189:22–35, 1984
34. Jacobs RR, Dahners LE, Gertzbein SD, Nordwell A, Mathys R: A locking hook–spinal rod: Current status of development. Paraplegia 21:197–200, 1983
35. Jacobs RR, Nordwall A, Nachemson AL: Reduction, stability and strength provided by internal fixation systems for thoracolumbar spinal injuries. Clin Orthop 171:300–308, 1982
36. Kahanovitz N, Arnoczky SP, Levine DB, Otis JP: The effects of internal fixation on the articular cartilage of unfused canine facet joint cartilage. Spine 9:268–272, 1984
37. Kahanovitz N, Bullough P, Jacobs RR: The effect of internal fixation without arthrodesis on human facet joint cartilage. Clin Orthop 189:204–208, 1984
38. Kaneda K, Abumi K, Fujiya M: Burst fractures with neurologic deficits of the thoracolumbar–lumbar spine. Results of anterior decompression and stabilization with anterior instrumentation. Spine 9:788–795, 1984
39. Kempf I, Issa JB, Briot B, Grosse A, Jaeger JH, Lemaguet A, Delangre C: Traitement chirurgical des fractures instables du rachis dorso-lombaire par matériel de Harrington. Acta Orthop Belg 46:289–309, 1980
40. Kluger P, Gerner HJ: Das mechanische Prinzip des Fixateur externe zur dorsalen Stabilisierung der Brustund Lendenwirbelsäule. Unfallchirurgie 12:68–79, 1986
41. Kostuik JP: Anterior fixation for fractures of the thoracic and lumbar spine with or without neurologic involvement. Clin Orthop 189:103–115, 1984
42. Krag MH, Beynnon BD, Pope MH, Frymoyer JW, Haugh LD, Weaver DL: An internal fixator for posterior application to short segments of the thoracic, lumbar or lumbosacral spine. Design and testing. Clin Orthop 203:75–98, 1986
43. Lewis J, McKibbin B: The treatment of unstable fracture–dislocations of the thoraco-lumbar spine accompanied by paraplegia. J Bone Joint Surg 56B:603–612, 1974
44. Louis R: Chirurgie du rachis. Anatomie chirurgicale et voies d'abord. Berlin–Heidelberg–New York, Springer, 1982.
45. Louis R, Maresca C: Stabilisation chirurgicale avec réduction des spondylolysis et des spondylolisthesis. Int Orthop 1:215–225, 1977
46. Luque ER: Segmental spinal instrumentation of the lumbar spine. Clin Orthop 203:126–134, 1986
47. Luque ER, Cassis N, Ramirez-Wiella G: Segmental spinal instrumentation in the treatment of fractures of the thoraco-lumbar spine. Spine 7:312–317, 1982
48. McAfee PC, Bohlman HH: Complications following Harrington instrumentation for fractures of the thoraco-lumbar spine. J Bone Joint Surg 67A:672–686, 1985
49. McAfee PC, Bohlman HH, Yuan HA: Anterior decompression of traumatic thoracolumbar fractures with incomplete neurological deficit using a retroperitoneal approach. J Bone Joint Surg 67A:89–104, 1985
50. McAfee PC, Yuan HA, Fredrickson BE, Lubicky JP: The value of com-

puted tomography in thoraco-lumbar fractures. J Bone Joint Surg 65A:461–473, 1983
51. Magerl F: Clinical application on the thoracolumbar junction and the lumbar spine with a fixateur externe. External Skeletal Fixation. Edited by DC Mears. Baltimore, Williams & Wilkins, 1981, pp 353–366
52. Magerl F: External skeletal fixation of the lower thoracic and the lumbar spine. Current Concepts of External Fixation of Fractures. Edited by HK Uhthoff. Berlin–Heidelberg–New York, Springer, 1982, pp 353–366
53. Magerl F, Orthopedic Clinic, Kantonsspital St. Gallen (Switzerland), unpublished data, 1982
54. Morscher E: Zweizeitige Reposition und Stabilisation der Spondylioptose mit dem Harrington-Instrumentarium und vorderer interkorporeller Spondylodese. Arch Orthop Unfall-Chir 83:323–334, 1975
55. Nagel DA, Koogle TA, Piziali RL, Perkash IC: Stability of the upper lumbar spine following progressive disruptions and the application of individual internal and external fixation devices. J Bone Joint Surg 63A:62–70, 1981
56. Osebold WR, Weinstein SL, Sprague BL: Thoracolumbar spine fractures: results of treatment. Spine 6:13–34, 1981
57. Purcell GA, Markolf KL, Dawson EG: Twelfth thoracic–first lumbar vertebral mechanical stability of fractures after Harrington rod instrumentation. J Bone Joint Surg 63A:71–78, 1981
58. Roy-Camille R, Saillant G, Berteaux D, Salgado V: Osteosynthesis of thoracolumbar spine fractures with metal plates screwed through the vertebral pedicles. Reconstr Surg Traumatol 15:2–16, 1976
59. Roy-Camille R, Saillant G, Mazel C: Internal fixation of the lumbar spine with pedicle screw plating. Clin Orthop 203:7–17, 1986
60. Saillant G: Etude anatomique des pédicules vertebraux. Application chirurgicale. Rev Chir Orthop 62:151–160, 1976
61. Schläpfer F, Wörsdörfer O, Magerl F, Perren SM: Stabilization of the lower thoracic and lumbar spine: comparative in vitro investigation of an external skeletal and various internal fixation devices. Current Concepts of External Fixation of Fractures. Edited by HK Uhthoff. Berlin–Heidelberg–New York, Springer, 1982, pp 367–380
62. Schöllner D: Ein neues Verfahren zur Reposition und Fixation bei Spondylolisthesis. Orthop Praxis 11:270–274, 1975
63. Sijbrandij S: A new technique for the reduction and stabilization of severe spondylolisthesis: A report of two cases. J Bone Joint Surg 63B:266–271, 1981
64. Stauffer ES: Current concepts review: Internal fixation of fractures of the thoracolumbar spine. J Bone Joint Surg 66A:1136–1138, 1984
65. Stauffer ES, Neil JL: Biomechanical analysis of structural stability of internal fixation in fractures of the thoracolumbar spine. Clin Orthop 112:159–164, 1975
66. Vellkas EP, Blackburne JS: Surgical treatment of spondylolisthesis in children and adolescents. J Bone Joint Surg 63B:67–70, 1981
67. Wasylenko M, Skinner SR, Perry J, Antonelli DJ: An analysis of posture and gait following spinal fusion with Harrington instrumentation. Spine 8:840–845, 1983
68. Wenger DR, Carollo JJ, Wilkerson JA, Wauters K, Herring JA: Laboratory testing of segmental spinal instrumentation versus traditional Harrington instrumentation for scoliosis treatment. Spine 7:265–273, 1982
69. White III AA, Panjabi MM: Clinical Biomechanics of the Spine. Philadelphia, J.B. Lippincott, 1978
70. White III AA, Panjabi MM, Thomas CL: The clinical biomechanics of kyphotic deformities. Clin Orthop 128:8–17, 1977
71. Whitesides TE, Shah SGA: On the management of unstable fractures of the thoracolumbar spine: Rationale for use of anterior decompression and fusion and posterior stabilization. Spine 1:99–107, 1976
72. Wiltse LL, Winter RB: Terminology and measurement of spondylolisthesis. J Bone Joint Surg 65A:768–772, 1983

Address reprint requests to

Dr. W. Dick
Orthop. Univ.-Klinik
Felix Platter-Spital
CH-4000 Basel
Switzerland

Accepted for publication May 11, 1987.

A-17

Acta orthop. scand. 47, 686–689, 1976

OPEN REDUCTION OF CENTRAL COMPRESSION FRACTURES OF THE TIBIAL PLATEAU

Preliminary Report of a New Method and Device Arrangement

H. G. EDELAND

Department of Orthopaedic Surgery, Central Hospital, Mölndal, Sweden.

A new method of reduction and fixation of a uniformly depressed fracture of the tibial condyle is described. A curved steel probe, introduced through a cortical window in the uninjured condyle, is used to reduce the fracture fragments as well as to compact the fracture region (TV-monitored x-ray projectioning is desired). The instruments needed for the operative procedure are as follows: a probe for reduction and compaction, a tube and a plunger for deposition of bone transplants, and a forked plate. Five cases in which the curved probe reduction method has been used are reported.

Key words: ceramic material; fixation; fractures; tibial condylar fractures

Accepted 13.ix.76

A fracture of one of the condyles of the tibia is not an uncommon injury, more often occurring laterally than medially, and mostly in the elderly osteoporotic patient (Rasmussen 1973). The uniformly depressed central condylar fracture with an intact cortical rim (Hohl Type I B) represents 26 per cent of the entire tibial condylar fracture group (Hohl 1967). Several of these fractures will benefit from the method of treatment outlined below.

In a forced valgus position of the knee, the lateral femoral condyle is wedged down upon the corresponding tibial condyle. In this way, the femoral condyle depresses and compresses the central parts of the tibial plateau thus fracturing the surface in a mosaic-like manner but often sparing the outer border of the condyle and the meniscus (Kennedy et al. 1968). (Figure 1.)

As stressed by several authors (Hohl 1967, Maquet et al. 1967, Rasmussen 1973), the fracture deformity produced by a central fracture of one of the tibial condyles, can only be tolerated for a short time, and it can only, to a limited extent, be compensated biomechanically by fibrous callus.

PATIENTS

Five patients have been operated on according to the method outlined below. In four patients the lateral condyle was fractured, in the fifth the medial condyle. In all cases the central compressions amounted to or exceeded one cm and the knee was unstable in the extended position. Three patients were women, two men. All patients were more than 55 years old. In

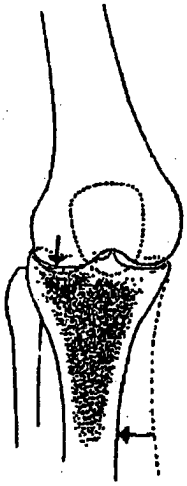

Figure 1. Forced valgus position of the knee, causing a central depression of the lateral tibial plateau.



Figure 2. Two probes, with different curvatures.

one patient the fracture region was stabilized by two loops of wire, from the lateral to the medial side of the tibial condyle. Autologous bone transplantation was performed in two patients.

METHODS

The aim of the method described below is to re-establish in a simple way the all-important support of the femoral condyle and consequently the stability of the knee joint. This will prevent an otherwise unavoidable joint insufficiency due to increased load, with the forces converging on limited parts of the tibial condyle, resulting in gradually increasing strains on the ligaments.

The method requires a curved steel probe which has a diameter of 1.0–1.5 cm, a length of 20 cm, and a radius of the curve of approximately 25 cm. The "reduction end" of the probe is slightly concave. The instrument, with various curvatures, is illustrated in Figure 2.

The probe is introduced into the bone via a fenestration in the subcondylar cortex of the unfractured side of the tibial head, so that the probe will not affect the supporting cortical parts of the fractured condyle. The concave "reduction end" of the probe is placed in position beneath the compressed parts of the condyle, under TV-monitored x-ray control. The compressed fracture region is reduced by repeated careful pushes of the probe (Figure 3). On its way, the probe transfers and compacts considerable amounts of cancellous bone from the region beneath the depression. The curvature of the probe permits some "swing" and this makes some minor adjustments of the reduction possible and also compacts and forms transverse bone bridges immediately beneath the fracture parts. This stabilizes the reduced fracture parts. The reduction may, if necessary, be further stabilized by several methods of internal fixation, e.g., by a wire technique, described by Gottfries et al. (1971), or by a plate device especially designed for this purpose (Figure 4). Only a short skin incision is needed for the reduction procedure. The surgery should be performed with the fractured leg slightly extended. The pre-operative set-up is illustrated in Figure 5. A full-length circular knee-cast should be used for 4 to 6 weeks post-operatively in order to keep the fractured knee joint compartment protected.

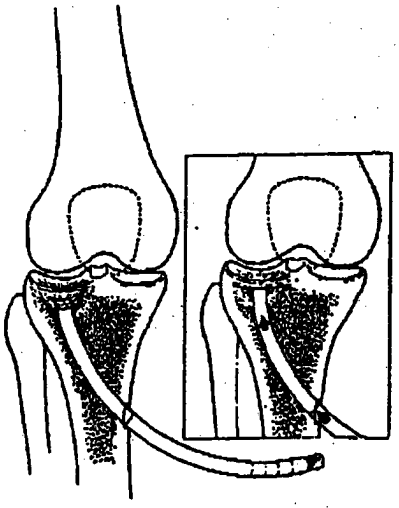

Figure 3. Principle of the fracture reduction and compaction procedure with a curved probe.

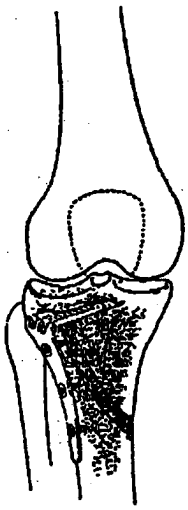

Figure 4. Outline of the support plate, applied to a reduced condylar fracture region, with bone grafts and/or ceramic material filling the bone defects.

RESULTS

All patients were followed up for at least six months, three for more than a year. A satisfactory joint function with an active flexion capacity of up to 90 degrees and with full or almost full extension capacity was noted in all cases.

A post-operative depression of 5 to 10 mm of the reduced area occurred in one case. This re-dislocation occurred within the first two months after surgery. Due to subjectively incapacitating valgus instability of the knee, this patient uses a walking stick and a short knee brace.



Figure 5. The per-operative set-up, with the C-bow x-ray apparatus in position for an A-P central beam projection of the knee joint space. This necessitates a free-hanging extremity, which should be slightly extended. Note that the probe is put into the slide of metaphysis contralateral to the fractured condyle.

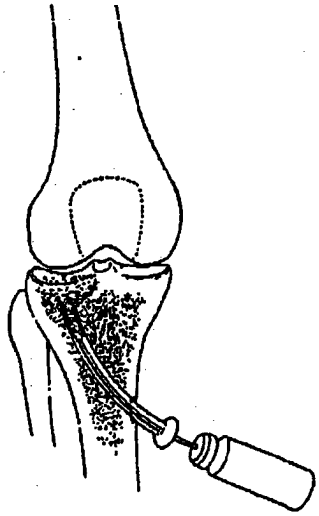

Figure 6. Principle of the use of the bone graft and/or ceramic "loaded" tube-and-plunger instrument set-up.

All patients had sagittal stability. Two patients (one mentioned above) had some valgus instability. All patients were able to use stairs. No-one was troubled by night pains. One patient had permanent joint swelling. There have been no infections or serious general complications, such as venous thrombosis or pulmonary embolism.

DISCUSSION

The method described is probably only suitable for the treatment of uniformly depressed central condylar fractures. The alternative to the selected method would have implied a wider approach to the fracture area. This would have decreased the support of the fracture region even if bone grafts had been used. This standard method usually includes visual control of the reduction through an arthrotomy. Meniscectomy would probably have been performed in order to facilitate the reduction of the fracture fragments, even if the meniscus was not ruptured primarily. It is suggested that by using the above method, arthrotomy, bone grafting, and meniscectomy could be avoided.

Instead of bone grafts to compensate for the bone defects, porous ceramic material could be used as suggested by Benum et al. (1976) and Cameron et al. (1976). The ceramic material (e.g. tricalcium phosphate) could be introduced into the bone defect region by the use of a cylinder-and-piston type of instrument arrangement, as shown in Figure 6.

ACKNOWLEDGEMENT

The drawings were made by Fredrik Johansson, Göteborg, Sweden.

REFERENCES

Benum, P., Lyng, Bø O., Rafn, I. & Hoffner, J. D. W. (1976) Porous ceramics as a bone substitute in the medial condyle of the tibia. *Acta orthop. scand.* 47, 158–166.

Cameron, H. U., McNab, I. & Pilliar, R. M. (1976) Evaluation of a bio-degradable ceramic. Abstract, Program, 1976 Meeting, *American Society of Biomaterials*, p. 82.

Gollfries, A., Hagert, C.-G. & Sörensen, S. E. (1971) T- and Y-fractures of the tibial condyle. A follow-up study of cases treated by closed reduction and surgical fixation with a wire loop. *Injury* 3,1, 56–62.

Hohl, M. (1957) Tibial condylar fractures. *J. Bone Jt Surg.* 49-A, 1455–1467.

Kennedy, J. C. & Bailey, W. H. (1968) Experimental tibial-plateau fractures. Studies of the mechanism and a classification. *J. Bone Jt Surg.* 50-A, 1522–1534.

Maquet, P., Simonet, J. & de Marchin, P. (1967) Biomécanique du genou et gonarthrose. *Rev. Chir. orthop.* 53, 111–138.

Rasmussen, P. S. (1973) Tibial condylar fractures. Impairment of knee joint stability as an indication for surgical treatment. *J. Bone Jt Surg.* 55-A, 1331–1350.

Correspondence to: H. G. Edeland, M.D., Department of Orthopaedic Surgery, Central Hospital, S-431 22 Mölndal, Sweden.

A-18

NOTICE
THIS MATERIAL MAY BE PROTECTED
BY COPYRIGHT LAW (TITLE 17, U.S. CODE)

Fractures of the Tibial Condyles

A Preliminary Report on Supplementary Fixation With Methylmethacrylate

WILLIAM R. KENNEDY, M.D.*

Severely displaced fractures of the tibial condyles present a difficult problem in management. Surgical reconstruction of a significantly disrupted joint surface has been advocated by many authors,[4,6-12] however the technical problems associated with open reduction and internal fixation have frequently led to poor reductions, loss of fixation, and in turn, disappointing postoperative results.

A significantly depressed tibial condylar fracture in the osteoporotic elderly patient provides a most difficult problem for which many techniques have been developed. Bolts, screws, plates, tibial, iliac and patellar bone grafts plus combinations of the preceding have all been described in the literature and used with varying degrees of success. Since 1973 we have used methylmethacrylate in conjunction with metallic devices to treat these fractures. The following is the report based on 7 cases with follow-up ranging from 20 to 51 months.

CLASSIFICATION

For this review the modified classification system of Apley[1] described by Roberts[10] was used to classify which type of tibial condyle fractures were suitable for this method of treatment. All of the cases in this report were Type III displaced fractures, however a Type II fracture with significant displacement and instability would be an excellent candidate for this method of fixation if open reduction was elected to be used. Also, all of the cases in this report were lateral condyle fractures (Fig. 1).

MATERIALS AND METHODS

Surgical repair of the fracture was carried out under general anesthesia within 4 days of the date of injury. None of the cases were operated on as an emergency procedure. The routine was to follow admission with a medical evaluation and surgery to be performed on the second day of hospitalization. Upon admission to the hospital, the leg was placed in a splint, which was removed only for frequent Betadine® scrubs. Preoperative and postoperative antibiotics were given routinely.

The proximal tibia at the fracture site was exposed by a long lateral incision as described by Barr.[2] The capsule was incised 1 cm lateral to the patella and the joint was inspected. Removal of the lateral meniscus was usually necessary in order to provide maximal exposure of the joint surface. The capsular incision was continued distally over the lateral tibial condyle to the insertion of the iliotibial band. In 2 cases, the iliotibial band had avulsed a fragment of bone from the site of its attachment into the tibia.

Using a periosteal elevator the proximal origin of the anterior tibial muscle was elevated from the tibia hinging it on its posterior attachments. Care was taken to protect the anterior tibial artery and deep peroneal nerve as they pass under

* Suite 230, Medical Arts Building, Sarasota, Florida 33579.

Received: September 20, 1977.

0009-921X/78/0700/0153/$00.75 © J. B. Lippincott Company

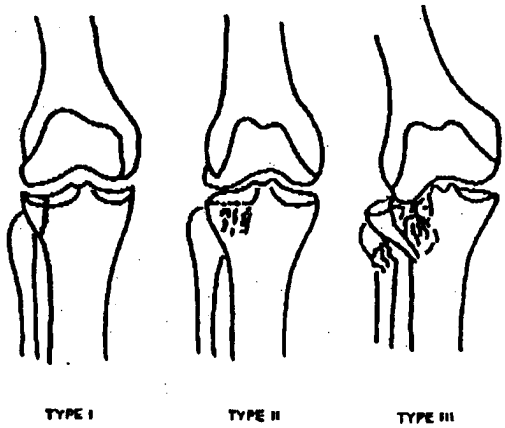

FIG. 1. The tibial plateau fracture classification of A. G. Apley modified by J. M. Roberts[10] is shown. Type I, nondisplaced. Type II, local compression of the lateral tibial plateau. Type III, displaced fracture of the tibial condyle with instability of the knee.



FIG. 2. The depression of the lateral tibial condyle is shown with an intact peripheral shell of tibial cortex.

the cover of the anterior tibial muscle. The bone exposed on the anterior tibia provided a site in which to fashion a window through which the depressed segments of the joint surface could be visualized and manipulated.

Through the window in the tibia, a blunt instrument could be inserted and used to push up the depressed bone fragments. By visualizing the interior of the joint through the capsular incision anatomical reduction was carried out. However, once the articular fragments had been put into their proper place an obvious cavity was present in the subarticular bone. The crushed cancellous bone beneath the articular surface usually left a space which we elected to fill with methylmethacrylate rather than a bone graft.

In the Type III fractures, a transverse fixation device was usually necessary. We used an ASIF cancellous screw in 6 cases but a bolt or other device could also be used. The surgeon must be aware that the methylmethacrylate filling the cavity has little strength in holding the split fragments together and its purpose is to maintain the articular fragments in their elevated position, thus providing support for the compressed articular surface. At the time of surgery, the methylmethacrylate filling the cavity beneath the articular surface provided some stability to the "split" or peripheral fragments, however lateral–medial fixation must also be used if early motion is to be instituted.

Once the methylmethacrylate had hardened the joint was then flexed and extended. At the time of surgery all of the repairs were felt to be stable enough to allow motion postoperatively and it was not necessary to cast any of our cases postoperatively until 90° of flexion had been achieved. The anterior tibial muscle was reattached anteriorly to its previous position covering the window in the tibia now filled with methylmethacrylate. Hemovac® tubes were usually inserted into the joint prior to closure and the leg was placed in a Jones compression bandage. Roentgenograms were taken in the surgical suite (Figs. 2–4).

POSTOPERATIVE CARE

After 48 hours the Hemovac® tubes were removed and on the third day following surgery the Jones bandage was removed. The leg was then carefully placed in a Thomas splint with a Pearson foot attachment. By means of pulleys and hand controls passive range of motion exercises were begun with the assistance of a registered physical therapist. When 90° of passive flexion had been accomplished with consistency

the leg was placed in a cylinder cast with the knee flexed 30°. A nonweight bearing gait was taught and the patient was allowed to ambulate.

RESULTS

The criteria used by Roberts[10] was adopted to rate our results. An acceptable result showed 90° of flexion from full extension, good strength and endurance for the patient's age, a normal gait pattern, good ligamentous stability and no more than mild intermittent symptoms after unusual exertion. If any one of these criteria was not fulfilled the result was rated not acceptable. Results were based only on the clinical evaluation (Table 1).

Six of our 7 cases achieved an acceptable result with a minimum follow-up of 21 months. Our one unacceptable result was a 71-year-old housewife who suffered 2 severe complications which compromised her result. Four days postoperatively she developed an acute anterior myocardial infarction. However, 26 days postoperatively she had gained a range of motion measuring 0–100°. She still did not fulfill our criteria for an acceptable result since strength was lacking. Three months after surgery she fell entering her mobile home and reinjured her knee necessitating another surgical procedure. This subsequent injury was not a result of failure of the methylmethacrylate.

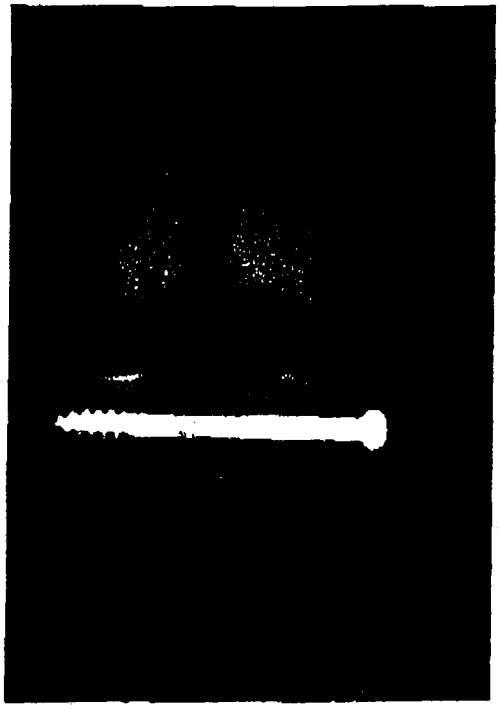

FIG. 3. Surgical elevation of the lateral tibial condyle has been secured with a screw. However, a residual space remains to be filled beneath the elevated condyle.

We have not noted any specific effects of the methylmethacrylate on the bone or joint surfaces. There has been no roentgenological evidence of necrosis of the articular sur-

TABLE 1.

Patient	*Age/Sex*	*Date of Injury*	*Postop Range of Motion*	*Complications*	*Rating*
E.H.*	49/F	5/20/73	0–130°	Myocardial infarction refracture lateral tibial condyle	Not Acceptable
G.M.	74/F	5/19/74	0–130°		Acceptable
E.M.*	74/F	10/17/74	5–100°		Acceptable
M.H.	20/F	10/24/74	0–130°		Acceptable
M.G.	90/M	12/ 9/74	0–130°		Acceptable
H.M.	70/F	5/29/75	5–120°		Acceptable
J.B.**	63/F	12/11/75	0–90°		Acceptable

* Case of Charles E. Boring, M.D.

** Case of Alfred P. Seminario, M.D.

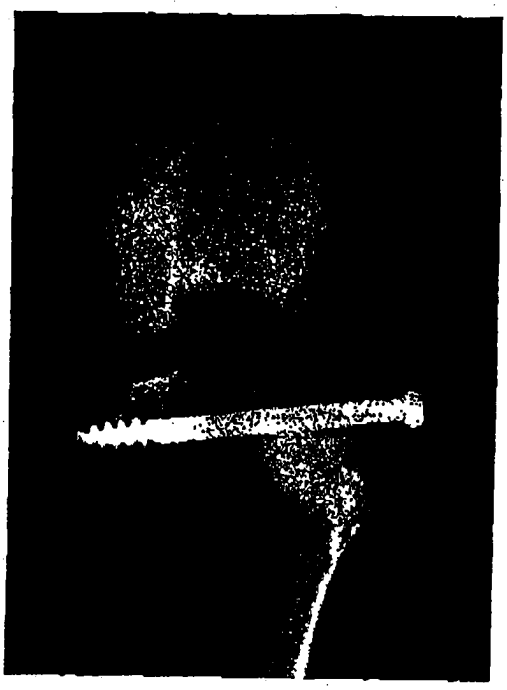

FIG. 4. The void is now filled with methylmethacrylate.

face bone in the repaired tibia nor has there been any specific sign of bone resorption. These findings were also noted by Harrington[3] in his study of intertrochanteric hip fractures using methylmethacrylate as an adjunct to fixation.

DISCUSSION

In the elderly a valgus producing force directed at the knee frequently produces a lateral tibial condyle fracture. The extent of damage to the joint surface is frequently more extensive than can be appreciated on the roentgenograms. In the Type III fractures, the significant displacement of the articular surface if left to heal in its displaced position can leave the knee joint unstable. The 7 such cases presented in this series were treated with open reduction and internal fixation using methylmethacrylate in conjunction with metallic devices.

Many authors have emphasized the importance of early mobilization of the knee joint following this injury.[1,4,5,7] In our experience open reduction with internal fixation has frequently yielded an excellent reduction of the fracture. However, the rigidity of the fixation may not be sufficient to allow the joint to be actively or even passively exercised in the immediate postoperative period. Furthermore, once mobilization of the knee was instituted the reduction obtained at surgery has been on occasion lost because of the fragility of the shell of the proximal tibial cortex.

In 1967, Dr. William Cassebaum and I recognized this problem and sought to improve the fixation then used for tibial condyle fractures by the addition of methylmethacrylate. Only cadaver surgery was performed at that time. Since then further experience with the use of methylmethacrylate in treating Type III tibial condylar fractures has confirmed the usefulness of the method.

SUMMARY

In severely displaced fractures of the tibial condyles, failure of the method of fixation may lead to disappointing results of open reduction operations. This problem may be successfully and safely treated by using methylmethacrylate (MMC) for internal fixation. In this series 6 of 7 cases achieved an acceptable result of fixation with MMC. This compares favorably to published series of fractures of this type treated by open reduction.

REFERENCES

1. Apley, A. G.: Fractures of the lateral tibial condyle treated by skeletal traction and early mobilization. A review of sixty cases with special references to the long-term results, J. Bone Joint Surg. 38B:699, 1956.
2. Barr, J. S.: The treatment of fracture of the external tibial condyle (bumper fracture), JAMA 115:1683, 1940.
3. Harrington, K. D. : The use of methylmethacry-

late as an adjunct in the internal fixation of unstable comminuted intercrochanteric fractures in osteoporotic patients, J. Bone Joint Surg. 57A:744, 1975.

4. Hohl, M. and Luck, J. V.: Fracture of the tibial condyle, a clinical and experimental study, J. Bone Joint Surg. 38A:1001, 1956.
5. Hohl, M.: Tibial condylar fractures, J. Bone Joint Surg. 49A:1455, 1967.
6. Lechner, C. W. and Hand, F. M.: Fractures of the tibial plateau, J. Bone Joint Surg. 22:559, 1940.
7. Neal, E. G.: General principles in the management of the joints, Surg. Clin. North Am. 41:1607, 1961.
8. Palmer, I.: Compression fractures of the lateral tibial condyles and their treatment, J. Bone Joint Surg. 21:674, 1939.
9. ———: Fractures of the upper end of the tibia, J. Bone Joint Surg. 33B:160, 1951.
10. Roberts, J. M.: Fractures of the condyles of the tibia, J. Bone Joint Surg. 50A:1505, 1968.
11. Rombold, C. : Depressed fractures of the tibial plateau. Treatment with rigid internal fixation and early mobilization. A preliminary report, J. Bone Joint Surg. 42A:783, 1960.
12. Von Bahr, V.: Depressed and comminuted fractures of the lateral tibial tuberosity, Acta Chir. Scand. 92:139, 1945.