A-15

Arch Orthop Trauma Surg (1986) 105:235–238

Archives of Orthopaedic and Traumatic Surgery

© Springer-Verlag 1986

Use of the Acetabular Reamer to Harvest Autogeneic Bone Graft Material: A Simple Method for Producing Bone Paste

NOTICE
THIS MATERIAL MAY BE PROTECTED
BY COPYRIGHT LAW (TITLE 17, U.S. CODE)

W. Dick

Department of Orthopaedic Surgery, University of Basel, Switzerland

Summary. In comparision with solid bone grafts, the particulate form as a paste-like material offers several advantages. The method reported for harvesting a homogeneous mixture of ground cortical and cancellous bone has proven to be simple, time-saving, and productive. A normal acetabular reamer is used to procure the graft from the outer surface of the posterior iliac wing, transforming it simultaneously into paste-like material.

Bone grafting procedures are gaining increasing importance in orthopedic surgery. The use of bone graft material in the form of solid pieces of different sizes has been accepted practice for decades. More recently, bone paste consisting of small bone particles and blood has been used for craniofacial reconstructive surgery [4, 6].

In comparison with solid bone grafts, the particulate form as a paste-like material offers several advantages:

1. The surface of the graft is multiplied, and vascularization and remodeling of bone are thereby facilitated.
2. The healing that occurs in the bone graft area is a "field phenomenon" occurring simultaneously throughout the entire defect [4, 6].
3. Ingrowth of capillaries is not slowed by the previously necessary resorption of transplanted bone, as clefts give access everywhere.



Fig. 1a–c. Reconstruction of a vertebral body by filling the anterior defect transpedicularly with bone paste by a posterior approach. Stabilization of fracture by "fixateur interne". Result after removal of the implant 7 months later

Offprint requests to: W. Dick, M.D., Orthopädische Universitäts-Klinik, Felix-Platter-Spital, Burgfeldstr. 101, CH-4012 Basel, Switzerland

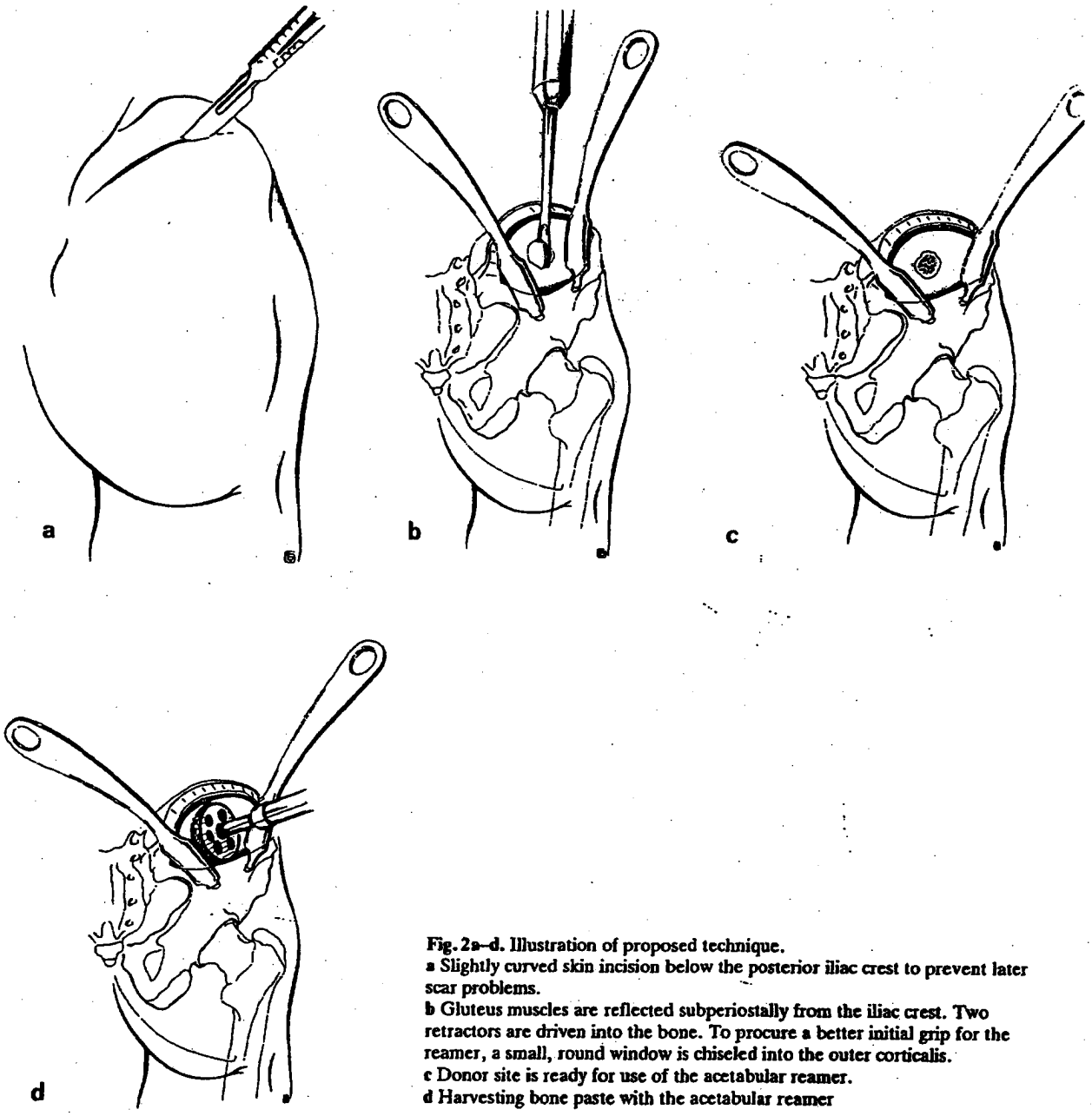

Fig. 2a–d. Illustration of proposed technique.
a Slightly curved skin incision below the posterior iliac crest to prevent later scar problems.
b Gluteus muscles are reflected subperiostally from the iliac crest. Two retractors are driven into the bone. To procure a better initial grip for the reamer, a small, round window is chiseled into the outer corticalis.
c Donor site is ready for use of the acetabular reamer.
d Harvesting bone paste with the acetabular reamer

4. Irregularly shaped defects can be filled more completely. The contact between host site and graft is closer and more extensive than with solid bone chips.
5. The position of two bone fragments to be united can still be corrected after grafting without dislocation of the graft.
6. Only a small access is necessary to fill a large cavity: for example, according to Daniaux [2], a transpedicular canal of 6 mm in diameter is sufficient to fill a traumatic defect in a vertebral body from a posterior approach (Fig. 1).

There is evidence that ground compact bone is incorporated more quickly than solid cancellous bone grafts and that bone induction is better [1, 5, 7–12].

The method for collecting a homogeneous mixture of ground cortical and cancellous autogeneic bone reported here has proven to be very simple, time saving, and productive (Fig. 2): from a curved incision along the posterior iliac crest the posterior



Fig. 3. a Posterolateral spinal fusion in a 35-year-old patient.
b 4 weeks after operation a well-shaped fusion mass between the transverse process of L-4 and L-5 is visible



Fig. 4. a Harvesting autogeneic bone in a 13-year-old female scoliosis patient. A 50-mm acetabular reamer is used.
b The reamer is withdrawn. The Synthes reamers offer the advantage that the bone particles are collected inside the cup of the reamer.
c Two to three times this amount of mixed cortical and cancellous bone particles can be gained

iliac wing and iliac spine are prepared subperiostally. The gluteus muscles are reflected with two retractors. A normal acetabular reamer (50 mm in diameter) is then used to procure the graft and transform it simultaneously into a paste-like material. To procure a better initial grip for the reamer a small opening is chiseled into the cortical layer. This is not necessary if a reamer with a centering pin is used initially.

The outer wing of the ilium and the cancellous table are reamed; the inner wing is preserved. By pulling the reamer sideways in all directions a lot of bone can be gained. With a few milliliters of blood from the donor site the graft takes on a pasty consistency. Bleeding at the donor site is controlled by collagen hemostatic felt. The acetabular reamer is much quicker and cheaper than a bone mill.

Our good experience with the bone paste in spinal surgery [3] and the technique of harvesting it with the reamer used since 1983 has led us to use it wherever autogeneic bone grafting is needed without pressure resistance, e.g.,

- In direct anterior repair of spinal fractures to fill up the defect in the vertebral bodies transpedicularly according to Daniaux [2]
- In posterolateral spinal fusion for degenerative spine disorders (Fig. 3)
- In scoliosis surgery (Fig. 4)
- In spondylitis and osteomyelitis
- In leg lengthening procedures
- In tibial head and other impression fractures
- In resections of bone tumors
- In operations for pseudarthrosis
- In reconstructions for loss of bone stock in revision arthroplasties (THR) combined with cementless prostheses.

Where pressure resistance is needed, the autogeneic bone paste can be combined with a homogeneic strut graft.

Acknowledgement. The author is indebted to Dr. B. Gerber for the drawings in Fig. 1.

References

1. Chalmers J, Gray D, Rush J (1975) Observations on the induction of bone in soft tissues. J Bone Joint Surg [Br] 57:36
2. Daniaux H (1982) Technik und erste Ergebnisse der transpedikulären Spongiosaplastik bei Kompressionsbrüchen im Lendenwirbelsäulenbereich. Acta Chir Austriaca [Suppl] 43:79
3. Dick W (1986) The "fixateur interne" (FI) – a versatile implant for spine surgery. Spine (in press)
4. Habal M, Leake D, Maniscalco J (1978) Repair of major cranio-orbital defects with an elastomer-coated mesh and autogenous bone paste. Plast Reconstr Surg 61:394
5. Kuner EH (1984) Über die Marknagelung der Tibiaschaftfraktur. Orthopäde 13:266–270
6. Mulliken J, Glowacki J (1980) Osteogenesis for repair and reconstruction in the craniofacial region. Plast Reconstr Surg 65:553
7. Oikarinen J, Korhonen K (1981) The bone inductive capacity of various bone transplanting materials used for the treatment of experimental bone defects. Clin Orthop 140:208
8. Rudzki M, Burri C, Hutschenreuter P (1976) Der Ein- und Umbau von autologer Spongiosa und Compacta im ersatzschwachen Knochenlager. Langenbecks Arch Chir [Suppl]:263–266
9. Schöttle H, Jungbluth KH, Sauer HD, Schöntag H (1978) Weichteilverknöcherungen nach stabilen Osteosynthesen durch Knochenbohrmehl. Chirurg 49:49–53
10. Urist MR, Dowell TA, Hay PH, Strates BS (1968) Inductive substrates for bone formation. Clin Orthop 59:59–96
11. Urist MR (1980) Fundamental and clinical bone physiology. Lippincott, Philadelphia
12. Velasco RU, Habal MB, Spiegel PG, Lotz M, Leake DL (1983) A study of autologous cancellous bone particles in long bone discontinuity defects. Clin Orthop 177:264–273

A-16

The "Fixatuer Interne" as a Versatile Implant for Spine Surgery

W. Dick

The "fixateur interne" is a new device for posterior spine surgery. It consists of long Schanz screws which are inserted from a posterior approach through the pedicles into the vertebral bodies, and of connecting threaded longitudinal rods, carrying mobile clamps which can be fixed in every position by nuts. The long leverarms of the Schanz screws facilitate manual reduction. They are removed at the end of operation. As the device is stable against flexion and rotation by itself, it does not act on the four-point bending principle. Thus, the fixation can be restricted to the immediately adjacent vertebrae of a lesion, leaving the rest of the spine mobile. In fracture treatment instrumentation is combined with a direct repair of the anterior loss of bone stock by a transpedicular bone grafting procedure from the same dorsal approach. This report presents and discusses 183 instrumentations in fresh fractures, posttraumatic deformities, degenerative diseases, tumors, and severe spondylolistheses. The main advantage is the short fixation area and the ease of after treatment. [Key words: "fixateur interne," posterior spine surgery, pedicle fixation, spinal fracture, spinal deformity]

THE COMMON POSTERIOR instrumentations for surgery on thoracic and lumbar spine such as Harrington,[1,7,19,22,23,28,36,57] Jacobs,[33–35] Luque rods,[21,46,47] or dorsal Roy-Camille plates[58,59] are based on a four-point fixation[60,70]; a two-point fixation on both sides of the afflicted area. On each side they have a mobile link to one vertebra and need a second bony support on the lamina of the next vertebra. This means that generally at least five vertebrae, two above and two below, are included in the fixation. For fracture treatment, Jacobs even recommends a three-above, three-below technique for better stability.[33–35]

It is commonly accepted that scoliosis patients with their previously stiff spine tolerate well iatrogenic loss of mobility. However, that principle does not apply to other patients with previously mobile spines. Simultaneous iatrogenic loss of mobility and of lumbar lordosis worsens the impairment.[30,67] Patients without neurologic defects can develop mechanisms of compensation; for paraplegics, however, a stiff thoracolumbar or lumbar spine causes rehabilitation problems.[3]

Even restricting the bony fusion to the afflicted area and removing the implant after consolidation often does not solve the problem because the mobility of the temporarily instrumented part of the spine is not always restored. Extraarticular bridging of an untouched facet joint leads to degeneration of the cartilage.[32,36,37] Therefore a long-range immobilization of intact joints of the thoracolumbar or lumbar spine cannot be the final solution in spine surgery; on the extremities, similar procedures never would be accepted. Furthermore, direct adjustment of the position of one particular vertebra is not possible with any four-point bending system. Shifting of a vertebra or reduction of vertebral fragments can be done only by indirect means and corrective forces can be applied at most in one or two directions. The common posterior instrumentations work excentrically from the center of rotation on the dorsal elements and tend, when distracted, to produce an unwanted kyphotic tilt to the instrumented end vertebrae.

In unstable fractures,[11,21] sometimes stability is not good enough to allow early mobilization of the patient. Slipped hooks and loss of correction are reported complications.[26,40,48]

Magerl was the first to introduce 1977 another biomechanical principle when he connected long percutaneous Schanz screws anchored dorsally and transpedicularly into the vertebral bodies with a stable external frame.[51,52] This "fixateur externe" made it possible to leave the four-point fixation and to shorten the instrumented area to three vertebrae.[2] Following Magerl's ideas and suggestions,[53] a fully implantable and stable spine fixation device was developed at Basle University Orthopaedic Department, which is called "fixateur interne" (FI) instrumentation.[13,14,16]

THE IMPLANT

The implant consists of Schanz screws of 5 mm diameter for transpedicular fixation in the vertebrae, and threaded longitudinal rods of 7 mm diameter to connect the Schanz screws (Figure 1). The rods carry clamps which are first mobile in every direction and permit application of forces to produce kyphosis, lordosis, distraction, compression, and rotation. Finally they can be fixed by nuts in the desired configuration. A system of flattened sides on the threaded rods, nonturning washers, grooves and bars secures a firm hold of the position of the Schanz screws relative to each other, including rotational stability (Figure 2). As long as the clamps stay firm, no redislocation will occur.

When testing the FI system,[13,18] mounted to free polyethylene blocks, with an anterior bending moment up to 70 Nm, no giving way of the clamps occurred. The approximation of the tips of the Schanz screws under load was 2.5 mm with a bending moment of 18.5 Nm; 3.4 mm with 25 Nm; 4.6 mm with 35 Nm; 5.4 mm with 42.[illegible] Nm, and 8.6 mm with 70 Nm. No residual deformation was found after loading and unloading up to 40 Nm of anterior bending moment. With 70 Nm, a plastic deformation of the FI of 0.3 mm remained after unloading.

Further testing was carried out on seven human cadaver spines in comparison to Harrington rods, Jacobs rods, Roy-Camille plates, and an external fixator. The spines were mounted to a universal

From the Division of Orthopaedic Surgery, Department of Surgery, University of Basel, Basel, Switzerland, and the Swiss Paraplegic Center, Basel, Switzerland.

Submitted for publication June 21, 1985, and revised December 15, 1986.



. "Fixateur interne."



2. Technical details of the implant.

testing machine (Rumul Mikroton 654) and submitted to a pure anterior bending moment. Two inductive goniometers (Schaevitz RVDT R 30A) were fixed to the immediately adjacent vertebral bodies and the angulation deformity was measured. Testing included the intact spine, the spine with an experimental combined lesion of the anterior and posterior elements, and the fractured spine after instrumentation with the different fixing devices.

Mean angulation deformation for the FI with an anterior bending moment of 5 Nm was 1°, with 10 Nm 2.9°, with 15 Nm 6.1° and with 20 Nm 6.6°. In two spines with about 12 Nm, there was observed a slow giving away of the cancellous bone around the Schanz screws, leading to elevated angulation (mean age of all specimens, 78 years). For comparison: Harrington distraction rods disengaged[33,41,45,46] in the same model regularly with 6–10 Nm bending moment. No loosening of a clamp occurred. Figure 3 shows the relation to the other fixing devices in the same experimental set up.

One patient with a severe lumbar fracture with combined anterior and posterior disruption died of pulmonary embolism 17 days after FI instrumentation. His spine was tested in the same way: angulation deformation reached 0.9° with 10 Nm anterior bending moment; 1.1° with 15 Nm; 1.4° with 20 Nm and 2.4° with 47 Nm. No loosening occurred and no residual deformation after unloading was found. After removal of the FI rods the spine was disruptured completely when anterior bending moment reached 9 Nm (Figure 4).

OPERATIVE TECHNIQUE

By the usual midline posterior approach, the laminae and facet joints are prepared open and the transverse processes localized. With some experience the points of entry for the Schanz screws dorsally can be found easily. They are located slightly more laterally than those described for dorsal plating by Roy-Camille et al.,[38] Saillant,[40] and Louis and Maresca.[44] Figure 5 shows the relationship to the transverse processes and the facet joints. In the lumbar spine, the point of entry is found level to the middle of the transverse

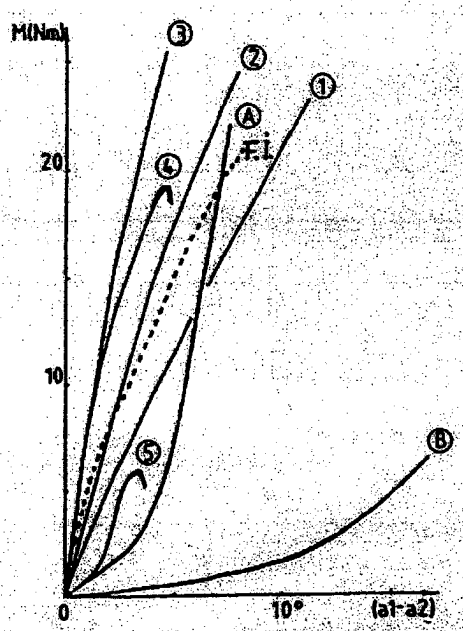

Fig 3. Anterior bending moment in Nm vertically, kyphotic angulation deformation in degrees horizontally A, intact spine. B, experimental combined anterior and posterior lesion. 1 = Fixateur externe without prestressing; 2 = Fixateur externe with prestressing; 3 = posterior plate fixation; 4 = Locking hook spinal rod system; 5 = Harrington distraction instrumentation. Dotted line: Fixateur interne.

process as far laterally as the lateral border of the upper articular process. In the thoracic spine, the entry point is located immediately below the upper facet joint approximately 3 mm lateral to the middle of the joint near to the base of the transverse process. Therefore, it is recommendable at thoracic levels to remove the transverse process with a bone nibbler.

After localization of the entry points, 2-mm K-wires are inserted parallel to the end plates and convergent 10–15° towards the midline through the pedicles into the vertebral bodies (Figure 6) for a depth of 3 cm (except in S1, which is considerably smaller). After roentgenogram control, the K-wires are replaced by the self-tapping Schanz screws. It is only necessary to open up just the point of entry with a 3.5 mm drill bit for a depth of 5–10 mm. No tapping is done. The Schanz screws are driven manually into the vertebral bodies until their tip lies close to the anterior wall. In an average patient, it is safe to insert the Schanz screws to about 40 mm (to the sacrum, 30 mm). From then on, image intensifier control is mandatory during insertion, as the anterior wall is thin and offers little resistance. Involuntary perforation cannot be felt.

As the Schanz screws are lying within the closed corticalis of the pedicles, they do no harm to the neural structures and achieve firm purchase in the bone.[12] They are connected with the FI rods lying towards the middle in the groove along the spinous processes (Figure 7). Now, forces in every direction can be brought upon the Schanz screws as needed for the individual case. This may be illustrated schematically for a burst fracture (Figure 8): first, the kyphosis is corrected by compressing forcefully the free dorsal ends of the Schanz screws towards each other. In cases where the posterior wall of the vertebral body has been destroyed, first the distraction nuts are brought near to the clamps to prevent the posterior wall from further dislocation, leaving free space of 3 mm per 10° kyphosis correction between nut and clamp.[12] By squeezing together the ends, the tips of the Schanz screws are spread apart and thus the desired lordosis is achieved. Then the angle between the Schanz screws is fixed by the lateral nuts and reduction is completed by distraction with the nuts on the threaded rod until the anatomic height of the vertebral body is restored. After tightening the connecting nuts, the dorsally protruding parts of the Schanz screws are removed; a special bolt cutter cuts them off smoothly and without a sharp edge. The nuts are secured against loosening by compressing their border into the flattenings of the threaded rods. Wound closure poses no problems.

Of course, by reversed manners, compressive and kyphosing forces can also be applied. The same is true for rotational corrections. The FI instrumentation yields stability in all directions except parallel lateral dislocation of the instrumented vertebrae, which is normally prevented by the bony dorsal elements. In cases with severe lateral instability cross-linking of the FI rods is recommended.

As soon as consolidation of the fracture and the transpedicular graft is assured, routine implant removal is recommended as at least one mobile disc space is bridged and no posterior fusion is done generally. Tumor cases are of course excepted. Depending on roentgenographic follow-up, implant removal will be possible usually after 9 to 12 months postoperatively, in some cases even earlier.

The different combinations of the possibilities for correction make the FI instrumentation adaptable to both trauma and corrective orthopaedic spine surgery.

THORACOLUMBAR AND LUMBAR FRACTURES

In operative treatment of thoracolumbar and lumbar spine fractures, the FI instrumentation offers several advantages.

Restricted Fixation Area

The biomechanical principle of the FI, relying on an angle-stable connection of firmly anchored Schanz screws, permits the instrumentation to be restricted just to the vertebrae immediately adjacent to the fracture, avoiding the inclusion of two or three levels above and below; only two motion segments are immobilized (Figure 9), and in pure dislocations even one (Figure 10).

Thus little iatrogenic loss of mobility is ensured. This is important especially for the rehabilitation of paraplegic patients[1,20] where independence depends on extensive lumbar spine mobility: 1) to reach the feet, especially if there is not good sitting balance or if hip joint mobility is restricted as in osteoarthritis or paraarticular ossification; 2) to reach the ground sitting in the wheelchair; 3) to get back into the wheelchair without help after a fall; 4) for standing exercises where hyperlordosis of the lumbar spine is needed (often patients with long stiff areas relate pain when standing); 5) for walking exercises to swing through the splinted lower extremities with the oblique abdominal muscles. Also nonparaplegic patients report a substantial subjective gain of mobility when long rod instrumentations are replaced by the FI (Figure 11).

Anatomical Reduction

The second advantage of the FI besides its shortness are the long handles and lever arms of the Schanz screws facilitating the anatomic reduction of the fracture. The continuous threads on the rods instead of the discontinuous ratchet steps of the Harrington distraction rods permit establishing the exact amount of tension desired (Figure 12).

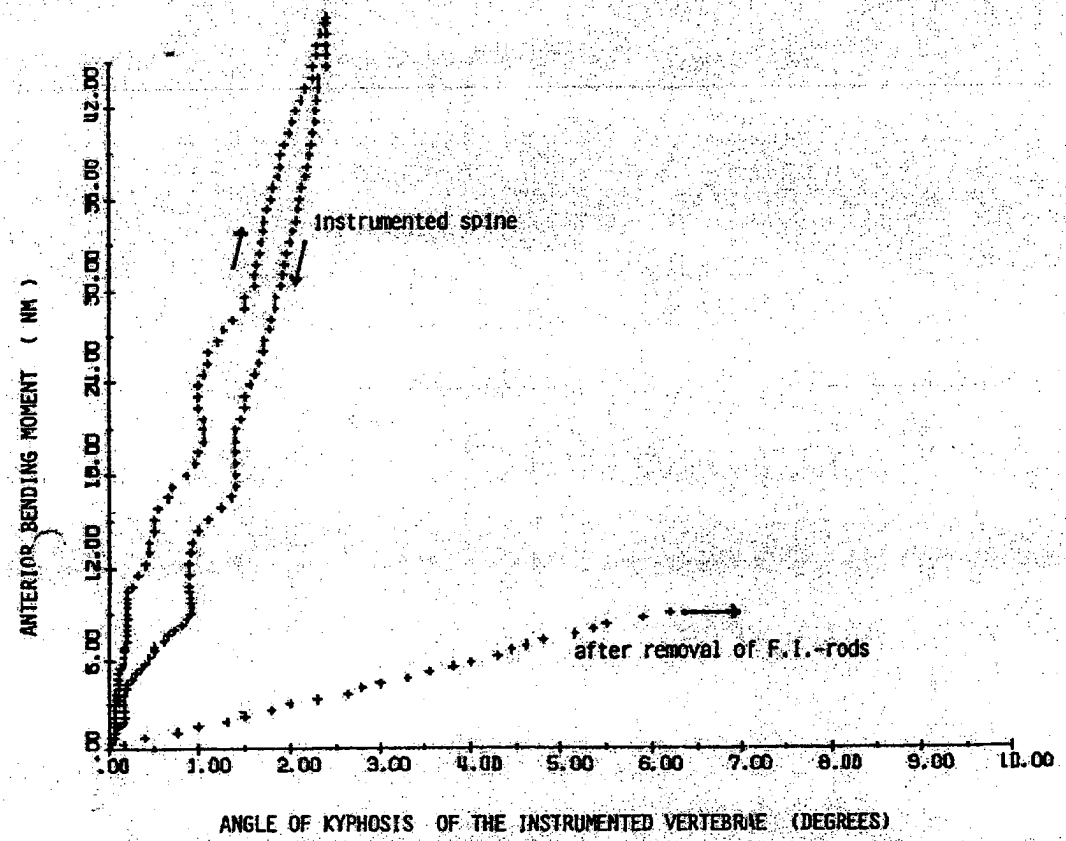

4. The instrumented spine of a 44-year-old male patient with severe fracture–dislocation of L1, who died on the 17th day (embolism), was submitted to anterior bending moment. The angle of kyphosis between D12 and L2 was measured. The pure elastic deformation was 2.4 degrees under load of 47.5 Nm. After removal of the FI rods complete disruption of the specimen occurred at 9 Nm.

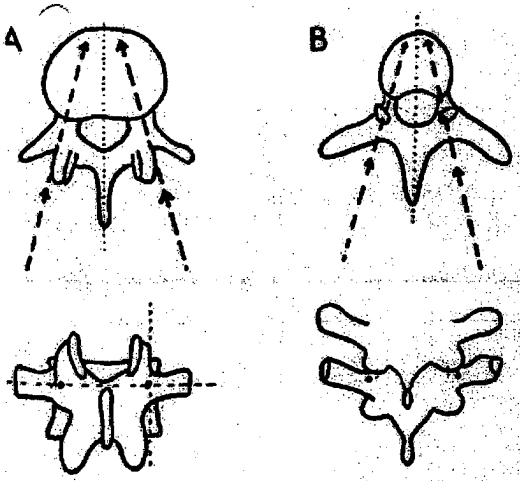

5. Points of entry for the Schanz screws on A, lumbar and B, thoracic vertebrae.

Independence from Type of Lesion

FI instrumentation can be applied as well in simple wedge-compression fractures as in incomplete and complete burst fractures, Chance fractures, rotational slice fractures, fracture-dislocations, and pure dislocations. Its biomechanical function makes it independent of intact longitudinal ligaments or of the condition of the posterior elements and of the posterior wall (Figure 13). Even after a previous wide laminectomy (which is only rarely indicated[3,44] but not uncommonly found in referred patients), the lack of posterior elements does not influence the way of application (Figure 14): the same two-segmental positioning of the Schanz screws is even easier to perform because the remnants of the pedicles can be visualized directly beside the dura. In such cases a posterolateral fusion of the instrumented area is done at the same time. The device is removed after 12 to 15 months in these patients.

Lack of Iatrogenic Loss of Lumbar Lordosis

Lordosis or kyphosis can be selected freely. Furthermore the kyphotic tilt of the instrumented end vertebrae, which we find with

Case 1:04-cv-00204-JJF Document 157-9 Filed 04/13/2005 Page 11 of 15



Fig 6. The Schanz screws are driven through the pedicles into the vertebral bodies.

all distraction rods even if they are square-ended and bent into lordosis, is avoided (Figure 15).

Easy Removal

In case of complications or implant removal after fracture healing, the posterior approach makes reinterventions easy in contrast to anterior procedures. The implant is removed by unscrewing the Schanz screws grasped on their overstanding part with a special forceps. The lateral nuts can be unlocked in spite of their compressed border.

Solid Fixation

The pedicle is the strongest part of a vertebra and, like all transpedicular screws, the Schanz screws get a very firm anchorage. Patients without neurologic impairment can ambulate 3 to 5 days postoperatively; paraplegic patients are allowed to sit in the wheelchair after 1 or 2 weeks. Most patients receive a light-weighted brace of the Jewett-type for 8 weeks; no full plaster or plastic jacket is used. Where the FI instrumentation has a pure tension-band function with dorsal compression (chance fractures, pure luxations, "fracture–dislocation en cartier d'orange"[9]), no external support at all may be used.

Special Considerations

Because of the high bending forces acting on the short part of the Schanz screws outside the pedicle in reduced wedge–compression or burst fractures, attention has to be paid to the loss of bone stock anteriorly to avoid fatigue fractures of the Schanz screws. Therefore, a direct anterior repair simultaneously with the FI instrumentation from the same posterior approach is strongly recommended. One or both pedicles of the fractured vertebra are opened up with a 6-mm drill bit, as Dunaux[10] has described (Figure 16). Through this canal, the defect in the vertebral body can be filled with small pieces of autologous cancellous bone using a funnel and a slightly curved impactor (Figure 17). The funnel must reach the vertebral body itself to protect the canal from intrusion of bone graft particles through potential lesions of the pedicle. Another way of access to



Fig 7. The Schanz screws are connected with the threaded FI rods lying towards the middle. Finally the overstanding ends are cut.

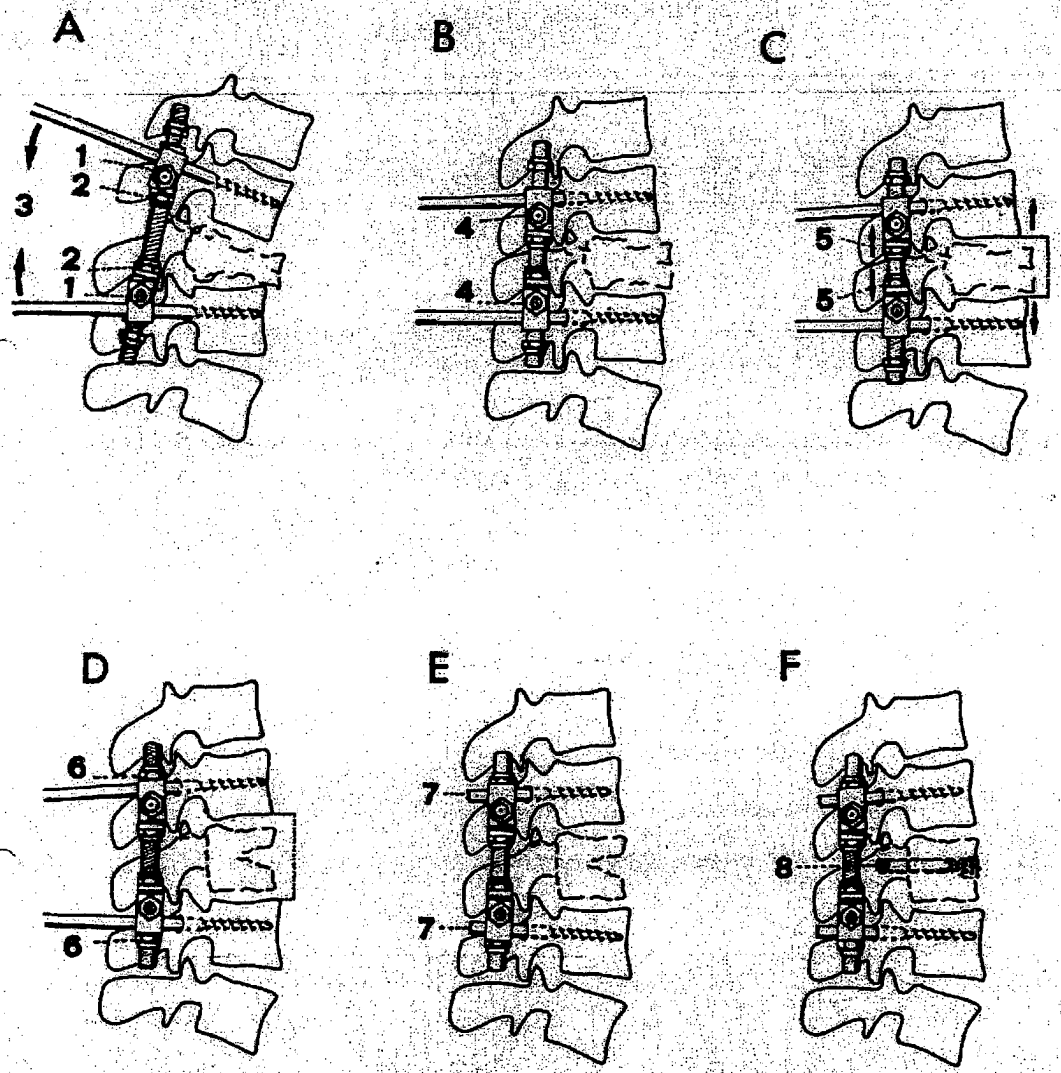

Fig 8. FI instrumentation of a burst fracture. **A,** reduce kyphotic deformity by squeezing together the dorsal ends of the Schanz screws (3); the lateral nuts (1) are loose; the distraction nuts (2) may be positioned near to the clamps to protect the posterior wall from further compression. **B,** Tighten the lateral nuts (4), thus lordosis is fixed. **C,** Restore vertebral height by the distraction nuts (5). Lordosis will not be altered. **D,** Tighten the countemuts (6), thus rotation is controlled. **E,** Cut the overstanding ends of Schanz screws (7). **F,** Fill up the defect anteriorly in the fractured vertebra with autologous bone paste by transpeduncular approach according to Deriaux.[10]



Fig 9. CT scans of a 36-year-old man after implant removal proves the correct positioning of the Schanz screws in both vertebrae. (Admission: Frankel D, follow-up: improved Frankel D).



Fig 10. In cases such as this 25-year-old man with mainly discoligamentous lesions, posterolateral fusion is necessary. Sometimes unisegmental FI instrumentations can be realized. (Frankel A, no change).

the defect zone in the vertebral body from behind is lateral to the pedicle through an osteotomy of the base of the transverse process in the lumbar spine according to Arnold.[2] The necessary amount of bone to fill the defect is surprisingly high. The simplest and quickest way in our experience is to procure the bone graft with an acetabular reamer from the posterior iliac spine by a separate incision along the posterior iliac crest. This gives a homogeneous paste-like mixture of cortical and cancellous bone,[15] which probably means the best biological graft material. Of course, also a bone mill can be used.

A quick and solid bony healing anteriorly is the best protection for the implant and makes a posterior fusion unnecessary. Therefore, the transpedicular grafting is only omitted where there is no anterior bone defect zone like in dislocation–fractures with nearly pure discoligamentous lesions (Figure 10). Chance fractures or some rotational slice fractures. Posterolateral fusion to bridge the injured segment is needed only in the discoligamentous lesions.

FI instrumentation can be applied from the eighth thoracic vertebra to the sacrum, covering therefore the most frequent sites of spine fractures. Higher up the pedicles often are too small for the 5-mm Schanz screws, but in the upper and midthoracic spine indications for operative treatment are rare, and the disadvantages of long-rod instrumentations or dorsal plates are less important than in the thoracolumbar and lumbar spine. Yet, under one exceptional circumstance, FI instrumentation was performed up to D4, when complete destruction of posterior elements and a visible disruption of the cord was found.

The versatility of the implant also permits unusual instrumentations like threefold fixation (Figure 18), unisegmental or trisegmental instrumentation, or two separate instrumentations in combined lumbar and thoracic lesions.

Compression of the canal contents due to luxation or kyphotic angulation is removed by the simple reduction of the fracture. Also in burst fractures with compression due to dislocated posterior wall fragments, the ideal anatomic reduction and sufficient distraction often lead to restoration of the canal diameter by ligamentotaxis, provided the operation is performed within the first 5 days. This can be proved by myelotomography or CT scan[20] as shown in Figure 19.

Therefore, only when the intraoperative myelogram shows continuing obstruction by posterior wall fragments after the reduction manoeuvre a laminectomy is added to impact these fragments from the same posterior approach or an additional anterior procedure may be indicated. A laminectomy is also performed for the repair of dural lesions, which are found more commonly on the dorsal than on the anterior aspect of the dura.

For older lesions with incomplete paraplegia and dislocated posterior wall fragments, where reduction in the described manner may be no longer successful, anterior decompression and stabilization is preferred.[4,20,38,41,49,71]

OTHER USES

The versatility of the device makes it a useful tool in various conditions besides fresh fracture treatment.



Fig 11. Two examples of conversion of painful long-range instrumentations into FI instrumentations. A, A 28-year-old woman (Frankel E). B, A 23-year-old man (Frankel A: no change). The difference in length is impressive, as was the functional gain for the patients.

Posttraumatic Deformities

In corrective surgery for late posttraumatic problems such as failure of other instrumentations, kyphotic deformities or permanent instability, FI instrumentation facilitates the after-treatment and permits immediate ambulation. In combination with anterior spine osteotomies, the FI adds reliable stabilization to the procedure (Figure 20). Since it is applied in these cases usually in the compression mode acting biomechanically in a tension band function, immediate mobilization of the patient may be undertaken even without external support.

Tumor Surgery

As the FI instrumentation can be applied easily after a laminectomy and provides immediate stability, it is a useful device for surgery in primary and metastatic bone tumors of the spine. If necessary, the instrumentation can be extended to more than two segments using longer threaded rods (Figure 21). For anterior resection of a tumorous vertebral body the procedure becomes safer and easier by previous *in situ* bridging dorsally with the FI.

Particular Conditions

In particular cases of degenerative diseases, spondylitis, congenital malformations, Bechterew's disease, Pott's disease, or Charcot spine, FI instrumentation proved helpful as well to achieve immediate stability within a short area. An example is given in Figure 22.

By means of a lumbosacral malformation, the versatility of FI instrumentation to apply various forces can be demonstrated best. As the device permits a direct and forceful adjustment of a single vertebra in all three planes, it makes the full correction of a malpositioned last lumber vertebra possible provided that there is no bony union of the malformation. Figure 23 shows a lumbosacral malformation with an obliquity of L5 of 25°, leading to scoliosis and decompensation, the trunk hanging over three cm to the left. Previous trials in similar cases with short Harrington compression and distraction instrumentations to correct the malposition of the vertebral body were not successful since the forces are applied eccentrically only on the posterior elements. With FI instrumentation, the vertebral body could be brought exactly into horizontal position and, by a parallel shift with one oblique cerclage wire around two Schanz screws, even be centered into the midline (Figure 23).

Salvage Procedures

In the multiple operated back with instability and anchoring problems for other implants, the FI can be very helpful, in addition to the common decompression and fusion. Always the remnants of pedicles can be localized with roentgenograms for positioning of the Schanz screws. By combination of distraction, compression or neutral fixation with decompressive procedures the instrumentation permits individual solutions: internal fixation in these cases offers the possibility of increased fusion rate, decreased pain, and easier after-treatment.

Spondylolisthesis Grade III, IV, and Spondyloptosis

To achieve partial reduction prior to fusion in severe spondylolisthesis, several methods are published.[5,6,9,11,21,29,45,54,62,63,69] In most of them one point is unsatisfactory: the distraction devices do lift L5, but they tend to increase the preexisting[58,72] unphysiologic vertical position of the sacral bone and to push forward even more the lordotic lumbar spine. In addition, the lumbar spine is fused from the sacrum up to L3, L2, or even L1. Only a few methods permit simultaneous reduction and unisegmental lumbosacral fusion,[27,43,62] and FI instrumentation can be included among these.

In grade III and IV spondylolistheses, a one-stage combined procedure is performed,[17] beginning with an anterior release through a transperitoneal approach. The anterior longitudinal ligament and the L5–S1 disc is resected. The end plates are curetted as far as possible and the interbody space filled with autologous bone paste. A sufficient amount is added also anteriorly to the bodies of L5 and S1. After wound closure the patient is turned into the prone position. The lamina of L5 is resected, and L5 and S1 are instrumented with transpedicular Schanz screws. Now reduction is performed with the help of their long lever arms and secured by tightening the FI (Figure 24).

In spondyloptosis, where the disc L5–S1 is not initially accessi-



Fig 12. Even in cases with destruction of the anterior and posterior elements, **A, B,** only the adjacent vertebrae are instrumented realizing a bisegmental fixation. When the posterior longitudinal ligament is intact also posterior wall fragments can be reduced without laminectomy, if operation is performed within the first 5 days. **C.** Often anatomic reduction of the vertebra is reached as in this case of a 35-year-old woman. Myelography, **D,** shows the condition of posterior wall. Reduction is held throughout mobilization. **E.** (Admission: Frankel D; follow up: improved. Frankel D.)