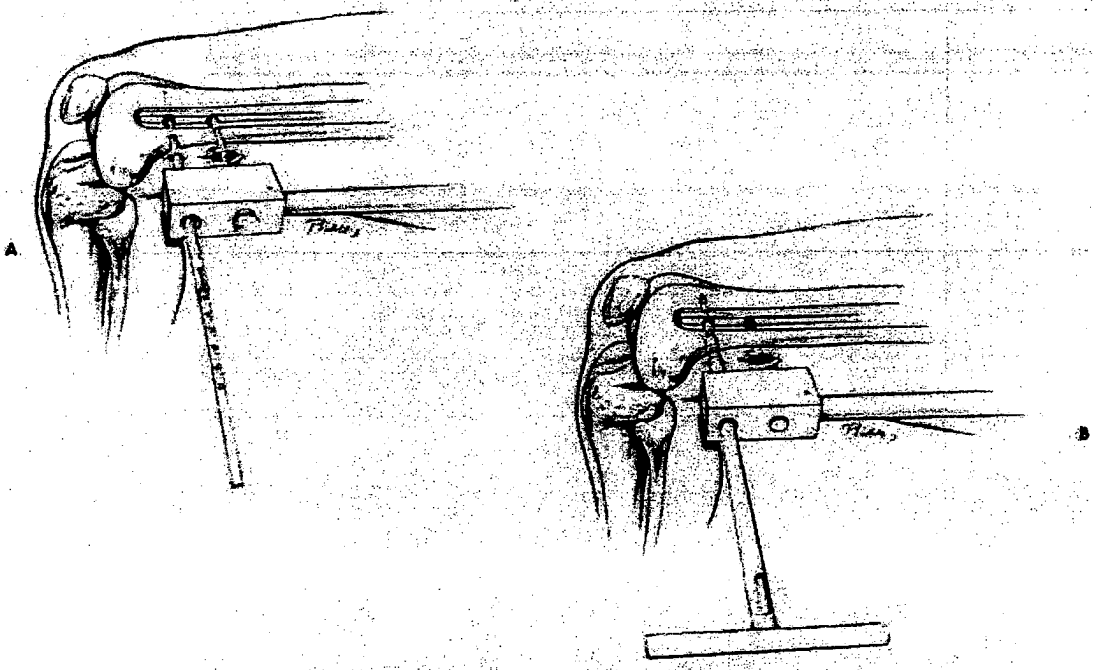

Fig. 44-49. A, Screw length is measured with depth gauge. B, Screw is inserted through target device. (From Boyle, M.: Grosse-Kempf tibial surgical protocol. Courtesy Howmedica, Inc.)

to maintain alignment of the target device until preparation of the first hole is completed and the screw insertion is started.)

AFTERTREATMENT. The aftertreatment is about the same as for Lottes nail fixation. When rigid fixation has been obtained in middle shaft fractures, partial weight bearing on crutches is allowed early. For fractures of the proximal or distal shafts, a patellar weight bearing or a long leg cast may be required until bridging callus is noted.

Fixation of fibula for tibial fractures

Internal fixation of the fibula is unnecessary in treating fibular shaft fractures but may be useful in stabilizing other structures. Fixation of a fibular fracture by a plate and screws or by a medullary nail inserted through the lateral malleolus will partially stabilize comminuted fractures of the distal tibial shaft or metaphysis when damage of the soft tissues or contamination of the wound makes internal fixation of the tibia inadvisable. Fixation of the fibula is essential in the treatment of comminuted explosion fractures of the ankle and should be done as the initial step. Fractures of the tibia, when soft tissue damage or contamination of the wound makes internal fixation inadvisable, can be handled by inserting Steinmann pins transversely through the tibia above and below the fracture and incorporating them in a cast or applying an external fixator (p. 1582). Even so, fixing the fibula may occasionally be useful.

Deformities of foot and toes following tibial fractures

McKeever has described the checkrein deformity of the great toe that may occur after fracture of the distal third of the tibia. The flexor hallucis longus muscle adheres to callus at the fracture so that its tendon forms a bowstring between this point and the site of insertion of the tendon into the great toe. Thus when the ankle is dorsiflexed, the great toe is sharply flexed, but when the ankle is plantar flexed, the interphalangeal joint extends completely. The pressure of the plantar surface of the great toe against the sole of the shoe on dorsiflexion of the ankle produces a painful callus. Should it be impossible to free the muscle in the distal third of the leg after the fracture has united, the tendon is lengthened in the foot.

Karlström et al. in 1975 reported 23 cases of clawfoot or cavus deformity following fractures of the tibial shaft. These deformities were believed to be the result of fibrous contracture of the muscles of the deep compartment from muscle trauma and ischemia in the deep posterior compartment of the leg. This deformity may be misinterpreted as an inward malrotation of the tibial fracture.

CONDYLES OF TIBIA

There are many classifications for fractures of the condyles of the tibia. The one most commonly used is that described by Hohl. Hohl classified tibial condylar fractures into six categories: type 1, undisplaced; type 2, local

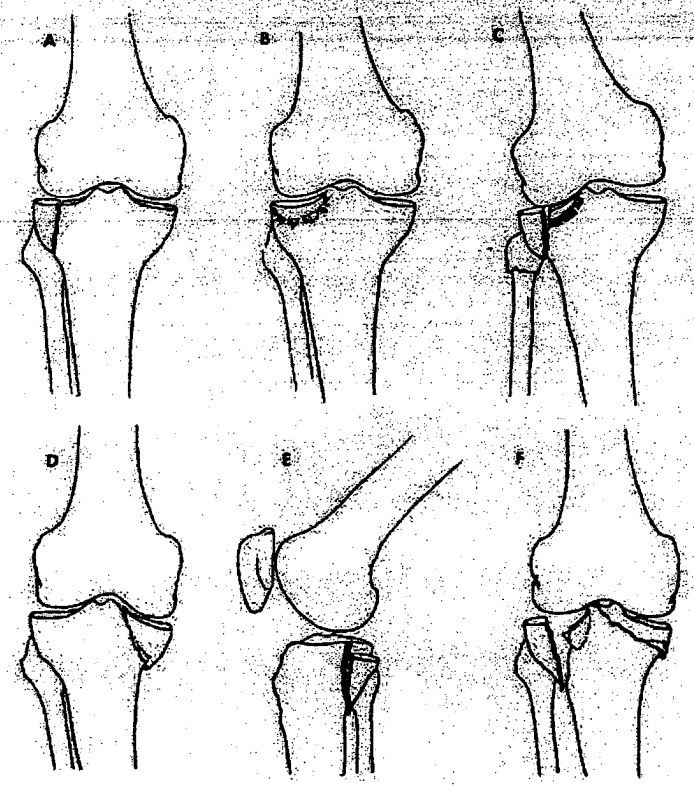

Fig. 44-50. Hohl classification of tibial condylar fractures. A, Undisplaced. B, Local compression. C, Split compression. D, Total condylar compression. E, Split. F, Comminuted. (From Hohl, M.: J. Bone Joint Surg. 49-A:1455, 1967.)

compression; type 3, split compression; type 4, total condylar depression; type 5, split; and type 6, comminuted (Fig. 44-50). In a study by Hohl of 915 tibial condylar fractures, 24% were undisplaced, 33% were local compression, 16% split compression, 8% total compression, 4% split, and 14% comminuted. In addition to the articular bony injury, injuries to the cruciate and collateral ligaments and the menisci are very common. Historically these fractures have been referred to as bumper or fender injuries, but a variety of falls and other less violent trauma frequently produce these fractures, particularly in the elderly osteoporotic patient. Schulak and Gunn relate the frequency of the type of fracture produced and the frequency of collateral ligament injury to the type and mechanism of forces applied to the knee (Fig. 44-51). Ligamentous injuries occur more frequently in undisplaced, local compression, and split compression fractures, and it is wise to obtain stress roentgenograms of the knee to evaluate these structures. Schatzker et al. in a review of 94 tibial condylar fractures proposed the following classification and treatment methods when the fracture is significantly displaced or when significant joint instability is present.

Type I—pure cleavage (Fig. 44-52)

A typical wedge-shaped uncomminuted fragment is split off and displaced laterally and downward. This fracture is common in younger patients without osteoporotic bone. If displaced, it may be fixed with two transverse cancellous screws.

Type II—cleavage combined with depression (Fig. 44-53)

A lateral wedge is split off but in addition the articular surface is depressed down into the metaphysis. This tends to occur in older people, and if the depression is greater than 7 to 8 mm or instability is present, most should be treated by open reduction, elevation of the depressed plateau "en mass," bone grafting of the metaphysis, fixation of the fracture with cancellous screws, and buttress plating of the lateral cortex.

Type III—pure central depression (Fig. 44-54)

The articular surface is driven into the plateau. The lateral cortex is intact. These tend to occur in osteoporotic bone. If the depression is severe or if instability can be demonstrated on stress, the articular fragments should be

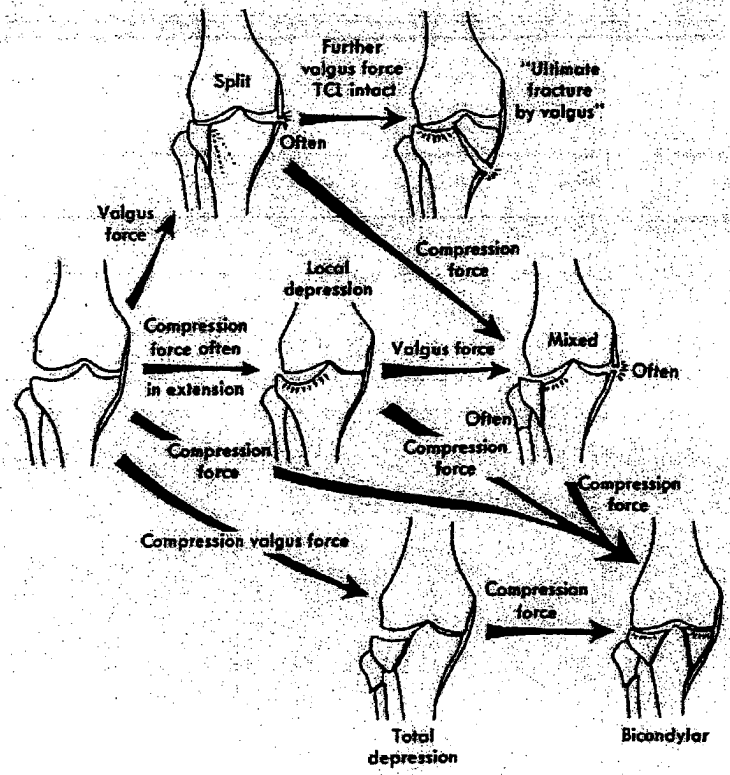

Fig. 44-51. Relationship of force to tibial condylar fractures. Tibial collateral ligament injuries commonly occur in split and mixed fractures of lateral plateau. In mixed fractures fibula is often fractured. In total depression fractures proximal fibular fracture or proximal tibiofibular diastasis occurs. (From Schulak, D.J., and Gunn, D.R.: Clin. Orthop. 109:166, 1975.)

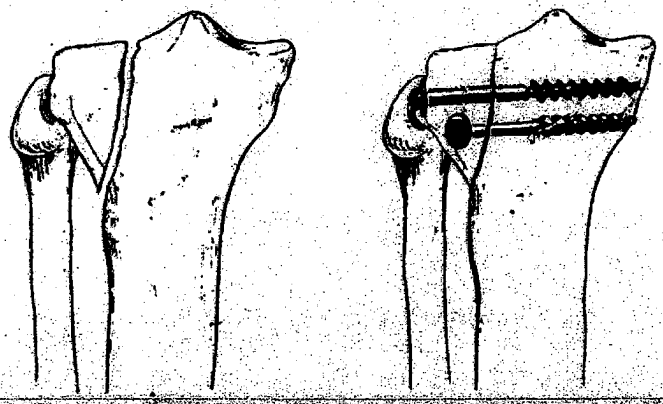

Fig. 44-52. Type 1, pure cleavage fracture. (From Shatzker, J., McBroom, R., and Bruce, D.: Clin. Orthop. 138:94, 1979.)

[redacted]

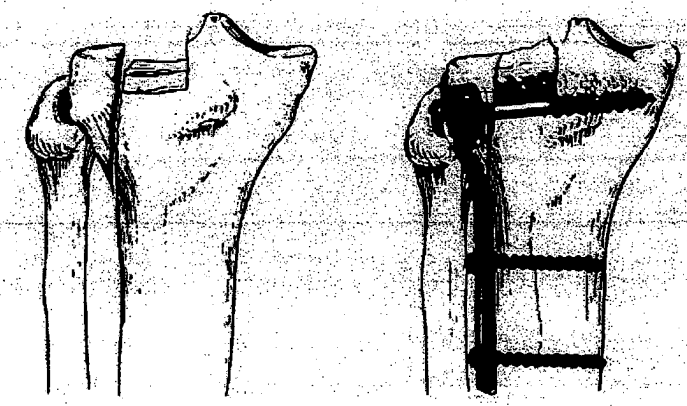

Fig. 44-53. Type II, cleavage combined with depression. Reduction requires elevation of fragments with bone grafting of resultant hole in metaphysis. Lateral wedge is lagged on lateral cortex protected with buttress plate. (From Schatzker, J., McBroom, R., and Bruce, D.: Clin. Orthop. 138:94, 1979.)

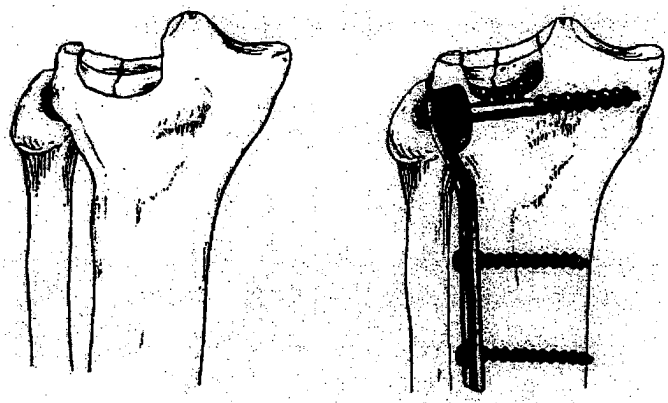

Fig. 44-54. Type III. pure central depression. There is no lateral wedge. Depression may also be anterior, posterior, or involve whole plateau. After elevation of depression and bone grafting, lateral cortex is best protected with buttress plate. (From Schatzker, J., McBroom, R., and Bruce, D.: Clin. Orthop. 138:94, 1979.)

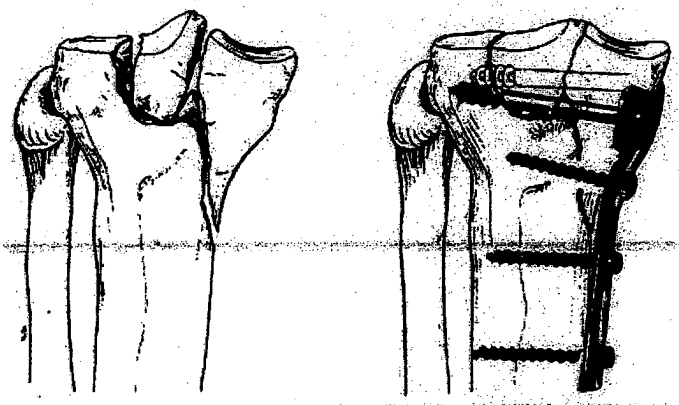

Fig. 44-55. Type IV. Medial condyle is either split off as wedge (type A) as illustrated, or it may be crumbled and depressed (type B) characteristic of older patients with osteoporosis (not illustrated). (From Schatzker, J., McBroom, R., and Bruce, D.: Clin. Orthop. 138:94, 1979.)

elevated and bone grafted, and the lateral cortex is supported with a buttress plate.

Type IV—fractures of medial condyle (Fig. 44-55)

These may be split off as a single wedge or may be comminuted and depressed. The tibial spines are often involved. These fractures tend to angulate into varus and should be treated by open reduction and fixation with a medial buttress plate and cancellous screws.

Type V—bicondylar fractures (Fig. 44-56)

Both tibial plateaus are split off. The distinguishing feature is that the metaphysis and diaphysis retain continuity. Both condyles should be fixed with buttress plates and cancellous screws.

Type VI—plateau fracture with dissociation of metaphysis and diaphysis (Fig. 44-57)

A transverse or oblique fracture of the proximal tibia is present in addition to a fracture of one or both tibial condyles and articular surfaces. The dissociation of the diaphysis and metaphysis makes this fracture unsuitable for treatment in traction and most should be treated with buttress plates and cancellous screws, one on either side if both condyles are fractured.

Surgical reconstruction of the articular surface, closed manipulation and casting, particularly with the cast brace, and traction with early motion have all been advocated for tibial condylar fractures. No method can be routinely used for all fractures, and each patient has to be individually evaluated. Evaluation of the fracture includes adequate

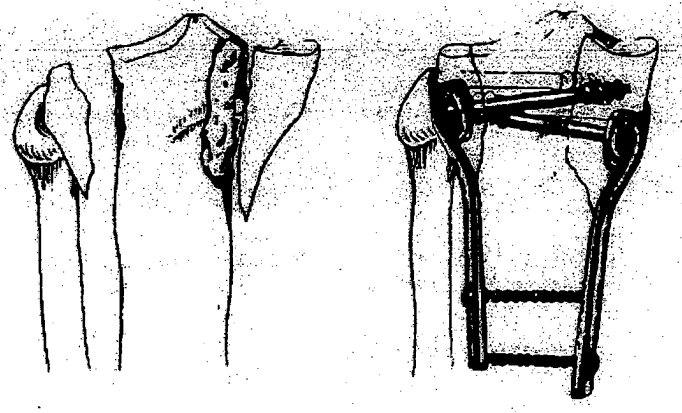

Fig. 44-56. Type V. Note continuity of metaphysis and diaphysis. In internal fixation both sides must be protected with buttress plates. (From Schatzker, J., McBroom, R., and Bruce, D.: Clin. Orthop. 138:94, 1979.)

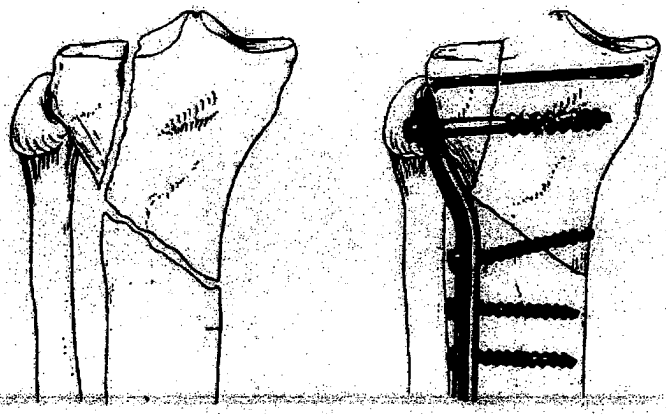

Fig. 44-57. Type VI. Essence of this fracture is fracture line which dissociates metaphysis from diaphysis. Fracture pattern of condyles is variable and all types can occur. If both condyles are involved proximal tibia should be buttressed on both sides. (From Schatzker, J., McBroom, R., and Bruce, D.: Clin. Orthop. 138:94, 1979.)

[redacted]

Case 1:04-cv-00204-JJF Document 157-6 Filed 04/13/2005 Page 6 of 11

roentgenograms along with consideration of the patient's age and social and economic demands as well as the presence or absence of related injuries. Extensive surgery on a severely comminuted fracture may result in less than optimum internal fixation and a need for postoperative immobilization resulting often in the joint being neither stable nor freely moveable. The use of traction for tibial condylar fractures usually produces good early motion, but often there are significant residual deformity and instability that lead to degenerative changes or arthritis.

Evaluation

Anteroposterior, lateral, and both oblique roentgenograms and frequently tomography are necessary to evaluate these fractures adequately. Assessment of the degree and the size of depressed articular fragments may be possible only with tomography. Often the classification of the fracture made from standard roentgenograms is changed to another type after tomograms are evaluated. The upper tibial articular surface is normally inclined posteriorly 10 to 15 degrees and an anteroposterior roentgenogram with the beam angled distally 10 to 15 degrees will result in better views of the tibial plateaus. Stress roentgenograms for collateral ligament injury have been mentioned previously.

Martin as well as Reibel and Wade have analyzed and discussed injuries of the tibial collateral ligament associated with these fractures. Injury or tear is suggested by local reaction about the ligament and persistent instability after reduction of the fracture of the condyle. Martin recommends checking the integrity of the ligament by comparing stress roentgenograms of the knee with those of the normal knee. Instability may be the result of ligamentous disruption, osseous depression of the articular surface, or translational displacement of a fracture fragment. Associated ligament injuries are now reported to occur in 10% to 30% of these fractures. According to Rasmussen, the major indication for surgery is not the measure of depression of the fragment or articular surface but the presence of valgus or varus instability of 10 degrees or more with the knee flexed less than 20 degrees.

Sarmiento et al. studied the influence of the fibula on the anatomic behavior of condylar fractures and suggest that some types may be safely treated in a functional brace. They studied 106 fractures of the proximal tibia treated in such a brace and concluded that often the condition of the fibula, whether fractured or intact, determines the angulatory behavior of these fractures under weight bearing and functional conditions. Isolated fractures of the lateral condyle with an intact fibula did not collapse further because of the support of the fibula. Conversely, fractures of the lateral condyle with associated fibular fractures had a tendency to collapse into valgus because of the loss of support of the fibula. Fractures of both condyles did not collapse further or angulate when the proximal fibula was fractured and displaced. However, if the fibula was intact, the medial condyle usually collapsed, creating a varus deformity.

Whatever the injury, the damage to the joint is usually more extensive than the roentgenograms indicate. The bony attachments of one or both cruciate ligaments may be avulsed and lie as free fragments in the joint. Comminuted fragments of the articular surface often lie at angles to their normal plane and may be upside down. The meniscus is often torn at its periphery, and a part or all of it may lie between the comminuted fragments.

TREATMENT. In undisplaced fractures, after the integrity of the collateral ligaments is established, treatment should consist of a few days of splinting followed by early active knee motion. Weight bearing should be delayed until fracture healing is evident, generally at 8 to 10 weeks.

After fracture of its articular surfaces the function of a joint is usually proportionate to the accuracy of reduction. Most authors point out that with displaced fractures the most significant factor influencing the long-term results and hence the treatment approach is the degree of displacement and depression. If the depression is less than 5 to 6 mm, then nonoperative treatment consisting of traction, early motion, and delayed weight bearing is usually satisfactory. When the compression or depression is from 6 to 8 mm, the decision for nonoperative or operative treatment depends to a great degree on the patient's age and the demands of activity on the knee. If the patient is elderly and sedentary, nonoperative treatment is usually suitable. If the patient is young or active, attempts at surgical reconstruction of the joint surface are justified. When the depression exceeds 10 mm, surgery with elevation and restoration of the joint surface is advised. In split compression fractures the treatment approach depends to a great degree on whether the displaced rim of the condyle can be reduced into a supporting position under the femoral condyle. This can often be accomplished by manipulation, and the displaced rim is held in this position either by traction or with percutaneous pins inserted across into the intact condyle. If the split cannot be manipulated into an acceptable position under the femoral condyle, then open reduction, elevation of the depressed area, and repositioning of the fragment beneath the condyle are indicated. Total condylar depression fractures often involve the medial condyle and can usually be reduced by manipulation. Often, however, they gradually redisplace in spite of continued traction or the use of a cast. If a good reduction can be obtained by manipulation, the percutaneous insertion of several transfixing pins into the intact lateral condyle will aid in preventing redisplacement and will allow early motion. If a satisfactory reduction cannot be obtained by manipulation, open reduction is recommended with fixation using multiple cancellous screws or with a buttressing type of T plate.

A split fracture may involve the anterior or more commonly the posterior margin of the medial tibial condyle. If significant displacement is present, open reduction and internal fixation with one or more cancellous screws is generally the best method of treatment.

Comminuted fractures may split into the intercondylar eminence area, and the articulating surface of the medial and lateral condyle may be relatively uninvolved. Usually this type of fracture is best treated nonoperatively since reassembling the comminuted condyles along with the associated proximal shaft fracture is most difficult. Reduction by manipulation or by traction with a Kirschner wire through the calcaneus or the distal tibia is usually successful. Skeletal traction in extension with gentle range-of-motion exercises for the knee for 4 to 6 weeks followed by a cast brace will produce the most predictable results. Open reduction and internal fixation are especially difficult since

Case 1:04-cv-00204-JJF Document 157-6 Filed 04/13/2005 Page 7 of 11

extensive exposure and dissection are required when both condyles are opened. For the average orthopaedic surgeon, open reduction often results in considerable impairment of knee function even though satisfactory restoration of the articular surface may have been accomplished. The extensive exposure and long surgery time also increase the possibility of complications. If open reduction and internal fixation are necessary, an extensive anterior approach reflecting the patellar tendon from its attachment into the tibia affords good exposure of both condyles. A screw or a Stone four-point staple serves to reattach the tendon. Multiple cancellous screws and both medial and lateral contoured buttressing plates may be required for fixation of the fracture fragments.

Fracture of lateral condyle

An understanding of the mechanism producing fractures of the lateral tibial condyle is necessary for intelligent treatment. This fracture is usually produced by a valgus strain on the knee with the ligaments and muscles on the medial side resisting separation of the tibial and femoral condyles. The lateral femoral condyle is driven downward into the weight-bearing surface of the lateral tibial condyle, depressing the central portion of the articular surface into the cancellous metaphysis well below its normal level. In addition the lateral margin of the articular surface of the tibia bursts laterally and one or more fractures extend longitudinally down into the metaphysis of the tibia, producing a lateral fragment. This fragment is usually fairly large and when seen from the lateral side is often triangular with the base of the triangle proximal. Usually the fragment is held at joint level by the intact fibula. Less often the lateral condyle fractures the fibula at its neck and may be displaced as one large fragment with only slight central depression and comminution.

TECHNIQUE. Begin the incision approximately 2.5 cm lateral to the superior pole of the patella, carry it distally just lateral to the tibial tuberosity, and then curve it distally and posteriorly to end approximately 10 cm distal to the joint line just anterior to the neck of the fibula. Reflect the lateral edge of the skin flap with its subcutaneous tissue until the head of the fibula and the entire lateral aspect of the joint are seen. Identify and protect the common peroneal nerve. Then incise the capsule and inspect the interior of the joint. When the meniscus is found undamaged or only detached peripherally, it should be preserved. The condyle can be adequately exposed by incising the coronary ligament attachment of the meniscus and reflecting it proximally with the femoral condyle. A varus stress can then adequately expose the articular surface of the lateral condyle. If the meniscus is irreparably torn, meniscectomy is required.

To expose the longitudinal fracture of the lateral condyle, strip the origin of the extensor muscles from the anterolateral aspect of the condyle through an incision shaped like an inverted L (Fig. 44-58). Extend the horizontal limb

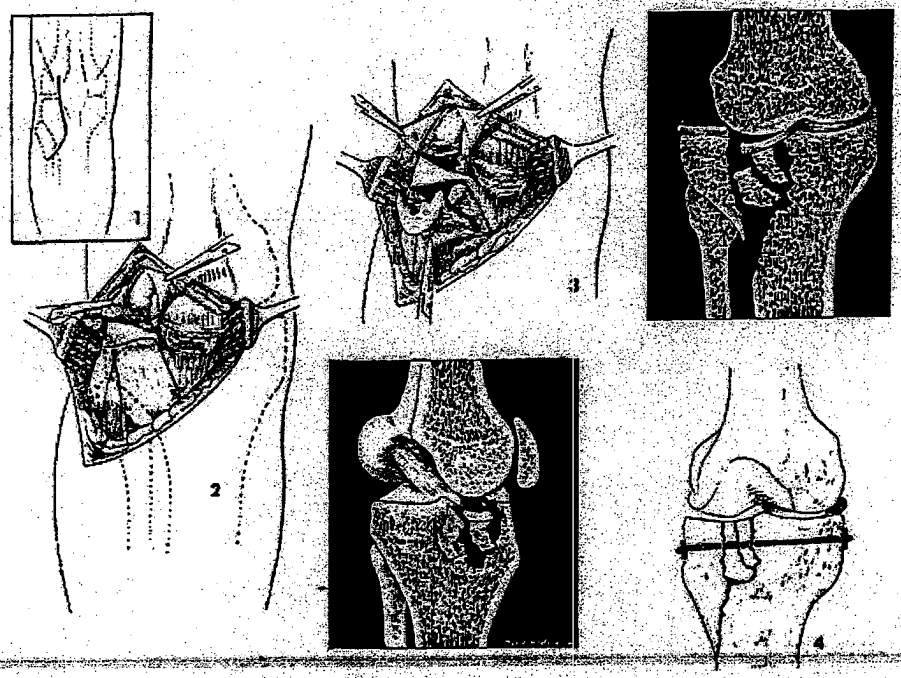

Fig. 44-58. Barr open reduction and internal fixation of fracture of lateral condyle of tibia. 1, Skin incision. 2, Capsule of joint incised to permit inspection. L-shaped incision releases origin of extensor muscles. 3, Central portion of articular surface is usually displaced below normal level of tibial plateau; lateral margin of articular surface bursts laterally. 4, After elevation of central portion and fixation with bolt. (From Barr, J.S.: JAMA 115:1683, 1940.)

Case 1:04-cv-00204-JJF Document 157-6 Filed 04/13/2005 Page 8 of 11

of the incision laterally from the tibial tuberosity for approximately 2.5 cm and pass the vertical limb distally 5 to 7.5 cm just lateral to the crest of the tibia. Now reflect the muscle origin laterally until the fracture line is exposed. Rarely does the iliotibial band require detachment. If it does, detach its insertion to Gerdy's tubercle with a small piece of bone and reflect it proximally.

Retract the lateral fragment to gain access to the central part of the tibial condyle. This lateral fragment will often hinge open like a book, exposing the depressed articular surface and cancellous bone of the central depression. Insert a periosteal elevator well beneath the depressed articular fragments and by slow and meticulous pressure elevate the articular fragments and compressed cancellous bone in one large mass (Fig. 44-59). This produces a large cavity in the metaphysis that must be filled with bone. Unless this is done, redisplacement and settling down may occur. Various types of grafts have been proposed, from transverse cortical supports to full-thickness iliac grafts. Jackson has proposed using a segment of autogenous fibula. We prefer packing cancellous bone into the defect since this much more nearly conforms to the defect cavity. It can be obtained from either the iliac crest or the lateral femoral condyle. We have found that cancellous grafts from the bone bank are also satisfactory. If the lateral femoral condyle is used, split longitudinally and elevate the synovium and periosteum over the lateral aspect of the condyle. Create a lateral cortical window and with a curet remove an adequate amount of cancellous bone to fill the defect. Replace the lateral window and close the synovium. After the cavity in the tibia beneath the elevated fragments has been filled with cancellous bone, pack the bone snugly using an inlay impactor. Then replace the lateral tibial condylar fragment snugly to lock the articular fragments together. The lateral margin of the articular surface must be reduced under the femoral condyle for support.

As the fragments are elevated and reduced, temporarily fix them with multiple small Kirschner wires. We usually apply a specially contoured AO type of T buttress plate for definitive fixation. This plate is applied to the anterolateral tibial condyle and contoured precisely to conform to the condyle and proximal metaphysis. Once properly contoured, it is secured to the condyle with appropriate cancellous screws of sufficient length to engage the opposite medial cortex.

If the fracture consists of only one or two large fragments with little or no comminution and little central depression, replacement and internal fixation with cancellous screws, Knowles pins, or Webb stove bolts have been used. If the lateral cortical bone is fragile and osteoporotic, a washer may prevent the head of the screw or pin from losing fixation. A stove bolt is somewhat difficult to use and is seldom selected (Fig. 44-60). If a Knowles pin or cancellous screw is used, it must be long enough to engage the cortex of the opposite condyle securely. Insert the pin or screw from the lateral side of the lateral fragment directly transverse to the longitudinal axis of the tibia and in a posterior and medial direction catching the medial tibial cortex.

If the meniscus has been detached peripherally, carefully suture it back to its coronary ligament attachment.

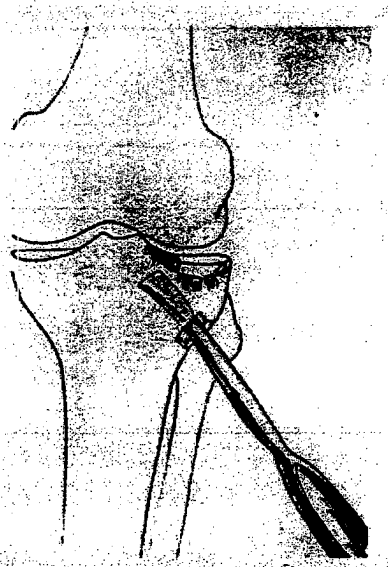

Fig. 44-59. Periosteal elevator or similar instrument is introduced below level of depressed tibial plateau fragment and with careful and gentle upward pressure, articular fragments are elevated.

Then replace the iliotibial band to its insertion at Gerdy's tubercle with a Stone four-point staple.

If displacement of the peripheral rim is slight and central depression of the condyle is the main deformity, remove an anterior cortical window with its proximal edge about 1.3 cm distal to the articular surface. Then insert a small thin osteotome or periosteal elevator through the window into the cancellous subchondral bone and elevate to normal level the depressed fragments of the articular surface. Then fill the defect with cancellous bone as just described.

AFTERTREATMENT. The knee is placed in a posterior plaster splint. At 3 to 4 days, if the wound is healing satisfactorily, the splint is removed and physical therapy with quadriceps exercises and gentle active assistive exercises are begun; or a passive motion machine may be used.

Crutch walking is begun but no weight bearing is permitted for 12 to 16 weeks.

If extensive suturing of the periphery of the meniscus has been required, immobilization for 3 weeks or so is required before motion exercises are permitted.

Ligament repair with condylar fracture

Associated collateral and cruciate ligament injuries with tibial condylar fractures are much more common than once realized and if untreated may be responsible for instability and a poor late result despite a well-healed condylar fracture. Associated ligamentous injuries have been reported in 4% to 10% of tibial condylar fractures. The tibial collateral ligament is most commonly injured, usually with undisplaced or local depression fractures of the lateral tibial condyle. Stress roentgenograms are essential in making this diagnosis. If the intercondylar eminences of the tibia are fractured and displaced, these should be replaced and secured at the time of open reduction of the condyle. Re-



Fig. 44-60. A, Typical fracture of lateral condyle of tibia. B, After open reduction and fixation. Tibial plateau has been restored.

pair of the tibial collateral ligament requires a separate medial incision as described for repair of the tibial collateral ligament in Chapter 56. When the ligament has been repaired and the condylar fracture fixed, the knee is immobilized in a long leg plaster cast with the knee flexed 45 degrees. While early motion following fixation of tibial condylar fractures is desirable, motion must be delayed if repair of an acute collateral ligament injury is also involved. We have found that a long leg cast maintained for 2 weeks until the sutures are removed, followed by a femoral cast brace with an extension stop that allows flexion but prevents full extension, is an effective compromise in postoperative care. The cast brace is worn for a 4-week period, and then is removed and active exercises are begun.

Fracture of medial condyle

If open reduction, elevation, and internal fixation of the medial femoral condyle are required, a technique similar to that previously described for the lateral tibial condyle is carried out. For split compression and total depression fractures of the medial tibial condyle, in addition to elevating the depressed fragment and packing bone beneath it, an AO plate may be used as a medial buttressing plate. This can be bent to an accurate contour to fit the tibial metaphysis and the tibial condyle, and the fracture can be fixed with cancellous screws in the proximal portion of the plate and regular cortical screws in the distal portion (Fig. 44-61).

Comminuted proximal fractures

If open reduction of comminuted fractures involving both condyles is required, extensive exposure is necessary. These fractures are often of the Y variety with both con-

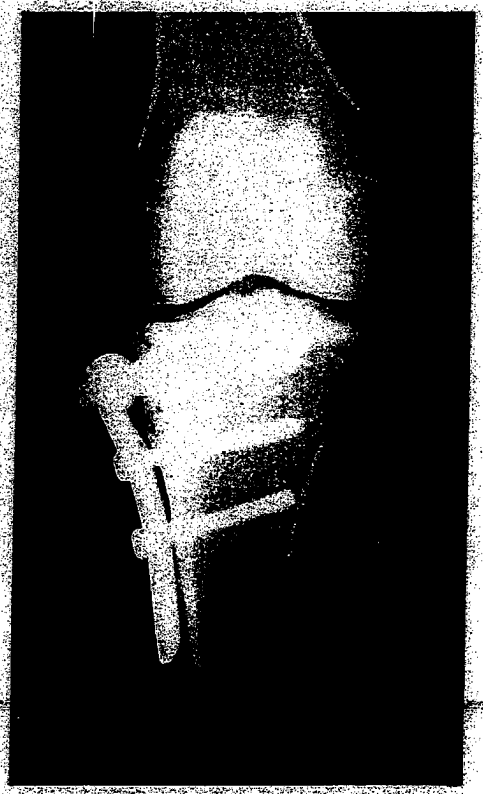

Fig. 44-61. Comminuted fracture of lateral tibial condyle after open reduction and internal fixation with buttress plate. Note cancellous screws through proximal T portion of plate.

[redacted]

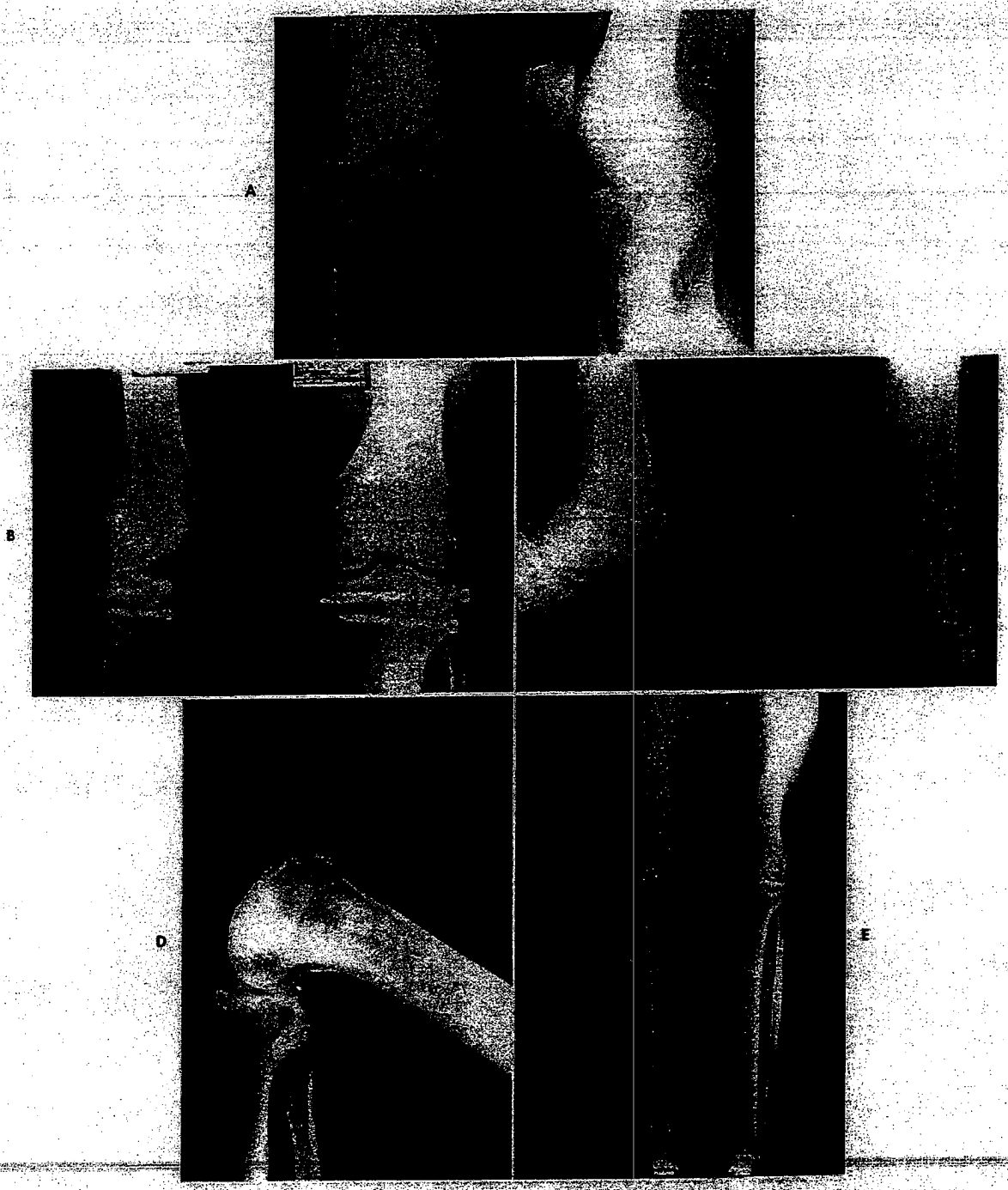

Fig. 44-52. A, Male, 42 years old, sustained severe split depression fracture of lateral tibial plateau. Open reduction and internal fixation was not possible. B, Four months after insertion of lateral facet of patella to replace lateral tibial plateau, internally fixed with Knowles pins. C, Four years after surgery. D, Flexion of knee four years after surgery. E, Standing roentgenogram of both lower extremities demonstrating retention of good lateral joint space 12 years after surgery.

dyles displaced and the central fracture extending into the joint in the intercondylar eminence area. Open reduction and internal fixation are performed preferably on the day of injury or else are delayed for 7 to 10 days until edema and soft tissue reaction have subsided.

TECHNIQUE. Make a long anterolateral incision beginning 2.5 cm above the superolateral aspect of the patella, proceed distally along the lateral aspect of the patella and patellar tendon, and curve it anteriorly across the proximal tibia just inferior to the tibial tuberosity and then distally a sufficient length to expose the proximal shaft fracture. Identify the interval of the prepatellar bursa, and undermine the skin flaps and retract them medially and laterally, exposing the full extent of the patellar tendon and the proximal tibia from the midline laterally to the midline medially. Then detach the patellar tendon with a small plug of bone and reflect it proximally. This exposes both the medial and lateral compartments of the joint for articular reconstruction. Reconstruct the articular surface using multiple Kirschner wires as temporary fixation. Then apply an AO contoured T plate to the medial aspect of the tibial metaphysis and extend it down the medial tibial shaft a sufficient length to rigidly fix all fractures. Insert cancellous screws in the proximal part of the T plate and attach the distal portion with cortical screws. Apply a second, generally smaller T plate laterally to serve as a buttress plate. Remove the multiple Kirschner wires serving as temporary fixation. If the menisci are preserved, suture them to their coronary ligament attachments. Replace the patellar tendon with its plug of bone into the tibial tuberosity and secure it with a screw or a staple so that early gentle range-of-motion exercises can be carried out. Close the capsular incisions with interrupted sutures and close the skin and subcutaneous tissue over Hemovac drains. Place the extremity in a posterior plaster splint with the knee flexed 30 degrees.

AFTERTREATMENT. After 3 or 4 days if the wound is healing satisfactorily, the knee is brought into full extension and gentle active and active assisted exercises are begun. At 3 weeks as the knee motion gradually improves, the patient is placed in a femoral cast brace, but no weight bearing is allowed for 10 to 12 weeks.

PATELLAR GRAFT FOR COMMINUTED LATERAL TIBIAL CONDYLAR FRACTURES

In 1952 Wilson and Jacobs independently described an original method of treating severely depressed comminuted fractures of the lateral condyle: the patella is removed and is used to replace the articular surface of the condyle. The operation is not indicated in split fractures of the condyle or for the usual depression or comminution of its articular surface but rather for those fractures in which restoration of a satisfactory articular surface is impossible because of the extensive comminution. Jacobs reported his experience with the operation in 13 knees, and the results were all satisfactory. In each instance the knee was painless and stable and extension was complete, flexion varied from 50 degrees to normal. We have used this operation several times for extremely comminuted fractures; we are pleased with it and recommend it for those rare fractures that cannot be treated by the usual methods. Reconstruction of the condyle with an autogenous patellar graft is in our opinion preferable to the use of a prosthetic implant.

On roentgenograms Wilson and Jacobs have not noted avascular necrosis of the patellar graft or the depressed condyle. In one of our patients demonstrable avascular necrosis occurred with collapse when the transplanted patella was wafered thinly. In all other patients the patella has been gradually incorporated into the tibial condyle. This procedure is primarily for severely depressed and comminuted condylar fractures and should not be used routinely.

TECHNIQUE (WILSON AND JACOBS). Expose the joint through an anterolateral incision, turn the patella over, and remove it by sharp dissection. Using a rongeur remove the cortical bone from its anterior surface, leaving cancellous bone exposed, but do not wafer the patella thinly. Now divide the patella between its medial and lateral facets. Place the lateral portion with its larger and better formed facet in the defect in the lateral condyle with its cartilaginous surface up. The medial portion of the patella may be chipped up into small fragments and packed beneath the lateral portion once it has been positioned. The lateral portion often fits in snugly and is quite stable; thus Jacobs did not suggest the use of any internal fixation. We fix the graft in place with two transverse Knowles pins (Fig. 44-62).

Lee uses a pear-shaped graft from the anterosuperior iliac spine to fill such a defect. The curved inner table of the graft becomes the new upper surface of the condyle; the sharpened point helps to seat it firmly. The graft is wedged in firmly, and any defects are filled with extra bone chips (Fig. 44-63). We have had no experience with this operation.

AFTERTREATMENT. The leg is placed in a knee immobilizer in a fully extended position. Quadriceps exercises are begun on the day following surgery, and gentle range-of-motion exercises are allowed after 3 or 4 days provided that the incisions are healing satisfactorily. The patient is allowed to begin walking with crutches as soon as he gains good muscular control of the leg. However, full weight bearing is not allowed for 4 to 6 months.

Percutaneous fixation of fractures of condyle

In fractures of a tibial condyle when a satisfactory closed reduction can be obtained, percutaneously inserted Knowles pins or cancellous screws may provide sufficient fixation to allow early active motion. This method is applicable when extensive open reduction with internal fixation is unwise, as in an elderly patient, or when local skin conditions are not satisfactory for major surgery. With the patient under anesthesia a manipulation is carried out using image intensifier television fluoroscopy. If a reduction can be obtained, under television fluoroscopic control pins or screws are inserted through two small stab incisions over the subcutaneous portions of the fractured condyle to engage the opposite cortex. The small stab incisions can usually be closed with a single suture. Range-of-motion exercises can be begun immediately.

