A-21

Acta Neurochir (Wien) (1988) 93: 104–109

Acta Neurochirurgica
© by Springer-Verlag 1988

First Hungarian Neurosurgical Experiences with "Fixateur Interne" in the Treatment of Thoraco-lumbar Spine Injuries

Technical Note

T. Pentelényi and S. Zsoldos

National Institute of Traumatology, Department of Neurosurgery, Budapest, Hungary

Summary

The Fixateur Interne (F.I.) is a new device for internal fixation of the thoraco-lumbar spine developed by Dick and Magerl. It is based on a new principle since it does not act as a four-point bending system like long rod instrumentations but it is a two-point fixation system and it is stable in flection by itself. Because the system seems not well known among neurosurgeons, its use and advantages are described and two cases reported.

Keywords: Fixateur interne; thoraco-lumbar injuries; two-point fixation system; segmental stabilization; Schanz-screws; threaded rods and hinges; transpedicular bone-grafting.

Introduction

It is well known that there are different methods for the reduction and stabilization of the severely injured thoraco-lumbar spine: Harrington distraction and compression system[1, 2, 10, 11], Luque rods and segmental wire fixation[18, 19], Jacobs' locking hook spinal rod system[15, 16], dorsal plates[13, 17, 22, 26, 27, 29] etc. – just to mention some of the stabilization methods. Besides their unquestionable advantages all of them have many disadvantages too. Slipped hooks or rods, broken rods, loss of correction are not rare[4, 9, 25]. Stability often is not good enough, direct reduction is not possible, and being four-point fixation systems they immobilize too long a part of the healthy spine, also with bigger risk of septic complications[23, 28]. There are also rehabilitation problems in the paraplegic patient because of the long stiff thoraco-lumbar spine and the iatrogenic loss of lumbar lordosis[3, 12, 14].

To solve these problems Magerl and Dick developed new spinal stabilization systems, the Fixateur Externe[20, 21] and Fixateur Interne[6, 7]. Here we deal only with the Fixateur Interne (F.I.) or internal fixator. Because this system and its advantages seem not well known among neurosurgeons we like to describe it in a neurosurgical journal and report our first experiences.

Principle and Biomechanics

The mechanical principle is completely different from those mentioned above. F.I. is a two-point fixation system, it does not require second and fourth points of bony support, it is stable by itself. The transpedicle Schanz-screws fix the bodies in any desired position and the screws are held in a stable angle by the connecting threaded rods and hinges. Its stability against bending forces is much better than that of the Harrington distraction rods[6]. Rotational stability can be enhanced by additional diagonal wire-fixation.



Fig. 1. Fixateur Interne. The device consists of two pairs of Schanz screws, two threaded rods and two pairs of hinges: chucks, jaws and nuts. It is used always in pairs

Case 1:04-cv-00204-JJF Document 157-12 Filed 04/13/2005 Page 3 of 25

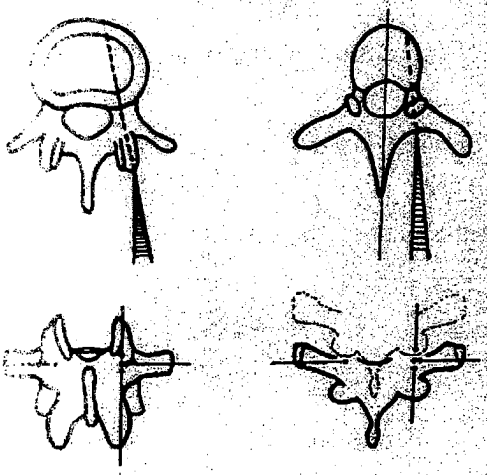

... Points of entry and direction of the transpedicular Schanz ...

... quipment and Surgical Procedure

... device* consists of two pairs of Schanz-screws, on... pair of connecting threaded rods and four hinges ... locks, jaws and nuts (Fig. 1).

... plantation procedure has to be done under image-... control. From a posterior approach long Schanz-screws are driven through the pedicles into the vertebral bodies above and below the injured level. The correct points of entry are marked by the intersection of two lines: the horizontal axis of the transverse process and the vertical lateral tangential line of the articular process (Fig. 2). The selftapping screws are inserted parallel to the end-plates of the bodies and convergent 10 to 15 degrees towards the midline.

Reduction is done with the help of the long lever-arms of the Schanz-screws first by gross manual action if it is necessary, then the screws are connected with threaded rods. Reclination, longitudinal distraction and fixation of the nuts are the further steps. The protruding parts of the Schanz-screws are cut at the end (Fig. 3).



Fig. 4. Transpedicular bone grafting, according to Deniaux[3]

* Fabricated by R. Mathys Co., Fabrik für Chirurgie-Instrumente, CH-2544 Bettlach, Switzerland.



Fig. 3. Fixateur Interne – applied to a spine model



Fig. 5. Case 1. Fracture of L1 with subluxation of Th 12 vertebra. Conservative reduction was not successful because of the subluxation of the right articular processes. Complete reduction and stabilization by Fixateur Interne. There was no neurological deficit

In many cases decompression can be achieved by reduction itself. If intraoperative myelography shows persisting block even after reduction and stabilization other kinds of decompression are necessary: laminectomy and antero-lateral decompression, opening the dura and duraplasties.

In the case of anterior bone-loss after reduction of a compressive body fracture direct transpedicle bone-grafting can be done from the same posterior approach with autologous cancellous bone-grafts according to Daniaux[5] (Fig. 4).

Case Reports

Our first experiences with this instrumentation are based on two cases.

1. S.P. 20 years old young man suffered a fracture-dislocation of Th 12-L 1 in a traffic accident (Fig. 5, top left). There was no neurological deficit. Conservative reduction was not possible because of the locked facets (Fig. 5, top right). Reduction was reached with the help of the long lever-arms of the Schanz-screws driven in a transpedicular way and after that we could perform stabilization in good position (Fig. 5, lower films).

2. B.M. 17 years old girl had a severe fracture-dislocation of L 1–2 with a severe incomplete neurological lesion (Frankel stage B, 8)

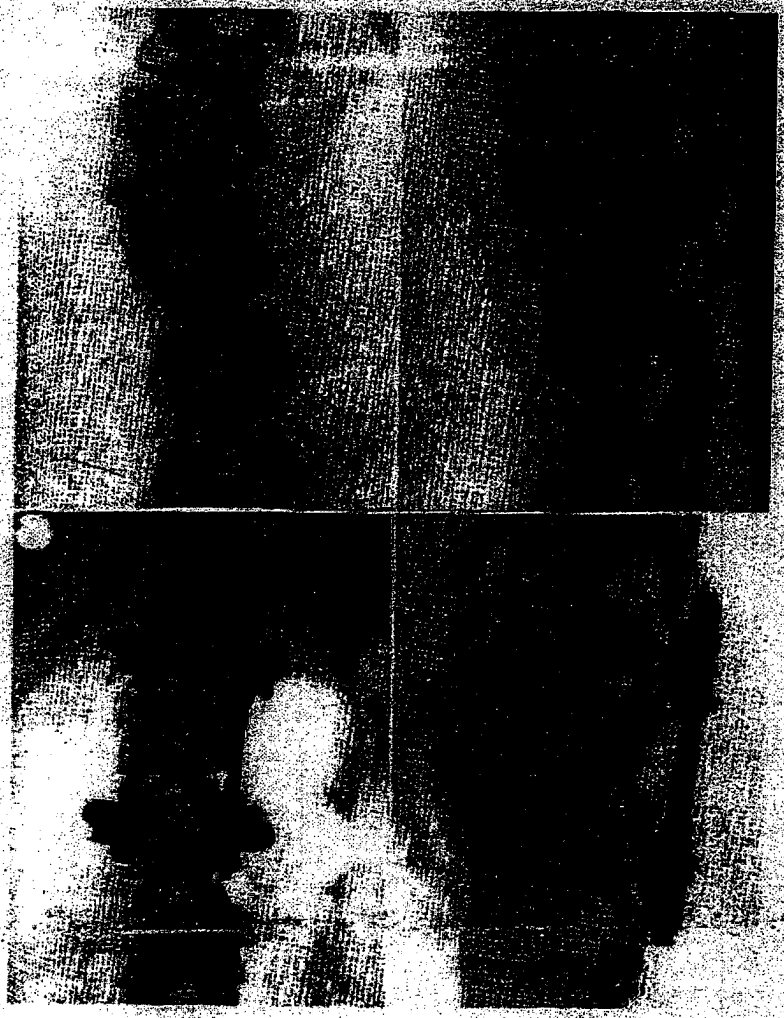

Fig. 6. Case 2. Fracture-dislocation of L 1–2 with severe incomplete neurological lesion (Frankel B). Reduction and stabilization by Fixateur Interne as the first step of surgical treatment. (Treatment is continued in Fig. 7)

in a motor accident (Fig. 6, top films). Reduction and stabilization was done by F.I. (Fig. 6, lower films) but the myelogram showed complete block even after reduction (Fig. 7, top pictures), so we had to perform a laminectomy, antero-lateral decompression and duraplasties with transpedicular bone-grafting. All of them were done in the fixed position assured by F.I. Concussion and rough oedematous swelling were seen in the cauda-equina. Anatomical interruption was not seen in the roots except in those of two high lumbar roots (L 2–3 in the right side). During the first six months of rehabilitation a moderate improvement of the neurological function was seen, the patient reached Frankel stage C[4]. The last check-up (Fig. 7, lower films) showed good and unchanged position of the stabilized spine.

Conclusions

We have only limited experience but it agrees with that published by the inventors Dick and Magerl[6, 7].

F.I. seems to be suitable for the treatment of all kinds of severe fracture-dislocations from Th 8 to S 1, also in the cases of torn ligaments, fractures of the posterior wall of the vertebral body, fractures and dislocations of the arches etc.

It is a very good method for direct reduction by the long lever-arms of the Schanz-screws and for stabilization by threaded rods, jaws and nuts. If it is necessary all kinds of effective bony decompression and dural decompression can be achieved in the reduced and stabilized position.

Surgery is done from the posterior approach which is easier and less demanding for the patient than ventral approach, and even also the anterior and middle col-



Fig. 7. Case 2 (continued). Intraoperative myelography shows complete block even in the reduced position. Laminectomy, antero-lateral decompression, dural decompression and duraplasties with transpeduncular bone grafting. Moderate improvement of neurological functions (Frankel C) and good spinal position after 6 months

umns of the spine can be fixed well in the transpedicular way.

The loss of bony substance of the injured vertebral body can be treated by direct transpedicular bone-grafting from the same posterior approach.

F.I. can assure proper segmental stabilization in the best way: only two segments are fixed generally, the healthy part of the spine remains intact, lordosis can be restored.

Its stability against bending forces is much higher than that of the long rod systems. Its rotational stability is not high but its enhancement is possible by diagonal



Fig. 8. Fixateur Interne with additional diagonal wire fixation in the case of rotational instability (according to Dick[4])

wire fixation in the cases of rotational instability (Fig. 8).

The patients do not need postoperative external fixation, their mobilization can be started from the first postoperative day. There are good possibilities for early rehabilitation. Removal of the metal implants is done 10–12 months later when solid bony union is seen.

The indications for this excellent new operative method are the same as those for all other spinal operative treatment in trauma cases. But F.I. can be applied also in tumour, spondylolisthesis and degenerative cases.

References

1. Anden U, Lake A, Nordwall A (1980) The role of the anterior longitudinal ligament in Harrington rod fixation of unstable thoracolumbar spinal fractures. Spine 5: 23–31
2. Armstrong GWD, Johnston DH (1974) Stabilization of spinal injuries using Harrington instrumentation. J Bone Joint Surg 56 B: 590–598
3. Bedbrook GM (1979) Spinal injuries with tetraplegia and paraplegia. J Bone Joint Surg 61 B: 267–279
4. Convery FR, Minteer MA, Smith RW, Emerson SM (1978) Fracture-dislocation of the dorsolumbar spine. Acute operative stabilization by Harrington fixation. Spine 3: 160–169
5. Daniaux H (1982) Technik und Ergebnisse der transpedikulären Spongiosaplastik bei Kompressionsbrüchen im Lendenwirbelsäulenbereich. Acta Chir Austr [Suppl] 43: 79–80

6. Dick W (1984) Innere Fixation von Brust- und Lendenwirbelbrüchen. Hans Huber, Bern Stuttgart Wien
7. Dick W, Kluger P, Magerl F, Wörsdörfer O, Zäch G (1985) A new device for internal fixation of thoracolumbar and lumbar spine fractures. The "Fixateur Interne". Paraplegia 23: 225–232
8. Frankel HL, Hancock DO, Hyslop G, Melzak J, Michaelis LS, Ungar GH, Vernon JDS, Walsh JJ (1969) The value of postural reduction in the initial management of closed injuries of the spine with paraplegia and tetraplegia. Paraplegia 7: 179–186
9. Gertzbein SD, Macmichael D, Tile M (1982) Harrington instrumentation as a method of fixation in fractures of the spine. A critical analysis of deficiencies. J Bone Joint Surg 64 B: 526–534
10. Harrington PR (1967) Instrumentation in spine instability other than scoliosis. S Afr J Surg 5: 7–18
11. Harrington PR, Dickson JH (1973) The development and further prospects of internal fixation of the spine. Israel J Med Sci 9: 773–781
12. Hasday CA, Passoff TL, Perry J (1983) Gait abnormalities arising from iatrogenic loss of lumbar lordosis secondary to Harrington instrumentation in lumbar fractures. Spine 8: 501–509
13. Herrmann HD (1979) Transarticular (transpedicular) metal plate fixation for stabilization of the lumbar and thoracic spine. Acta Neurochir (Wien) 48: 101–110
14. Holm ST, Nachemson A (1982) Nutritional changes in the canine intervertebral disc after spinal fusion. Clin Orthop 169: 243–252
15. Jacobs RR, Casey MP (1984) Surgical management of thoracolumbar spinal injuries. Clin Orthop 189: 22–35
16. Jacobs RR, Schlaepfer F, Mathys R Jr, Nachemson A, Perren SM (1984) A locking hook spinal rod system for stabilization of fracture-dislocations and correction of deformities of the dorsolumbar spine. Clin Orthop 189: 168–177
17. Lesoin F, Rousseaux M, Bonnaskao N, Villette L, Thomas CE, Lama A, Jomin M (1986) Specific selection of osteosynthetic material in the treatment of thoracic or lumbar spinal injuries by the posterior approach. Acta Neurochir (Wien) 81: 118–124
18. Luque E (1982) Segmental spinal instrumentation for correction of scoliosis. Clin Orthop 163: 192–208
19. Luque E, Cassis N, Ramirez-Wiella G (1982) Segmental spinal instrumentation in the treatment of fractures of the thoracolumbar spine. Spine 7: 312–320
20. Magerl F (1982) External skeletal fixation of the lower thoracic and the lumbar spine. In: Uhlhoff HK (ed) Current concepts of external fixation of fractures. Springer, Berlin Heidelberg New York, pp 290–370
21. Magerl F (1984) Stabilization of the lower thoracic and lumbar spine with external skeletal fixation. Clin Orthop 189: 125–141
22. Muhr G, Tscherne H (1982) Die dorsale Plattenosteosynthese bei Wirbelfrakturen. Acta Chir Austr [Suppl] 43: 77–78
23. Ouchold WR, Weinstein SL, Sprague BL (1981) Thoracolumbar spine fractures: results of treatment. Spine 6: 13–22
24. Pentelényi T (1986) Up-to-date operative treatment of spine injuries. Magy Traumat Orthop 29: 198–214
25. Purcell GA, Markoff KL, Dawson EG (1981) Twelfth thoracic—first lumbar vertebral mechanical stability of fractures after Harrington rod instrumentation. J Bone Joint Surg 63 A: 71–78
26. Roy-Camille R, Saillant G, Berteaux D, Salgado V (1976) Osteosynthesis of thoracolumbar spine fractures with metal plates screwed through the vertebral pedicles. Reconstr Surg Traumat 15: 2–17
27. Roy-Camille R, Saillant G, Marie-Anne S, Mamoudy P (1980) Behandlung von Wirbelfrakturen und -luxationen am thorakolumbalen Übergang. Orthopädie 9: 63–75
28. White AA, Panjabi MM, Thomas CL (1977) The clinical biomechanics of kyphotic deformities. Clin Orthop 128: 8–21
29. Wörsdörfer O (1981) Operative Stabilisierung der Thorako-lumbalen Wirbelsäule: vergleichende biomechanische Untersuchungen zur Stabilität und Steifigkeit verschiedener dorsaler Fixationssysteme. Habilitationsschrift Klinisch-Medizinische Fakultät Ulm

Correspondence and Reprints: Thomas Pentelényi, M.D., C.Sc., Chief of Neurosurgery, National Institute of Traumatology, Department of Neurosurgery, VIII. Mező Imre ut 17, 1081 Budapest, Hungary.

A-22

Operative Orthopaedics

Volume 1

Edited by
Michael W. Chapman, M.D.
Professor and Chair
Department of Orthopaedics
University of California, Davis
Davis, California

Michael Madison, Ph.D.
Managing Editor

196 Contributors

J.B. Lippincott Company
Philadelphia
London Mexico City New York
St. Louis São Paulo Sydney

Acquisitions Editor: Darlene Barela Cooke
Developmental Editor: Richard Winters
Manuscript Editor: Patrick O'Kane
Indexer: Barbara Littlewood
Developmental Designer: Susan Blaker
Design Coordinator: Michelle Gerdes
Production Manager: Carol Florence
Production Coordinator: Barney Fernandes
Compositor: TAPSCO Inc.
Printer/Binder: Halliday Lithograph Corp.

Copyright © 1988, by J.B. Lippincott Company.
All rights reserved. No part of this book may be used or reproduced in any manner whatsoever without written permission except for brief quotations embodied in critical articles and reviews. Printed in the United States of America. For information write J.B. Lippincott Company, East Washington Square, Philadelphia, Pennsylvania 19105.

1 3 5 6 4 2

LIBRARY OF CONGRESS
Library of Congress Cataloging-in-Publication Data

Operative orthopaedics/edited by Michael W. Chapman; Michael Madison, managing editor.
p. cm.
Includes bibliographies and index.
1. Orthopedic surgery. I. Chapman, Michael W. II. Madison, Michael.
[DNLM: 1. Orthopedics. WE 168 061]
RD731.064 1988
617.3—dc19
DNLM/DLC
for Library of Congress 87-34225
CIP
ISBN 0-397-50919-7 (vol. 1)
ISBN 0-397-50920-0 (vol. 2)
ISBN 0-397-50921-9 (vol. 3)

ISBN 0-397-50772-0 (3 vol. set)

The authors and publisher have exerted every effort to ensure that drug selection and dosage set forth in this text are in accord with current recommendations and practice at the time of publication. However, in view of ongoing research, changes in government regulations, and the constant flow of information relating to drug therapy and drug reactions, the reader is urged to check the package insert for each drug for any change in indications and dosage and for added warnings and precautions. This is particularly important when the recommended agent is a new or infrequently employed drug.

CHAPTER 35

Fractures of the Tibial Plateau

JOSEPH SCHATZKER

Principles of Treatment
Indications for Closed Versus Open Management
Evaluation of the Injury
Surgical Approaches and Technique
Position of the Patient
Incisions
Fracture Reduction
Fixation
Postoperative Care
The Role of Continuous Passive Motion, Fracture Bracing, and Traction
Pitfalls and Complications
Assessment Errors
Timing
Inadequate Fixation
Conclusions

PRINCIPLES OF TREATMENT

Indications for Closed Versus Open Management

General Indications

The goals of treatment of intra-articular fractures are to restore a satisfactory range of motion, stability, and freedom from pain. Failure of treatment results in stiffness, deformity, pain, and post-traumatic arthritis. In order to avoid deformity and stiffness, anatomic reduction, stable fixation, and early motion are necessary.

A fracture of the tibial plateau is an intra-articular fracture of a major weight-bearing joint. It occurs as a result of a combination of lateral bending and vertical thrust. This mechanism of loading and fracture results in depression of the articular surface and shearing off of portions of the metaphysis. In addition to the fractures, the collateral ligament on the convex side of the deformity may rupture, and if the distraction of the joint is sufficient, the tibial eminence may be avulsed or one or both cruciate ligaments may rupture. Thus, in addition to the fracture, serious instability may occur secondary to collateral or cruciate insufficiency, or both. When part of an articular surface becomes depressed, a smaller portion of the articulation must bear all the weight. This increases the stress borne by the articular cartilage. If, in addition, there is axial malalignment as a result of the metaphyseal component of the fracture, the weight-bearing axis is shifted to the side of the depression. These two mechanisms of joint overload can, by themselves, give rise to post-traumatic osteoarthritis, even without considering the additive effect of articular cartilage damage sustained at the time of the injury, and the damage that could result from ligamentous insufficiency and instability. Instability may also be present as a result of joint depression and incongruity without ligamentous rupture. Thus, incongruity of the articular cartilage, axial malalignment, and instability may act together or singly to produce post-traumatic osteoarthritis.

For successful treatment of a tibial plateau fracture, the joint must remain stable, the articular surfaces must remain or be made congruous, and the joint must retain a satisfactory range of motion. My review of a large number of fractures of the tibial plateau that were treated nonoperatively suggested guidelines for the treatment of intra-articular fractures.[22,23] The patients in the series whose intra-articular fractures were immobilized in plaster for a month or longer had marked and permanent joint stiffness. In patients with similar fractures that were treated by open reduction and internal fixation with subsequent joint immobilization in plaster, the stiffness was both more pronounced and permanent. Patients with fractures that were treated by traction and early motion, with or without open reduction, experienced varying degrees of joint incongruity, but had satisfactory range of motion. The results of this review indicate that intra-articular fractures should never be immobilized in plaster. Whether operated on or not, the affected joints must be moved early. Whether traction is used will depend on the stability of the fracture.

Fractures that were treated by manipulation and traction often showed persistent displacement of some articular fragments. At surgery, these fragments were invariably impacted

firmly into the metaphyseal bone, requiring direct, forceful, surgical manipulation to be disimpacted and elevated to their anatomic position. Thus, any fragments that cannot be reduced with initial closed manipulation and traction will not reduce with further manipulation or traction. If these fragments are essential for joint stability, their persistent displacement is an absolute indication for open reduction and internal fixation.

A number of patients with displacement of major portions of articulations were operated on weeks to months after the fracture injury. In no patient did the articular depression fill with fibrocartilage to restore joint congruity and stability. It can thus be concluded that if a joint is unstable because of major joint depression and incongruity, the depression, incongruity, and instability will become permanent unless the fragment is reduced surgically and held in position until union occurs.

Therefore, the choice between open or closed treatment must be based on joint congruity, stability, and axial alignment. If there is instability, incongruity, or malalignment because of depression and metaphyseal deformity, a satisfactory result will be attained only by operative means. However, this general statement must be tempered by an assessment of the "personality" of each individual fracture, with consideration being given to the patient's age, lifestyle, and expectations of treatment; the particular features of the fracture in question; the surgeon's skill; and the adequacy of the support staff and environment.

Specific Indications

I have developed a classification system for fractures of the tibial plateau that groups them into six types.[22] Each type represents fractures that are similar in their pathogenesis and pattern, requiring similar treatment and having a similar prognosis.

Type 1 Fractures. Type 1 fractures are wedge-type fractures of the lateral tibial plateau (Fig. 35-1). They occur most frequently in young adults whose tibial condyle resists depression. If undisplaced, these fractures require early motion and simple protection from weight bearing in order to avoid displacement upon axial loading. If displaced, these fractures generally require open reduction and internal fixation. If the degree of displacement is insufficient to warrant an open reduction, then the joint must undergo arthroscopy to make certain that the lateral meniscus is not trapped in the fracture. In my experience, all patients with displaced fractures who were operated on had a trapped meniscus. Arthroscopic examination is the only certain method for detecting this potential complication. If the meniscus is trapped, open reduction and internal fixation should be performed, and the meniscus freed and repaired.

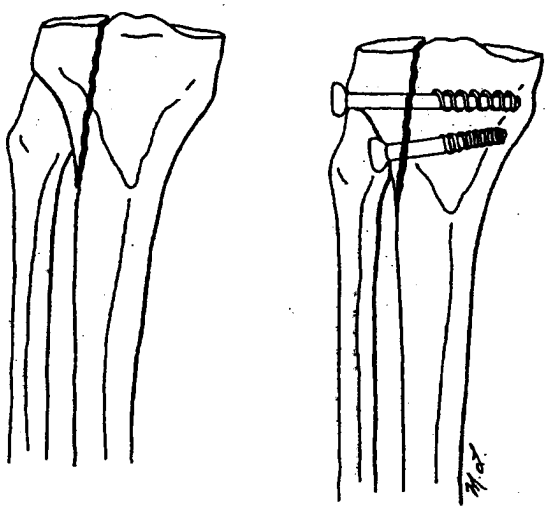

FIGURE 35-1. Type 1 fractures are wedge fractures of the lateral tibial plateau. The wedge is sheared off without any depression of the articular surface.

Type 2 Fractures. In type 2 fractures, fracture of the lateral wedge is accompanied by a varying degree of depression of the adjacent, remaining weight-bearing portion of the lateral tibial plateau (Fig. 35-2). The depressed segment may comprise the anterior, posterior, or middle portion of the tibial plateau, or it may be a combination of all three. The size of the wedge may also vary from a simple rim fracture to one involving a third or more of the plateau. The mechanism of fracture is the same as in type 1. The depression is the result of weakened bone failing under the compressive load. This type of fracture occurs in older patients, with the average age being about 50 years. Approximately 50% of these patients also have moderate degrees of osteoporosis.

If the depression of the articular surface does not exceed 4 mm, as measured against the intact medial plateau, open reduction is not necessary. A depression of greater than 4 mm is significant; if left unreduced, it will result in significant joint incongruity and instability. In the series of patients reviewed, all poor treatment results were attributable to residual joint depression, instability, and incongruity, either because these conditions were accepted initially, because the reduction was not perfect, or because redisplacement occurred during the postoperative period.[23] Closed manipulative reduction combined with traction, or traction alone, was associated with varying degrees of success. The displaced lateral wedge often reduced surprisingly well, but the anterior and posterior wedge fragments remained unaffected. Furthermore, the depressed articular portion could not be dislodged by closed technique. Thus, if instability was present as a result of persistent posterior rim fracture or central depression, it led to serious sequelae.

Certain displaced fractures were not operated on for a variety of reasons. These were initially treated by traction; once "sticky," a cast brace was used to maintain alignment until union was achieved. Once the cast brace was removed and weight bearing was commenced, the deformity tended to recur.

Thus, the cast brace is an excellent method of functional treatment, but it does not prevent recurrence of malalignment that is secondary to joint depression or metaphyseal malalignment. This type of malignment can be corrected only by open reduction. Any fracture with a significant lateral wedge component and central depression of greater than 4 mm should be operated on unless definite contraindications to surgery exist.

Type 3 Fractures. In type 3 fractures, a depression of the central portion of the lateral tibial plateau occurs without an

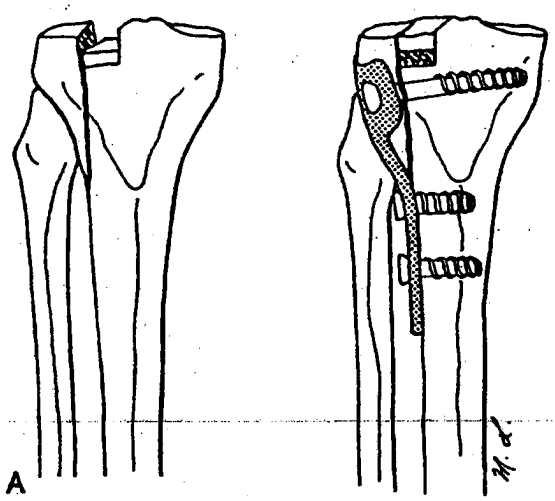

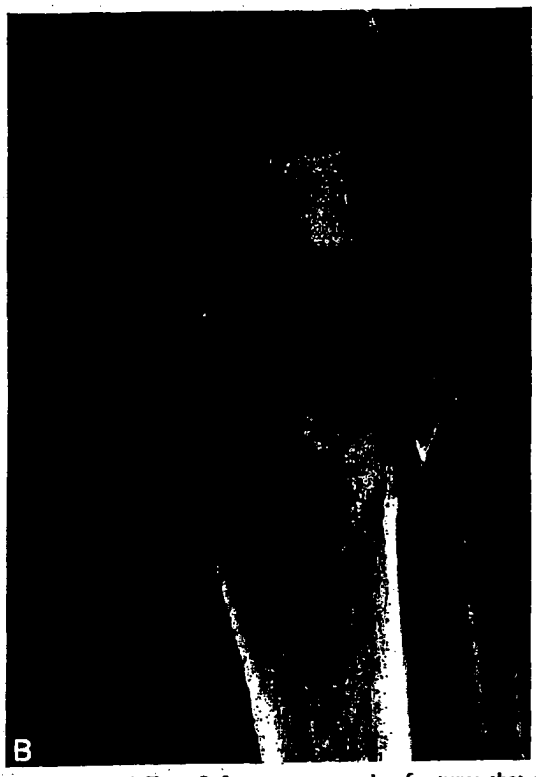

FIGURE 35-2. *(A)* Type 2 fractures are wedge fractures that are associated with depression of the articular surface. *(B)* Note the degree of articular depression.

associated wedge fracture (Fig. 35-3). These fractures are commonly the result of a low-energy force acting on weakened bone. Affected patients are generally older than those with type 2 fractures, with the average age being 55 to 60 years. These patients also have more severe osteoporosis than do their counterparts with types 1 and 2 fractures. Type 3 fractures are usually stable, and excellent function of the joint can be anticipated unless the depression involves the whole lateral plateau.

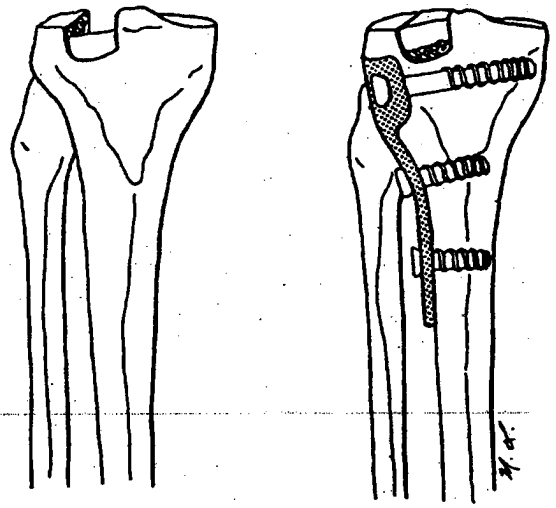

FIGURE 35-3. Type 3 fractures are characterized by central depression of the lateral tibial plateau.

If this is the case, open reduction and internal fixation are necessary to restore joint stability and alignment. If the fracture is at all significant, the joint must be examined under anesthesia to ensure stability and selection of the correct treatment. The joint must be stressed into a valgus position from full extension to 90° of flexion. If instability is demonstrated, surgery may be indicated, depending on the degree of instability and other factors, such as the patient's age or the presence or absence of osteoporosis.

Type 3 is the most common fracture pattern. In my experience, the few patients who have required an open reduction and internal fixation did well as long as joint congruity was restored and maintained until union occurred.

Type 4 Fractures. Type 4 fractures involve injury of the medial tibial plateau (Fig. 35-4). They occur either as a result of a high-velocity injury, or in association with less forceful trauma in elderly or osteoporotic patients. Fractures in patients who are injured as a result of high-velocity trauma are associated with a poor outcome because of concomitant injury to the soft tissues. The medial plateau requires a greater force to fracture than does the lateral plateau; thus, the associated violence is greater. The varus thrust results in a simple wedge split, similar to that which occurs in lateral type 1 fractures. However, in addition, there is often an associated fracture of the intercondylar eminence and the adjacent bone with the attached cruciate ligaments. These ligaments may rupture without avulsing the eminence. Furthermore, there is often a concomitant rupture of the lateral collateral complex, common peroneal nerve, and sometimes, disruption of the popliteal vessels. An injury of this magnitude represents a knee dislocation that has been realigned (see Chapter 128). Even if the medial plateau is undisplaced, these lesions often require surgery because of the associated disruption of soft tissues. Their poor prognosis is not attributable to the bony component, but rather is the result of the soft tissue injuries that may cause chronic knee instability, peroneal nerve palsy with a foot drop and dysesthesia, or

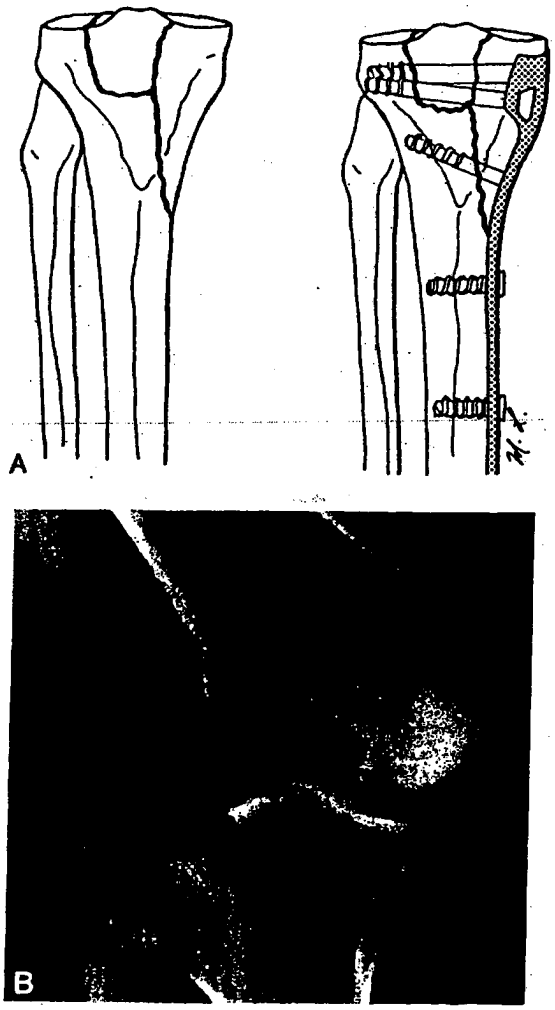

FIGURE 35-4. (*A*) Fracture of the medial tibial plateau. Note the associated fracture of the intercondylar eminence. (*B*) Note that the knee is dislocated.



FIGURE 35-5. (*A*) A bicondylar fracture. Frequently, the fracture lines are extra-articular. (*B*) In this example, the fracture involves the articular surface.

Volkmann's ischemic contracture secondary to the popliteal injury. In the elderly, the poor prognosis is often attributable to crumbling of a severely osteoporotic medial plateau which cannot be reconstructed surgically.

Type 5 Fractures. Type 5 fractures are wedge fractures of the medial and lateral plateau (Fig. 35-5*A*). They are often the result of a vertical thrust and a shearing of the two plateaus by the femoral condyles. The fracture lines may be extra-articular; that is, they may begin centrally close to the eminence, sparing the articular cartilage. Because of the attachment of the respective collateral ligaments and capsule to the sheared fragments, traction frequently effects an acceptable reduction. Thus, these fractures can often be managed with traction until they become "sticky," when transfer into a cast brace is indicated. When perfect alignment has not been maintained in young and athletic patients, we have performed open reduction because the slight shortening that tends to occur with spreading of the tibial condyles leads to a relative lengthening of the collateral soft tissue hinges. The resultant varus/valgus instability is not compatible with high-demand function. In patients in whom the fracture line begins within the articular cartilage (Fig. 35-5*B*), an anatomic reduction cannot be achieved with traction. Closed reduction has no role in the treatment of this subgroup of type 5 injuries.

Type 6 Fractures. The hallmark of a type 6 fracture is a fracture line that separates the metaphysis from the diaphysis (Fig. 35-6*A*). In addition, these fractures usually have a complex pattern, with involvement of both the medial and lateral plateaus. The separation of the metaphysis from the diaphysis

makes this fracture less amenable to closed treatment, since traction often results in a separation of these two, with little effect on the alignment of the articular components of the injury (Fig. 35-6*B*). Therefore, this severe injury almost always requires surgical intervention. A word of caution is in order, since these fractures may, at times, be so complex as to daunt even the most expert surgeon. Hence, an initial, careful evaluation is necessary to define their "personality." If there is doubt as to whether an open reduction would be successful, closed treatment is preferable to a failed open reduction despite the former's limitations. Despite the severity of type 6 fractures, 80% of the patients in my series who underwent an open reduction and internal fixation had a satisfactory result.[25]

In addition to the considerations underlying closed or open treatment that have already been mentioned, there are a number of other instances in which operative treatment is indicated, either because of the nature or the potential effects of the injury.

Open Fracture. Stability, in addition to debridement, is the mainstay of prophylaxis against sepsis. Therefore, open reduction and stable internal fixation of an open intra-articular fracture is mandatory.

Acute Compartment Syndrome. If conversion of a closed fracture to an open fracture must be undertaken to decompress a compartment, it is best to perform an open reduction and internal fixation of the associated fracture. In this case, one strives not only to prevent sepsis of the previously closed fracture, but also to simplify the logistics of caring for the injury. Closed treatment of the fracture becomes difficult if one must also care for the wounds associated with the compartment decompression.

Associated Vascular or Neurologic Injuries. Vascular or neurologic injuries are most frequently associated with type 4 fractures. Once the vascular disruption is repaired, the associated fractures should be stabilized and the ligaments repaired.

Evaluation of the Injury

History

The importance of an accurate evaluation of the patient and of the specific injury cannot be emphasized enough. An accurate diagnosis is the basis for successful treatment.

Although the patient is rarely able to relate the exact mechanism of injury, valuable clues may be obtained by determining whether the injury was of high or low velocity. Similarly, certain clinical parameters, such as numbness or pain, are also key factors to determine.

Physical Examination

The condition of the soft-tissue envelope can be determined only by careful physical examination. The same applies to eliciting tenderness, as well as to determining whether a collateral ligamentous tear, vascular injury, neurologic deficit, or acute compartment syndrome is associated with the fracture.



FIGURE 35-6. (*A*) The hallmark of a type 6 fracture is the separation of the metaphysis from the diaphysis. (*B*) Because of the fracture across the metaphysis, traction frequently fails to bring about any reduction of the articular component.

Radiographic Examination

An x-ray study is the only accurate method for determining fracture pattern and severity. The standard anteroposterior and lateral projections alone are inadequate, and must be supplemented with internal and external oblique projections (Fig.

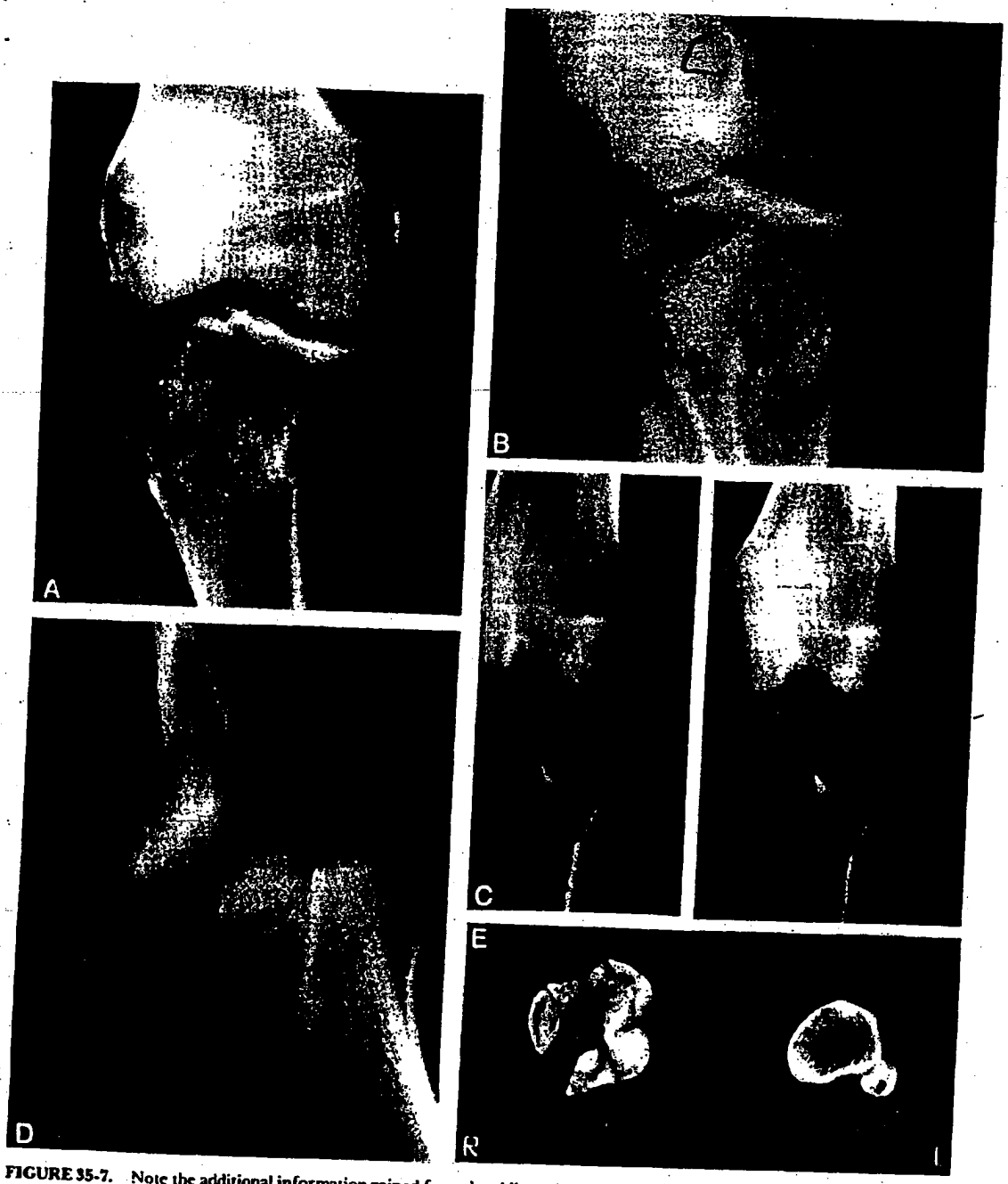

FIGURE 35-7. Note the additional information gained from the oblique (internal/external) projection with regard to the degree of joint depression. (*A*) Anteroposterior view. (*B*) Oblique view. (*C* and *D*) Computed tomography (CT) reveals obscure fracture lines, as well as the degree of comminution and fragment displacement. (*E*) CT scan of a tibial plateau fracture. Note the cross-sectional anatomy of the fracture.

35-7, *A* and *B*). Frequently, the true degree of plateau depression is best seen on an oblique projection. Often, tomography n the anteroposterior and lateral plane (Fig. 35-7, *C* and *D*) is lso necessary, particularly in complex injuries, in order to letermine accurately the extent and position of all fracture ines, as well as the degree of comminution and displacement of the fragments and the degree of articular depression. These examinations are not exclusive of one another, but rather are complementary, providing the surgeon with an accurate, three-dimensional view of the fracture upon which its operability can be judged. In complex fractures, computed tomography (CT) scanning may also be helpful. These examinations

shed much light on the cross-sectional anatomy of the fracture[5] (Fig. 35-7*E*).

SURGICAL APPROACHES AND TECHNIQUE

Position of the Patient

Position the patient supine in such a way that the end of the table can be lowered during the procedure and the knee flexed. Flexion of the knee improves visualization of the joint, and the flexed, dependent leg provides traction. Furthermore, this position obviates the need for an assistant to hold the leg. Moreover, the dependent position of the leg allows the surgeon to control varus or valgus positioning simply by pushing the foot in the desired direction.

Incisions

Specific Approaches to the Joint

The essence of a good surgical approach is maximal visualization with minimal devitalization of the fragments, together with the preservation of all important structures. I have abandoned all curved and triradiate incisions about the knee. The best skin incisions are the ones made as close to the midline as possible. Thus, I make a medial or lateral parapatellar incision or, if simultaneous exposure of both plateaus is necessary, I make a midline incision as for total joint arthroplasty. The flaps that are raised must be full thickness, extending to the fascia and retinacular expansions. This ensures their survival and prevents necrosis at the edge of the wound.

Preservation of the Meniscus

In order to visualize the articular surfaces, incise the capsule horizontally, just beneath the meniscus. An arthrotomy made above the meniscus, as in routine joint exploration, allows perfect visualization of the meniscus, but the meniscus completely obscures the underlying articulation. One must preserve the meniscus in surgically exposing the tibial plateau, and a meniscectomy should never be performed. If the meniscus is torn, resuture and preserve it if at all possible. The meniscus shares in weight transmission and distributes the weight over a broader surface area.[27] This cushioning effect also protects the elevated fragments of articular cartilage and enhances cartilage healing. At the end of the surgical procedure, carefully repair the horizontal arthrotomy made at the time of exposure.

To expose the depressed articular fragments in the most atraumatic way, make use of the fracture. If there is a peripheral wedge fragment, use its soft tissue attachment as a hinge, folding it back like the cover of a book. This allows perfect visualization of the joint depression without interfering with the blood supply to the bone.

Posterior Incision

If it is difficult to expose a posterior fragment through an anterior incision, make a second posterior incision. Usually, if the anterior incision is extended and the knee flexed, it is possible to reach the posterior portion of the joint.

Reflection of the Ligament

Preserve the collateral ligaments. On the lateral side, however, cut across the iliotibial tract in order to gain unobstructed access to the joint. At the end of the procedure, resuture the iliotibial band. I have done this many times without subsequent varus instability.

Occasionally, in severe injuries involving both tibial plateaus, it may be necessary to expose the whole articulation of the proximal tibia in order to reconstruct the joint. This can be done only if the quadriceps mechanism is transected because, with a shattered proximal tibia, it is not possible to dislocate the patella laterally without causing difficulty with reduction. The best technique for reflecting the quadriceps tendon upward is to incise the infrapatellar tendon longitudinally, dividing one-half proximally and one-half distally. This allows simultaneous visualization of both sides of the joint. I prefer to divide the tendon, suture it at the end, and protect it with a tension band wire (see Fig. 34-2) rather than osteotomizing the tibial tubercle to achieve the same result. At times, the tibial tubercle is the only intact portion of the anterior tibia. If the posterior cortex is also comminuted, it may become impossible to reattach an osteotomized tubercle.

Fracture Reduction

By virtue of ligamentotaxis, traction facilitates reduction. This factor is particularly useful in badly comminuted fractures. In such cases, insert one limb of an AO distractor into the medial femoral condyle and the other into the shaft of the tibia distal to the fracture (Fig. 35-8). Then distract the fragments before any formal exposure is undertaken. The reduction obtained by this method will greatly facilitate subsequent procedures.

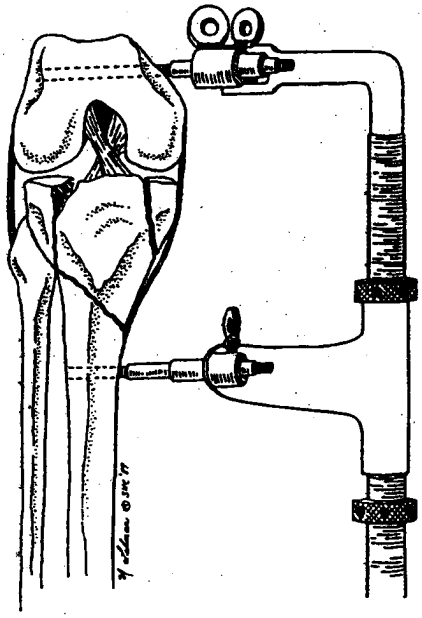

FIGURE 35-8. One limb of the AO distractor is inserted into the medial condyle while the other is inserted into the subcutaneous anteromedial surface of the tibia. Instead of using the distractor to connect both, 5.0-mm Schanz screws can be utilized. The AO tubular external fixator can also be substituted for the distractor.

Never elevate the depressed articular fragments one at a time; instead, elevate them *en masse* from below. If an attempt is made to lift the fragments up through the joint, the result is usually a number of totally devitalized, loose, articular fragments that cannot be put back and fitted together. If, instead, the fragments are collectively elevated from their impacted position in the cancellous bone of the metaphysis using a bone punch, they do not fall apart, but behave as if they were one unit. To initiate the elevation, insert a periosteal elevator deeply into the compacted cancellous bone of the metaphysis below the fragments. Then, with upward pressure, dislodge the whole segment and complete the reduction with a punch, as described (Fig. 35-9).

Fixation

Bone Grafts

Autogenous Grafts. Once the fragments are elevated, they must not be allowed to fall back, either at the time of surgery or, more commonly, during the healing process. Two maneuvers are helpful in this regard. The first is to insert a massive bone graft below the fragments into the hole in the metaphysis that was created when the fragments were elevated. The second is to compress the fragments circumferentially using the remaining intact portions of the plateau. This maneuver is accomplished by inserting lag screws so that, when they are tightened, they will tend to squeeze and narrow the proximal tibia. To prevent the fragments from falling back either at the time of compression or subsequently, a filler or bone graft must be inserted. I prefer to use a compacted autogenous cancellous graft for this purpose because it not only rapidly revascularizes, but it also retains all of its inductive properties. I also prefer cancellous bone because it adapts itself to the shape of the defect. Corticocancellous blocks are useful in the reconstruction of metaphyseal nonunions because they have greater structural strength and can be made to fit certain large defects. This structural strength is not required in a fresh fracture, and the sculpturing of the graft makes it more difficult to use than soft cancellous bone, which can be compacted to give it strength and which automatically adapts itself to the shape of the defect.

Allografts. Cancellous allograft provides satisfactory union in well-vascularized cancellous bone.[9] I have used it in osteoporotic elderly patients whose iliac crests have been poor sources of bone. Allograft, although it acts as a filler, lacks the inductive potential of autograft and is more likely to be successful in young patients.

Synthetic Bone Spacers. I have used methylmethacrylate successfully to fill metaphyseal defects of pathologic fractures. However, bone cement must not be used directly under articular fragments because destruction of the overlying articular cartilage may ensue.[15] If the patient is elderly or seriously ill and the life expectancy is short, increasing the stiffness of the subchondral bone by using bone cement will not lead to destruction of the articular cartilage within the patient's life span. However, if the patient has a long life expectancy, cement must not be used except when there is a viable layer of bone separating the cement from the articular cartilage. Although I have not used any commercial bone substitutes in this location, caution is warranted. If the material is hard, its stiffening effect on the overlying articular cartilage may lead to cartilaginous destruction, as occurs with bone cement.

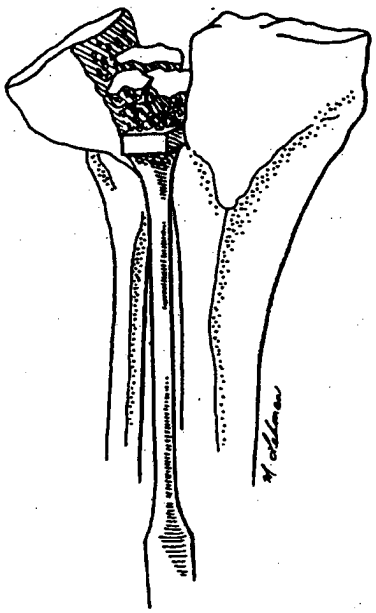

FIGURE 35-9. Note that an *en masse* elevation of fragments consists of insertion of a bone punch deep to the depressed fragments. Upward blows on the punch effect the reduction.

Internal Fixation

Interfragmental Compression and Buttressing. Internal fixation of a tibial plateau fracture involves four distinct steps. The first is anatomic reduction of the articular surface, involving disimpaction of the fragments from their impacted position, provisional fixation with Kirschner wires, and bone grafting of the defect in the metaphysis. The definitive steps in internal fixation include lagging the fragments together and applying interfragmental compression to achieve stability. In the final step, the associated fracture of the metaphysis is buttressed after reduction to prevent collapse and deformity secondary to axial loading.

Any plate, if it is carefully contoured to the shape of the underlying bone, can be made to function as a buttress plate. Because metaphyses of different bones have specific shapes, some implant designers, like AO/ASIF, provide several precontoured buttress plates. For the proximal tibia, the "T" plate, which fits best on the medial side, is used. For the lateral side, there is the "T buttress" plate and the "L" plate, which comes in a right and a left design (Fig. 35-10). Buttress plates must be adjusted carefully to fit the underlying cortex. If a plate does not fit, and it is first fixed to the bone at its ends, then as the middle part of the plate is fixed, it can inadvertently be placed under tension, causing the deformity it was intended to prevent. Therefore, whenever a buttress plate is fixed to bone, the first screws to be inserted should be the distal screws

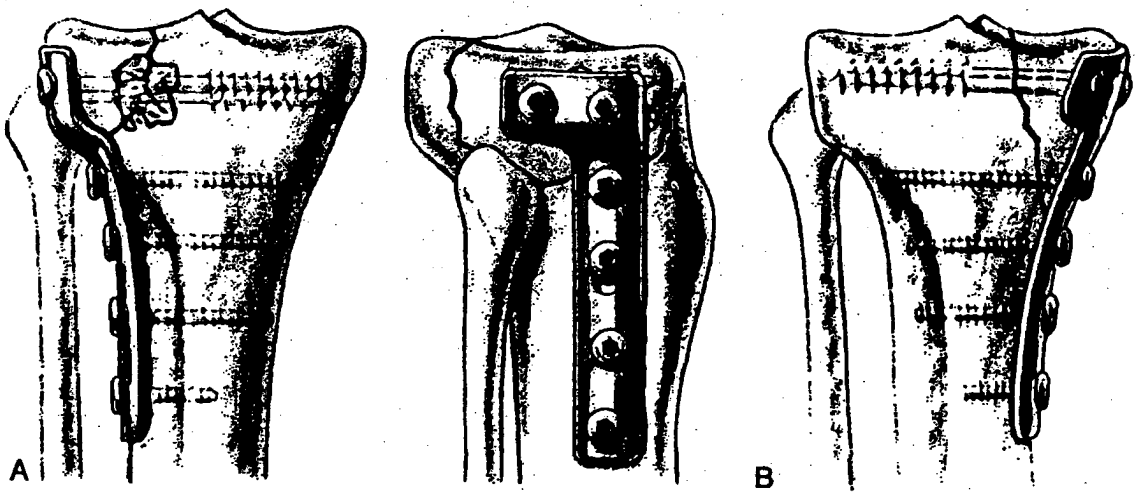

FIGURE 35-10. Note that the "T" plate fits best on the medial side and that the "T buttress" plate and the "L" plate fit best on the lateral side. Note also that the "L" plates come in a right and a left design. (Müller, M. E., Allgöwer, M., Schneider, R., et al: Manual of Intenal Fixation. New York, Springer-Verlag, 1979.)

and the remainder should be inserted in an orderly fashion, one after another, progressing toward the joint.

On the medial side, the plate is applied to the anteromedial surface of the bone deep to the pes anserinus. On the lateral side, the plate is applied anterior to the fibula. Thus, the "L" plate allows for more lateral buttressing than the "T" plate. The most proximal screws are usually long, cancellous screws that double as lag screws for the articular component of the fracture. If the articular component has already been fixed, then the proximal screws can be omitted. The function of the plate is to buttress the fracture site; to fulfill this function, it must rail or support the cortex, but it need not be fixed to the proximal fragment.

Internal Fixation of Shaft and Plateau Fractures. In type 5 and type 6 fractures, begin with fixation of the less comminuted side so that it can be reduced and fixed, even if only provisionally, while the more comminuted side is being reconstructed. As in the distal tibia, it is first necessary to reestablish normal length; this is easiest to accomplish on the side of least comminution. For provisional fixation, first fix the buttress plate to the cortex distally. Then fix the plate to the reduced plateau fragment with short cancellous screws, which should be directed posteriorly so as to engage the posterior cortex. This may, incidentally, be the only intact portion of the proximal tibia.

Occasionally, the comminution may be so severe that it is virtually impossible to reconstruct either side. Under these circumstances, it is probably best not to attempt surgical reconstruction because of the inherent technical difficulties. However, I have found the following technique to be useful in such instances. I have fixed a long "T" plate to the cortex on the medial side and a similar "T buttress" plate on the lateral side. I have then used the two plates like a scaffolding, between which I have erected the fragments to rebuild the proximal tibia. To complete the procedure, pass a bar bolt through the holes of the two plates proximally to tie them together and to maintain the shape of the proximal tibia.

Tourniquet Use. Whenever possible, I prefer to perform articular reconstructions with the limb exsanguinated and a pneumatic tourniquet inflated. With this technique, bleeding is controlled and visualization is greatly improved, thereby facilitating an accurate articular reconstruction. In order to shorten tourniquet time and to decrease the period during which the tibial wound is left open, I prefer to obtain cancellous bone from the donor site and close that incision before the tibial reconstruction is begun.

Specific Fracture Types. Type 1 wedge fractures can usually be fixed with lag screws alone provided the patient is young and the bone is dense and strong. If this type of fracture occurs in an older patient, it is best to protect the lateral cortex with a buttress plate in order to prevent deformity secondary to axial loading.

In type 2 fractures, the bone is usually weakened as a result of either osteoporosis or comminution. One cannot, therefore, rely even on lag screw or bar bolt fixation, in young individuals. A buttress plate is always necessary to prevent axial displacement. As already mentioned, fixation of the articular fragments depends on bone grafting of the defect in the metaphysis and lag screw fixation of the fragments.

Type 3 fractures rarely require open reduction. If the depression is such that instability is present and reduction is necessary, elevation of the fragments is best accomplished in the following manner. Fenestrate the lateral cortex of the plateau on the side at a level judged to be below the lowest depression. Insert a bone punch through the window and gently punch the depressed articular fragments back into place (Fig. 35-11). Maintain placement of the fragments by tightly packing cancellous bone into the defect beneath them. Lag screw fixation is difficult in such cases because the proximal tibia cannot be

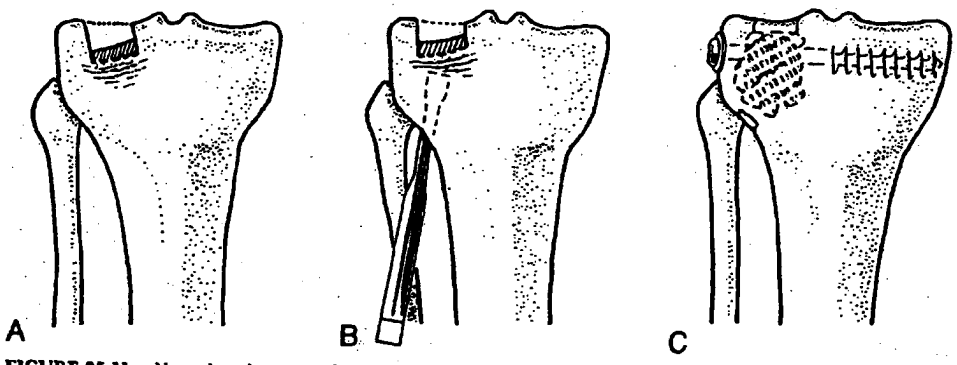

FIGURE 35-11. Note that the cortex is fenestrated on the underside of the tibial condyle below the depressed fragments. (Müller, M. E., Allgöwer, M., Schneider, R., et al: Manual of Intenal Fixation. New York, Springer-Verlag, 1979.)

squeezed together with the peripheral cortex intact. If the lag screw is passed under the fragments, it will help keep them in place. The fenestrated cortex requires buttressing, as the window weakens it substantially, causing fatigue with axial loading.

Type 4 fractures of the medial plateau, depending on their size, should be stabilized with one or two lag screws. The cortex almost always requires buttressing. This is best done with a "T" plate. Position the "T" plate on the anteromedial surface of the tibia deep to the pes anserinus and the anterior fibers of the medial collateral ligament. Fix the avulsed intercondylar eminence either with a lag screw or a tension band that is passed through two holes in the proximal anterior tibia and then tied in front (Fig. 35-12). If the proximal fibula is avulsed with the lateral collateral ligament, good reattachment can be achieved with either a lag screw or a tension band. In elderly patients with severe osteoporosis in whom the tibial plateau crumbles, open reduction and fixation is rarely possible because of technical difficulties, even if the patient is an acceptable operative risk. These patients are best treated initially by traction and subsequently transferred into a cast brace when their fracture becomes "sticky."

Type 5 fractures rarely require fixation. As already indicated, exceptions include young patients, or patients in whom a fracture line traverses the articular surfaces. In these instances, open reduction and internal fixation are required to ensure optimal recovery. Fix the two plateau fragments with lag screws and buttress the medial and lateral cortex. Usually I have used "T" plates, one on each side, to accomplish this, but the type of plate used is best determined by the configuration of the fracture. In the metaphyseal areas, the plates need not be very heavy.

In type 6 fractures, the metaphysis is disassociated from the diaphysis. The type of fixation required depends on the extent and level of this fracture. If the fracture is in the metaphysis, then a long "T" plate is usually sufficient, particularly if two plates are to be used. If the fracture is more distal, then a "T" plate cannot be employed because it is too weak an implant to neutralize a shaft fracture. Under these circumstances, a combination of a short buttress plate and a longer, 4.5-mm dynamic compression plate is indicated. The latter will be used either as a compression plate or a neutralization plate, depending on the configuration of the fracture.

The Role of Arthroscopy

As already mentioned, arthroscopy plays a role in the preoperative evaluation of type 1 fractures when determining whether the meniscus is caught in the fracture. This is the only justifiable role for the arthroscope in the management of tibial plateau fractures. Arthroscopy cannot be performed with the same degree of sterility as open reduction of a fracture. Thus, little can be gained by first reducing the articular component of the fracture with the aid of the arthroscope and then opening the fracture, since buttressing of the metaphysis always requires exposure of the bone. Use of the arthroscope drastically increases the risk of sepsis, making the combined use of these two techniques indefensible.

POSTOPERATIVE CARE AND REHABILITATION

The Role of Continuous Passive Motion, Fracture Bracing, and Traction

Salter's research[30] on the effects of continuous passive motion on regeneration of articular cartilage has made this treatment mode an indispensable adjunct in the rehabilitation of intra-articular injuries. Immediately upon completion of the surgical procedure, apply a light, unobstructive dressing to the extremity and position the extremity on a continuous passive motion machine. Set the machine to cycle from full extension to at least 60° of flexion. The amount of flexion is gradually increased so that, within 24 to 48 hr, the machine will cycle to at least 90° of flexion. Patients do not tolerate rapid cycling. I have found that approximately one full flexion and extension every 2 min is a comfortable pace. Usually, at the end of the first week, it is possible to discontinue continuous passive motion. Patients are then able to continue their rehabilitation program without reliance on passive aids. With the use of continuous passive motion machines, patients regain flexion rapidly; however, they often lose power in their quadriceps, so that an initial extensor lag is common. I advocate the use of Farradic stimulation during the extension phase in conjunction with the continuous passive motion machine. This has facilitated recovery considerably.

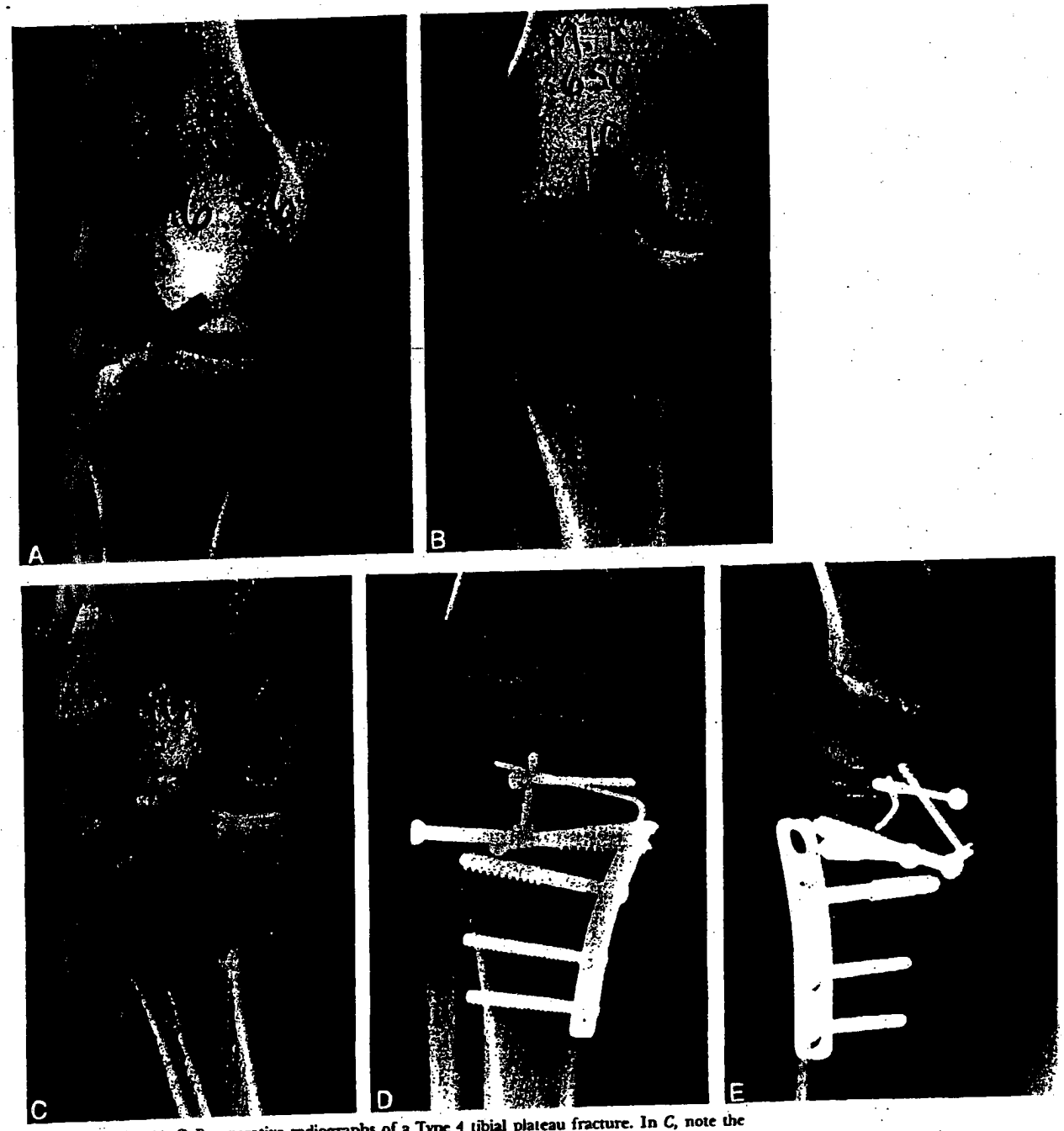

FIGURE 55-12. (*A–C*) Preoperative radiographs of a Type 4 tibial plateau fracture. In *C*, note the oblique projection, providing improved visualization. (*D* and *E*) Six months following surgery, note position (in *E*) of the buttress plate on the posteromedial side of the tibia. This is because the fragment of the medial condyle was medial and posterior. Also note the two lag screws that were inserted anterolaterally and directed posteromedially. They exerted the interfragmental compression for stabilization of the fragment. The buttress plate protected the fixation from axial load. The top screw was left out as it is unnecessary in a buttress plate. Note also the small fragment, 4.0-mm, lag screw that has been directed upward to hold the intercondylar eminence and the attached anterior cruciate ligament. The other lag screw and Kirschner wire were used to fix comminution of the articular surface.

If a continuous passive motion machine is unavailable, splint the knee in 60° of flexion for 24 to 36 hours, after which active mobilization should commence. Do not immobilize the knee in full extension after open reduction of a fracture because it is then extremely difficult to initiate and regain flexion.

The details of postoperative care other than early motion depend on the findings at surgery, as well as on the stability of the fixation achieved. If stable fixation has been achieved, then once the joint is mobilized on a continuous passive motion machine, the patient continues with active exercises without any added protection. If the reduction is deemed satisfactory, but fixation is less than ideal, then once the joint is mobilized, I protect the fixation of the fracture by means of a cast brace and allow the patient to proceed with active mobilization. The same regimen applies to collateral ligament repair. I do not believe in performing substantive repair of tears of the cruciate ligaments or primary substitutions because they demand restriction of the joint excursion in order to protect the repair. In the presence of a fracture, this results in an unacceptable loss of motion or in a protracted period of rehabilitation. The only primary repair of cruciates I perform is reattachment of bony avulsions. The fixation of these can be made sufficiently sound to permit early mobilization (Fig. 35-13, *D* and *E*).

Upon completion of open reduction and internal fixation, if the surgeon deems the fixation to be so poor as to be unsuitable for cast bracing, then the joint must be mobilized in traction. Never immobilize a joint that has undergone open reduction and internal fixation of an intra-articular fracture in plaster. The resultant stiffness is unacceptable.

Regardless of the stability of the reduction, I do not allow weight bearing for 10 to 12 weeks; at times, in severely comminuted fractures, I have extended this period to 14 or 16 weeks until I have been satisfied that union has occurred. Early weight bearing can interfere with the healing of articular cartilage, and it can lead to the displacement of the articular reduction or of the metaphyseal component of the fracture, or both.

PITFALLS AND COMPLICATIONS

Assessment Errors

The most common pitfall in the management of fractures of the tibial plateau is an incomplete clinical and radiographic evaluation. An exact open reduction and internal fixation, particularly in a complex injury, is possible only if all the facets of the injury have been recognized and evaluated, and a careful decision has been made as to the appropriate mode of treatment. Preoperative planning, including consideration of all the surgical steps necessary to expose, as well as fix the fracture, is then possible. Visualization has never been greater at surgery than with good quality radiographs or tomograms. For com-

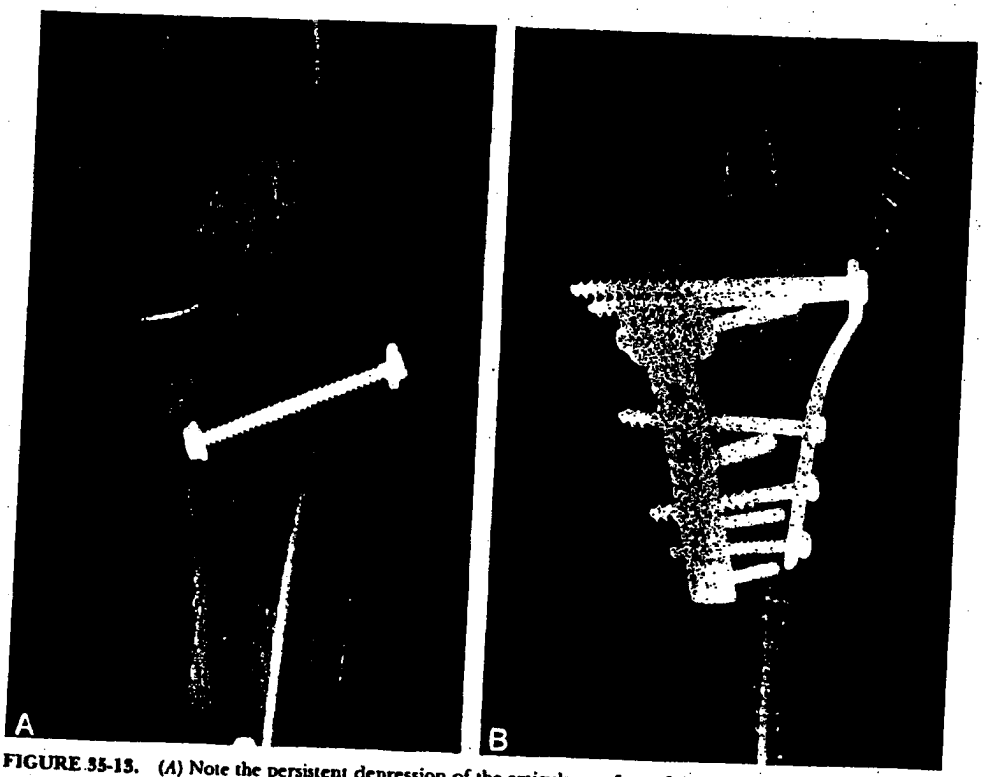

FIGURE 35-13. (*A*) Note the persistent depression of the articular surface of the lateral plateau, the malreduction of the wedge of the lateral plateau, and the varus alignment of the knee, with the anatomic axis of the femur and tibia being parallel. (*B*) Surgical reconstruction was performed 3 weeks following the fracture and the ill-conceived internal fixation. This elderly patient shows evidence of preexisting osteoarthritis of the knee.

plex injuries, I have even occasionally resorted to a CT scan. Surgeons who explore a fracture without a careful plan and who try to make therapeutic decisions as they proceed are to be condemned, for they will more often be wrong than right.

Timing

There are only three situations when a tibial plateau fracture must be treated as an emergency: an open fracture, a fracture associated with an acute compartment syndrome, and a fracture associated with a vascular injury. In the remainder of cases, the optimal timing for reconstruction of a tibial plateau must be based on such factors as the condition of the patient, any other associated injuries, the status of the limb, and finally, the state of the soft-tissue envelope.

At times, initial swelling or contusion of the soft-tissue envelope may be severe enough to preclude an early surgical repair. If a delay of more than a day or two is anticipated, then the patient should be placed in skeletal traction with the traction pin inserted at least a handsbreadth below the lowest recognizable fracture line. This will ensure that the traction pin will not be included in the surgical exposure when open reduction is performed. If there are no contraindications, repair of simple plateau fractures may be undertaken as soon as is practical. In more complex injuries, I prefer to wait until special radiographic views, tomography, and sometimes, a CT scan, as well as a careful preoperative evaluation, have been completed and a plan has been formulated.

Inadequate Fixation

In the past, tibial plateau fractures were fixed with bar bolts. This inadequate and ill-conceived mode of fixation continues to be used by some surgeons with predictably poor results (Fig. 35-13). Even when combined with traction, a bar bolt cannot ensure sufficient stability to prevent at least partial redisplacement (Fig. 35-14). Similarly, lag screws alone cannot ensure stability. Except in the case of a type 1 fracture in a young adult, the cortex should always be buttressed.

Repair of complex fractures of the tibial plateau requires considerable surgical expertise. Therefore, these fractures are probably best treated by traction unless the surgeon has had

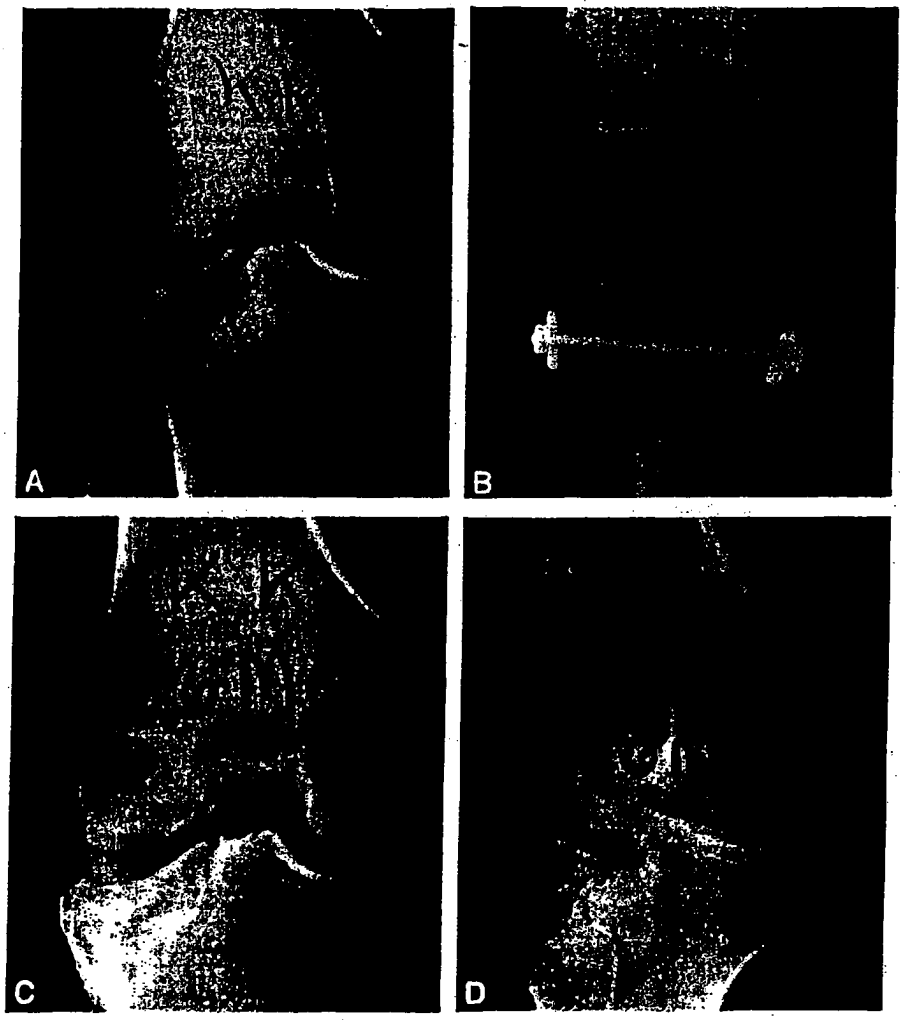

FIGURE 35-14. (*A*) A Type 2 fracture of the lateral plateau with depression. (*B*) This fracture was treated by reduction bar-bolt fixation and four weeks of traction. (*C* and *D*) Note that despite traction, inadequate fixation of the bar-bolt led to redisplacement of the articular surface.

extensive experience with intra-articular fractures of the proximal tibia. The anatomy may be so severely distorted by the injury that reduction may be extremely difficult. Except for sepsis, inadequate fixation of an incompletely reduced fracture is associated with the worst prognosis possible.

Following open reduction and fixation, if a significant loss of position is recognized during the postoperative period or during convalescence, a revision should be undertaken. This is because a malunion is incompatible with normal function.

Another frequent pitfall is failure to use bone grafts when indicated. As I have emphasized, grafting is done not to ensure union, but to be certain that the elevated articular portions remain in their reduced position. As plateau fractures traverse well-vascularized bone, nonunion of this fracture is very rare.

CONCLUSIONS

Fractures of the tibial plateau are intra-articular fractures of a major weight-bearing articulation. Thus, to preserve normal function, joint congruity, axial alignment, stability, and a satisfactory range of motion must be achieved. If the fracture is stable, the joint congruous, and axial alignment is preserved, then closed treatment is the method of choice. Even with closed treatment, early motion must be instituted or stiffness will ensue. Joint incongruity and instability are clear indications for open reduction and stable internal fixation. Of the patients reviewed,[23] the majority sustained these fractures in their fifth or sixth decade, and at least 50% had some degree of osteoporosis. Osteoporosis, unless very severe, is not a contraindication to surgery. More than 50% of the patients in this series who underwent open reduction and internal fixation had osteoporosis; yet this did not affect the outcome of surgery in any of them. Patients who underwent open reduction and internal fixation had, on the average, three times as severe a joint depression as those who underwent closed treatment. The overall outcome of surgical treatment in these patients was better than that achieved with closed treatment. Therefore, the severity of joint depression cannot be used as an argument against surgery, but rather as an argument for it. In performing surgery, the following treatment guidelines should be remembered:

1. Anatomic reduction
2. Elevation of the plateau *en masse*
3. Bone grafting of the defect in the metaphysis
4. Stable internal fixation
5. Early motion

REFERENCES

1. Apley, A.G.: Fractures of the Tibial Plateau. Orthop. Clin. North. Am. 10:61, 1979.
2. Apley, A.G.: Fractures of the Lateral Tibial Condyle Treated by Skeletal Traction and Early Mobilization. J. Bone Joint Surg. 38-B:699, 1956.
3. Bowes, D., and Hohl, M.: Tibial Condylar Fractures. Evaluation of Treatment and Outlook. Clin. Orthop. 171:104, 1982.
4. Brown, G.A., and Sprague, B.L.: Cast Brace Treatment of Plateau and Bicondylar Fractures of the Proximal Tibia. Clin. Orthop. 119:184, 1976.
5. Dias, J.J., Stirling, A.J., Finlay, D.B.L., and Gregg, P.J.: Computerized Axial Tomography for Tibial Plateau Fractures. J. Bone Joint Surg. 69-B:84, 1987.
6. Dovey, H., and Heerfordt, J.: Tibial Condyle Fractures. A Follow-up of 200 Cases. Acta. Chir. Scand. 137:521, 1971.
7. Elstrom, J., Pankovich, A.M., Sasson, H., and Rodriguez, J.: The Use of Tomography in the Assessment of Fractures of the Tibial Plateau. J. Bone Joint Surg. 58-A:551, 1976.
8. Gossling, H.R., and Peterson, C.A.: A New Surgical Approach in the Treatment of Depressed Lateral Condylar Fractures of the Tibia. Clin. Orthop. 140:96, 1979.
9. Gross, A.: Personal communication, Toronto, 1980.
10. Hohl, M.: Tibial Condylar Fractures. J. Bone Joint Surg. 49-A:1455, 1967.
11. Hohl, M., and Hopp, E.: Ligament Injuries in Tibial Condylar Fractures (abstr.). J. Bone Joint Surg. 58-A:279, 1976.
12. Hohl, M.: Management of Tibial Condylar Fractures. *In* Evarts, C.M. (ed.): A.A.O.S. Symposium on Reconstructive Surgery of the Knee. St. Louis, C.V. Mosby, 1978.
13. Ilfeld, F.W., and Hohl, M.: Closed Reduction Treatment of Tibial Condylar Fractures (abstr.) J. Bone Joint Surg. 42-A:534, 1960.
14. Kennedy, W.R.: Fractures of the Tibial Condyles. A Preliminary Report on Supplementary Fixation with Methyl Methacrylate. Clin. Orthop. 134:153, 1978.
15. Manley, P.A., McKeown, D.B., Schatzker, J., Palmer, N.C., and Carman, S.: Replacement of Epiphyseal Bone with Methylmethacrylate: Its Effect on Articular Cartilage. Arch. Orthop. Trauma. Surg. 100:3, 1982.
16. Moore, T.M.: Fracture-Dislocation of the Knee. Clin. Orthop. 156:128, 1981.
17. Moore, T.M., and Harvey, J.P., Jr.: Roentgenographic Measurement of Tibial Plateau Depression due to Fracture. J. Bone Joint Surg. 56-A:155, 1974.
18. Moore, T.M., Meyers, M.H., and Harvey, J.P.: Collateral Ligamentous Laxity of the Knee: Long Term Comparison Between Fractures and Normal. J. Bone Joint Surg. 58-A:594, 1976.
19. Müller, M.E., Allgöwer, M., Schneider, R., and Willenegger, H.: Manual of Internal Fixation. New York, Springer-Verlag, 1979.
20. Salter, R.B., Simmonds, D.F., Malcolm, B.W., Rumble, E.J., MacMichael, D., and Clements, N.D.: The Biological Effect of Continuous Passive Motion on the Healing of Full-Thickness Defects in Articular Cartilage: An Experimental Investigation in the Rabbit. J. Bone Joint Surg. 62-A:1232, 1980.
21. Sarmiento, A., Kinman, P.B., and Latta, L.L.: Fractures of the Proximal Tibia and Tibial Condyles: A Clinical and Laboratory Comparative Study. Clin. Orthop. 145:136, 1979.
22. Schatzker, J.: Compression in the Surgical Treatment of Fractures of the Tibia. Clin. Orthop. Rel. Res. 105:220, 1974.
23. Schatzker, J., McBrown, R., and Bruce, D.: The Tibial Plateau Fracture—The Toronto Experience 1968–1975. Clin. Orthop. Rel. Res. 138:77, 1979.
24. Schulak, D., and Schatzker, J.: Pseudarthrosis of a Tibial Plateau Fracture. Clin. Orthop. Rel. Res. 145:146, 1979.
25. Shybut, G.T., and Spiegel, P.G.: Tibial Plateau Fractures. Clin. Orthop. 138:12, 1979.
26. Waddell, J.P., Johnston, D.W., and Neidre, A.: Fractures of the Tibial Plateau: A Review of 95 Patients and Comparison of Treatment Methods. J. Trauma 21:376, 1981.
27. Walker, P.S., and Erkman, M.J.: The Role of Menisci in Force Transmission Across the Knee. Clin. Orthop. Rel. Res. 109:184, 1975.

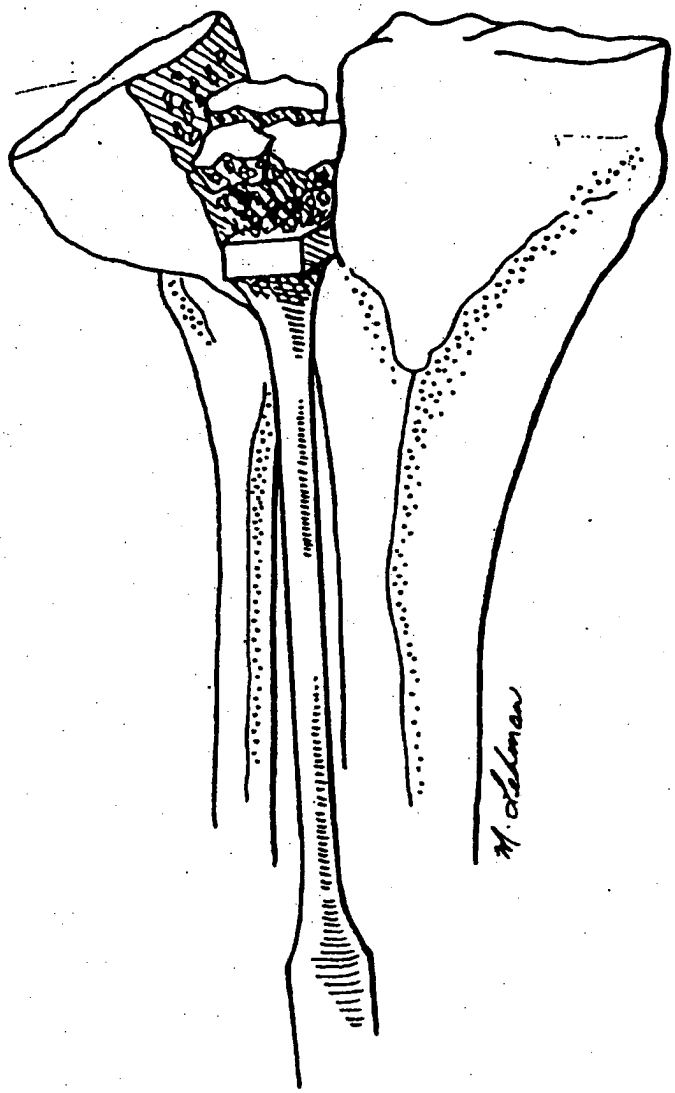

FIGURE 35-9. Note that an *en masse* elevation of fragments consists of insertion of a bone punch deep to the depressed fragments. Upward blows on the punch effect the reduction.