A-19

Chinese Medical Journal, 97(2):105-110, 1984.

OS CALCIS FRACTURE TREATED BY PERCUTANEOUS POKING REDUCTION AND INTERNAL FIXATION

Ma Yuan-zhang 马元璋, Chen Zheng-zhong 陈正中, Qu Ke-fu 曲克服
Zheng Chun-bo 郑纯波, Shen Cai-wei 沈才伟
Feng De-yan 冯德炎 and He Guo-chu 何国础

Shanghai Institute of Traumatology and Orthopedics, Department of Traumatology and Orthopedics, Ruijin Hospital, Shanghai Second Medical College, Shanghai

This paper reports os calcis fracture treated by percutaneous poking reduction and internal fixation. 106 cases were treated this way. The early results were excellent and good in 46 and 25 respectively and the late results excellent in 24 and good in 21. The treatment is described in detail.

Severe os calcis fracture with comminution and depressive displacement of the posterior articular surface and posterior sinus tarsi is called thalamic fracture. It is not easy to reduce downward displaced posterior articular fragment with manipulation owing to obstruction by the sustentaculum tail on the medial side and the cortical fragment on the lateral side. Essex-Lopresti[1] advocated poking reduction for calcaneal fracture. Since 1973, we have treated os calcis thalamic fracture by percutaneous poking reduction and internal fixation using Kirschner wire or specially designed pin. We realized from clinical practice that percutaneous poking reduction and internal fixation must be individualized for the various types of thalamic fracture, the former being indicated also in medial and lateral apophysis and calcaneal body extra-articular fractures.

FRACTURE TYPES

Horizontally depressed thalamic fractures. These are caused by vertical compression on the heel. The posterior articular fragment is commonly displaced downward and impacted into the cancellous bone of the calcaneal body, with complete separation between the posterior articular fragment and the inferior articular surface of the talus. There is also a split fracture of lateral calcaneal wall with lateral displacement. A frontal fracture of the calcaneal body may be present with the fracture line extending from the upper thalamic articular surface downward to the plantar cortex, dividing the os calcis into anterior and posterior fragments with upward displacement of the posterior end of the posterior fragment.

Thalamic fracture with crescent-shaped depressed fragment. This fracture is usually caused by vertical compression with heel abduction. It is similar to the type of horizontally depressed thalamic fracture, except that concomitant calcaneal body fracture is more usual and divides the os calcis into an

anterior and posterior fragments. The crescent-shaped posterior articular fragment includes the whole posterior articular surface or its lateral portion and the anterior end of the posterior articular fragment is displaced downward and rotated backward.

Thalamic fracture with tongue-shaped depressed fragment. This fracture has features similar to crescent depression type. The main difference is that there is posterior prolongation of the thalamic fracture line onto the calcaneal tuberosity posterosuperior area. The anterior end of the thalamic fragment is displaced downward and the posterior end displaced upward forming a gap in the posterior portion of the calcaneal tuberosity.

Calcaneal body extra-articular fracture. This is caused by vertical compression on the heel. The fracture line commonly runs from the sinus tarsi downward to the calcaneal body plantar cortex dividing the os calcis into an anteroposterior fragment. The posterior end of the posterior fragment may be displaced upward, flattening the pedal longitudinal arch.

TREATMENT

The principles of treatment include fracture displacement reduction as normal as possible, adequate immobilization and functional exercise. Reduction is directed mainly at correcting posterior articular fragment and lateral calcaneal wall fragment displacement. The types of fracture and direction and degree of displacement must be analysed from x-rays in order to design the plan of reduction properly. The patient takes a lateral recumbent position with the unaffected side facing down and is operated upon under strict asepsis. A Kirschner wi is passed through the calcaneal tuberosity fc skeletal traction. In the tongue-shaped dc pression type, the wire must be passe through the posterior portion of the fragmen or along its upper cortical surface. With a traction stirrup, manual traction is applie downward and backward to widen the sub talar joint space. Then, for percutaneou poking reduction, a Steinmann pin is inserted through the skin at the posterolateral aspect of the calcaneus and advanced forward, downward and slightly medially. The pin tip can usually detect the gap in the lateral calcaneal wall. Withdraw the pin and reinsert its posterior blunt end along the tract just made. Under fluoroscopy (lateral foot view), adjust the pin direction and depth so that its anterior tip advances under the tongue or crescent fragment and protrudes slightly over the anterior end of the fragment. The fragment is poked upward. For reduction of calcaneal body extra-articular fracture the same method can be used. To poke the horizontally depressed fragment, the pin anterior end must be placed under the central portion of the fragment.

Percutaneous internal fixation is carried out by inserting a Kirschner wire through the skin at the posterosuperior portion of the lateral calcaneal tuberosity into the calcaneal bone. The wire tip advances forward along the inferior surface of the posterior articular fragment penetrating into the sinus tarsi cortex for internal fixation. In unstable horizontally depressed fragments, the pin must be inserted through the fragment into the talus to maintain reduction. The excess wire is cut and the end slightly bent and

buried in the subcutaneous tissue. A specially designed pin may also be used for percutaneous internal fixation. Generally the pin hole need not be sutured.

Manipulative reduction of the displaced lateral calcaneal wall is performed by squeezing the medial and lateral calcaneal wall towards the central portion with both of the operator's palms. The heel shape is checked, keeping in mind that the normal depression below the lateral malleolus is one finger wide. After the lateral wall fragment has been reduced, a finger dorsal surface can be placed there and the lateral malleolar surface should be on the same sagittal plane.

Percutaneous poking reduction of the posterior articular fragment is followed by percutaneous poking of medial and lateral calcaneal apophyses fragments. The Steinmann pin is withdrawn a little and advanced again towards the inferior portion of the calcaneal tuberosity to rest on the medial and lateral calcaneal apophyses fragment to push it for fracture reduction.

After reduction, the affected limb must be immobilized with petit splints or plaster cast for 5-6 weeks when nonweight functional exercises can be carried out. 12-16 weeks after operation, the Kirschner wire or specially designed pin may be removed and bright bearing permitted.

CLINICAL DATA

From 1973 to 1981, 97 cases of calcaneal fractures were treated by percutaneous poking reduction with Steinmann pin. 70 were male and 27 female. Age ranged from 19 to 68 years, averaging 41. The left side was injured in 50, the right in 38 and both sides in 9. The total number of calcaneal fractures was 106, including 19 horizontal depression, 51 tongue depression, 31 crescent depression and 5 calcaneal body extra-articular. Among these, 19 were associated with fracture of both the medial and lateral calcaneal apophyses, with displacement in 16 and without in 3. Percutaneous poking reduction was carried out in all displaced apophyseal fragments. Of the cases accompanied by fractures of other portions of the calcaneum, 2 were anterior process fractures without displacement, and 4 anterior articular surface fracture, including 3 without displacement and 1 with slightly lateral displacement and lateral subluxation of the talo-scaphoid joint,

Table 1. Early results of fracture reduction

Reduction method	Early results				Total
	Excellent	Good	Fair	Poor	
Poking	10	7	8	11	36
Poking and internal fixation	36	18	5	11	70
Total	46	25	13	22	106

Table 2. Late results of 85 calcaneal fractures

Late results				Total
Excellent	Good	Fair	Poor	
23	11	1		35
12	9	1		22
5	4	3		12
1	8	4	3	16
41	32	9	3	85

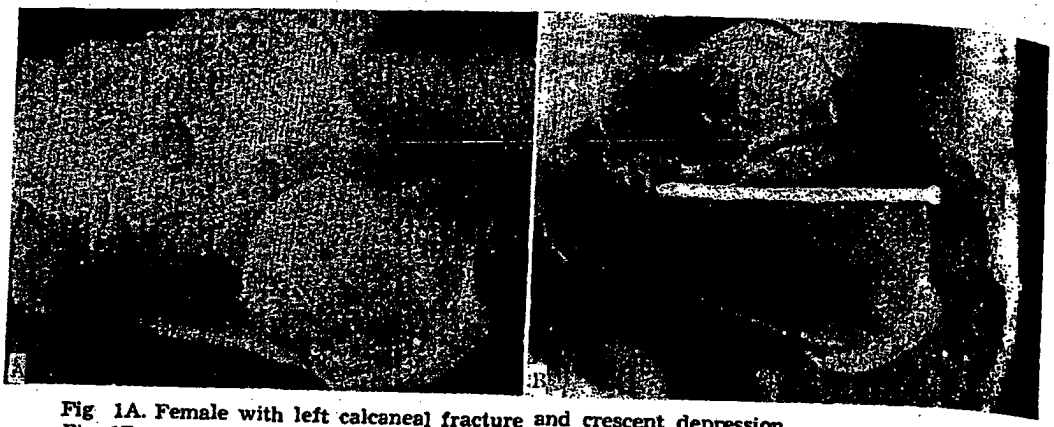

Fig 1A. Female with left calcaneal fracture and crescent depression.
Fig. 1B. The same case, Results of pin percutaneous poking reduction and percutaneous internal fixation with a specially designed pin are excellent.

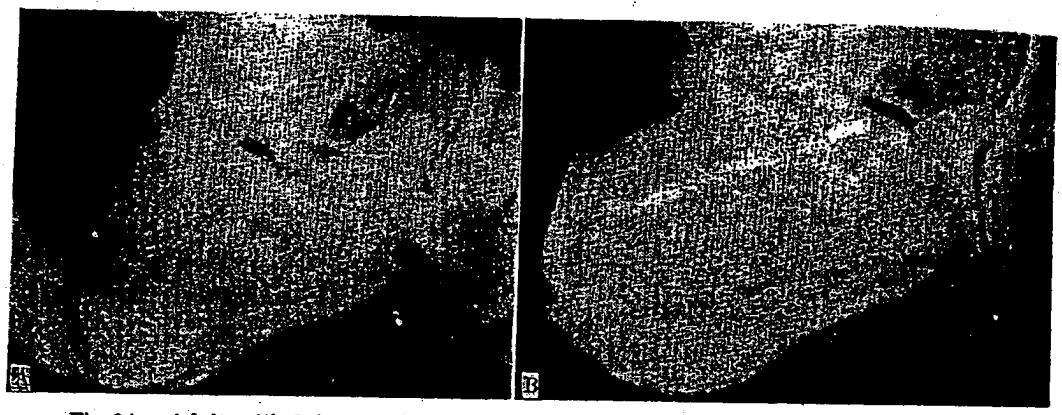

Fig 2A. Adult with left calcaneal body extra-articular fracture and medial and lateral apophyseal fractures.

Fig 2B. The same case. After percutaneous-poking reduction of the displaced posterior articular surface and medial and lateral apophyses fragment, percutaneous internal fixation is done with Kirschner wire.

All the cases in this series were simple fractures and most of them had severe displacement. According to the Böhler angle status before fracture reduction, it was less than 0 degree (i.e., negative value or a reverse angle) in 28, 0-10 degrees in 59, 11-20 degrees in 15 and 21-25 degrees in 4. Most cases were reduced within 1-2 days of injury, the longest interval being 19 days, averaging 3 days. After reduction, 36 had no internal fixation, 46 had percutaneous internal fixation with Kirschner wire and 24 had percutaneous internal fixation with specially designed pin. All the pin and wire holes healed without infection. The early results of treatment were assessed according to

Böhler's angle restoration and divided into 4 grades: excellent, talocalcaneal angle of more than 30 degrees; good, 26-30 degrees; fair, 21-25 degrees; poor, less than 20 degrees. Among the 106 cases, fracture reduction was excellent in 46, 36 of which were percutaneously fixed with Kirschner wire or a specially designed pin; good in 25, 18 of which were percutaneously fixed; fair in 13, 5 of which were percutaneously fixed, and poor in 22, 11 of which were percutaneously fixed (Table 1). All the fractures healed.

The late results were mainly evaluated according to recovery of muscular strength, walking and work capacity and presence or absence of pain. They were graded as excellent, no pain or occasional slight ache, normal muscular strength, and recovery of normal walking and working capacity; good, slight ache and ache after long distance walking, normal muscular strength and recovery of normal working capacity; fair, mild ache, slight muscular weakness of foot flexion-extension with lack of muscular strength, slight decrease of walking capacity, near normal working capacity or change to lighter work; poor, more severe pain, more lack of muscular strength in foot flexion-extension muscular strength may be less than grade 4, change to light work or inability to work. In 97 of this series 88 were followed up for more than 1 year. Among these, 85 were calcaneal fractures, including 7 bilateral os calcis fractures. The longest follow-up was 8 years, averaging 4 years and 5 months. The late results of fracture reduction are shown in Table 2 and Figs 1, 2.

DISCUSSION

Before percutaneous poking reduction and internal fixation, the fracture type and displaced fragment location must be ascertained and then the appropriate method of treatment decided upon to accomplish good reduction. Care must be taken in planning the location and direction of pin advance during percutaneous poking. Generally, poking reduction can be accomplished if x-ray fluoroscopy (lateral view) demonstrates that the anterior end of the Steinmann pin is under the anterior end of the posterior articular fragment. The anterior end of the Steinmann pin should not be directed too medially or it will rest on the sustentaculum tali or its adjoining bone. Avoidance of the fragment containing only the lateral portion of the posterior articular portion is particularly important, because this condition usually gives a false impression on lateral view fluoroscopy that the anterior end of the Steinmann pin touches the fragment, consequently leading to failure of reduction. After repeated attempts at advancing and poking the pin, the inferior thalamic portion, the cancellous bone and its surroundings may be severely damaged resulting in a large cavity which makes keeping the fracture fragments in the correct position difficult despite satisfactory poking reduction and Kirschner wire internal fixation.

After posterior articular fragment reduction, the displaced fragment of the plantar cortex of the calcaneal body is reduced spontaneously in most cases. However, medial and lateral calcaneal apophyses fragment can not be reduced with mainpulation. These fragments must also be poked back to their normal positions with a Steinmann pin lest late painful heel weight-bearing appear. Guard

against too early heel weight-bearing lest the fragments redisplace.

From the observations in this series, it is found that the method of percutaneous poking reduction and internal fixation is simple, can overcome the difficulties of manipulative reduction and can obviate such complications of open reduction as disruption, necrosis and wound infection. The key to treatment is posterior articular fragment reduction and internal fixation. After reduction of this fragment, lateral displacement of the lateral calcaneal fragment can usually be reduced by manipulation. Calcaneal body extra-articular fracture is easy to reduce and maintenance of reduction is accomplished with Kirschner wire or specially designed pins. Late results are mostly excellent if fracture reduction is excellent. Fair and poor results are usually due to poor reduction. Fair or poor reduction has several causes. Fractures are not easy to reduce after a lapse of 10 days postinjury, the reduced fragment easily redisplaces if internal fixation is not immediately applied after reduction, but the main cause is usually poor technic. Fair and poor results can turn into excellent or good later as a result of improvement in the lateral calcaneal and posterior articular fragment position or fibrous or bony ankylosis of the talo-calcaneal joint.

REFERENCE

1. Essex-Lopresti P: The mechanism, reduction technique and results in fractures of the os calcis. Br J Surg 39:395, 1952.

HONORARY MEMBERSHIP OF INFECTIOUS DISEASES SOCIETY OF AMERICA CONFERRED ON CHINESE VIROLOGIST

Chinese virologist Huang Zhen-xiang (C.H. Huang), who developed in vitro method for characterization of virus, received the certificate of honorary membership of the Infectious Diseases Society of America on December 9, 1983. He was elected honorary member of the society in May in recognition of his outstanding contributions in this field. Altogether eight foreigners were admitted to the society by the end of 1982.

Huang Zhen-xiang, 73, is honorary director and research fellow of the Institute of Virology under the Chinese Academy of Medical Sciences.

In the early 1940s when teaching microbiology in the United States, Huang published a paper which helped virology advance from the stage of animal experiment to the stage of tissue culture of virus, thus laying the basis of modern virology.

Since the 1950s, Dr Huang has been engaging in the research on Japanese encephalitis. His major research achievements in this field are contained in his "Studies of Japanese Encephalitis in China", published by Advances in Virus Research (Vol 27, 1982) in the United States.

"I'll devote the rest of my life to the reduction of Japanese encephalitis virus," Dr Huang said, "and I hope one day the mankind will eliminate these viruses."

A-20

Number 227
February, 1988

Transpedicular Fixation of Thoracolumbar Vertebral Fractures

SVEN OLERUD, M.D.,* GÖRAN KARLSTRÖM, M.D.,** AND LENNART SJÖSTRÖM, M.D.†

The most frequent surgical treatment of thoracolumbar fractures is still the Harrington rod system despite some adverse effects, the most serious being the locking of five to seven segments. The new pedicular fixation modification suggested by Magerl and Dick lock only two segments and give far better stability of the fractures. Used internally, the system is convenient for the patient, permitting early mobilization, often without any external support. The instrument, called the "posterior segmental fixator" (PSF), is used both as a reduction device and as a fixation device. The injured vertebra is grafted through the pedicle, giving security against late collapse after device removal. Twenty patients treated with this method had an average follow-up period of ten months. The primary reduction attains 88% of the calculated height of the injured vertebra, with only a few percent loss during follow-up time. Clearance of fragments in the spinal canal, diagnosed with computed tomography scan in eight patients, was successfully accomplished in all but one, with only distraction or reduction of the fragment through a limited laminotomy. The instrumentation in these cases was lateral to the dura. Nine patients with neurologic deficits improved and could walk without support or with crutches within a few months. One patient with complete parapiegia remained unchanged.

The main goals of surgical treatment of thoracolumbar vertebral fractures are to achieve reduction, stability, and early, painless mobilization. It is assumed, though not proven, that stable fracture fixation and decompression of nerve structures facilitate the restoration of neurologic deficits.[4,5,19,22,24,25,27,33] A further aim is to avoid late malpositions and to preserve lumbar mobility and posture.[11,27,29,42]

Harrington instrumentation and similar methods are currently the most commonly used fixations for thoracolumbar fractures.[2,7,12,21,30,40,43] However, fracture treatment with the Harrington device has certain limitations. The main disadvantage is that this device fixates five to seven vertebrae, resulting in negative effects on mobility. This negative effect is greater the farther down in the lumbar spine the fracture is located. Furthermore, in the postoperative period a brace is needed for mobilization of the patient during healing time to avoid instrument failures.[21,39] Moreover, the patient is not allowed to sit for six months.

Instability, instrument failures, and correction losses have been reported.[1,5,15,23,32,41,43] Some loss of correction may occur after removal of the distraction devices, so that the end result is often roughly similar to the original deformation.[1,28,38]

Roy-Camille and co-workers' transpedicular screw fixations of plates[37,39] paved the way for Magerl's external fixation of vertebral fractures with the aid of transpedicular screws[30,31] and for posterior segmental fixation with an internal fixator.[1,12] This instrumentation, according to Dick, seems to have several advanta

From the Department of Orthopaedic Surgery, Uppsala University, Uppsala Hospital.
* Professor and Chairman, Orthopaedic Department, University of Uppsala.
** Associate Professor.
† Fellow.
Reprint requests to Sven Olerud, M.D., Department of Orthopaedic Surgery, University Hospital, S-751 85 Uppsala, Sweden.
Received: April 13, 1987.

FIG. 1. The po
composed of one
well as to two sca
other by conical s
normal height an

vertebrae are im
preserved mobil
Because trans
duction, are pla
tebra, the possil
should be better
bar region. Whe
with a transpedi
secondary defor
This article re
riences with p
using the Dick

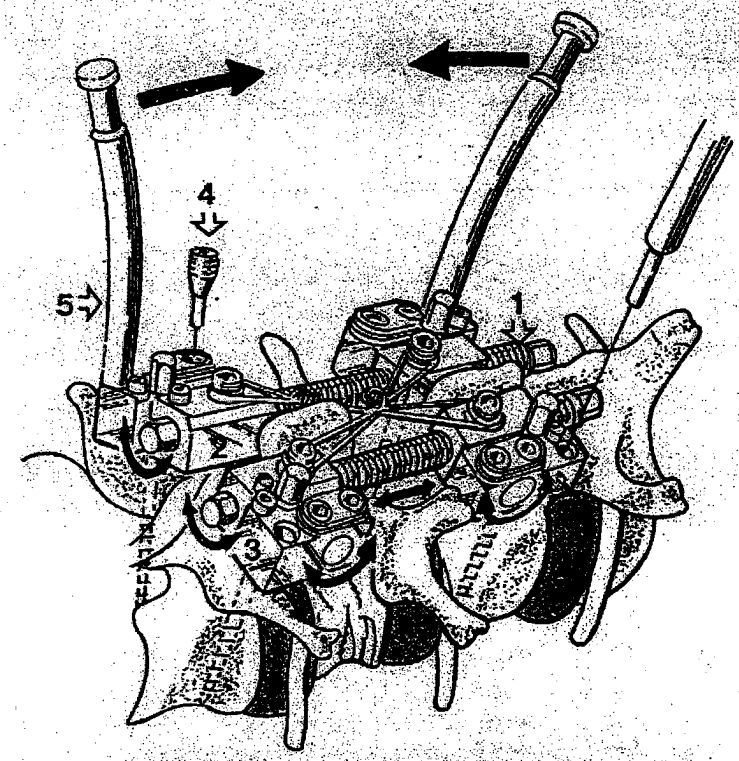

FIG. 1. The posterior segmental fixator (PSF). The device consists of two reversed units. Each unit is composed of one threaded rod (1). On this rod two bolt grips (2) are movable in relation to each other as well as to two screw grips (3) that surround the pedicular screws. The components are locked into each other by conical screws (4). With the special handles (5), the deformed vertebral body can be reduced to normal height and correct lordosis.

several advantages.[13] One is that only three vertebrae are immobilized, resulting in better preserved mobility.

Because transpedicular screws, used for reduction, are placed close to the injured vertebra, the possibility for anatomic reduction should be better, especially in the lower lumbar region. When this treatment is combined with a transpedicular bone graft[8] the risk for secondary deformities should be minimized.

This article reports the authors' early experiences with posterior segmental fixation using the Dick internal fixator[13] and a similar, modified instrument, the "posterior segmental fixator" (PSF).[35]

MATERIAL AND METHODS

The PSF (Fig. 1) consists of two identical but reversed units: a threaded rod against which two bolt grips can be moved in relation to each other and two screw grips that embrace the pedicle screws. The firm hold of the screws in the pedicles greatly facilitates reduction of the fractured vertebra to a correct height and to the correct degree of lordosis. The device is sufficiently stable to maintain the reduced position until healing is completed, without the need for a brace. If additional

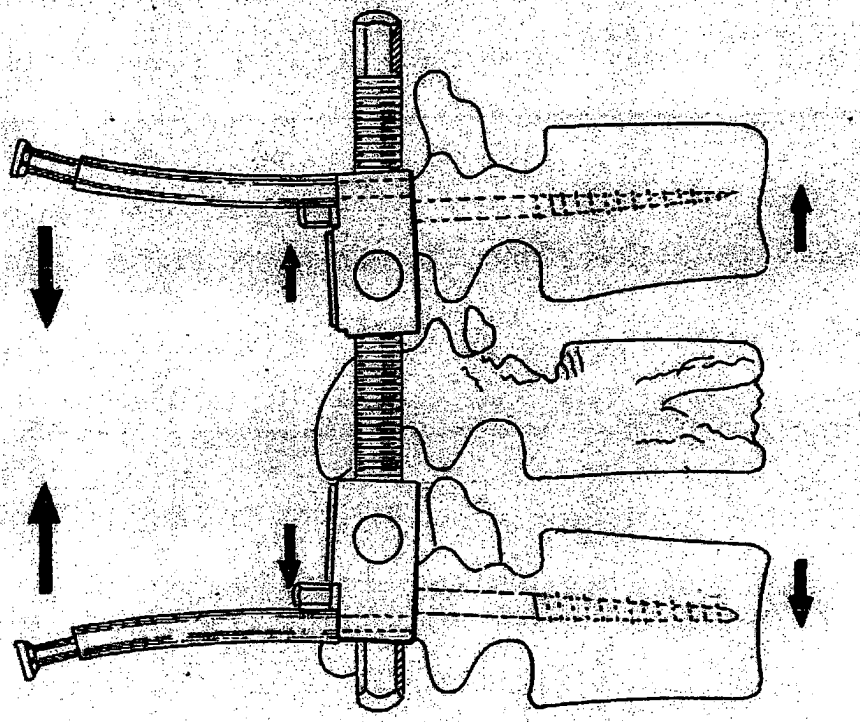

FIG. 2. The PSF allows reduction by extension as well as distraction. After reduction, the configuration and height of the fractured vertebra are normalized.

translatory stability is necessary, diagonal cerclage between the two halves of the instrument can also be used.

SURGICAL TECHNIQUE

The operation is performed with the patient in the prone position on two boards meeting at the level of the fracture site. An operating table suitable for fluoroscopy should be used, because an image intensifier with a C-arm is necessary for a correctly performed operation. The skin incision is made in the midline and should correspond to five spinous processes. The vertebral arches are dissected free subperiosteally to expose the facet joints. The sites of insertion of the screws are identified as described by Louis[29] and Roy-Camille *et al.*[37] The respective joint space and the middle of the transverse process are the most important reference points. A Kirschner wire is used at fluoroscopy to locate the correct place to insert the screw. An opening is then made in the pedicle with a drill or awl, and a self-threading screw is bored manually through the pedicle into the vertebral body. The screw is bored 3.5–4 cm, *i.e.*, almost to the anterior wall of the vertebral body. The position of the screw is checked most reliably in the lateral projection with the C-arm.

When all four screws have been inserted in the correct position, the threaded rod is attached to the screws by its clutches. With the aid of the image intensifier, the posterior wall of the vertebral body is reduced somewhat, but not completely; this will be done later, when the normal lordotic angulation is achieved. Lifting the head end and the foot end of the two boards on which the patient is lying also reduces the anterior wall of the vertebral body, with the fixator as a support; this is necessary if the vertebral arches and/or intervertebral joints do not provide stability.

Further lordosis is now achieved, if needed, by squeezing together the reduction pins that are fixed in the screw grips at the upper and lower vertebrae (Fig. 2). This can often be accomplished

relatively easily with
grips are then locked
the conical screws.
rotated, the fractured
until the height of th
normal.

Subsequently, the
the bolt grips. If the
undamaged, the two
tured vertebra will be
intervertebral joints
tured, however, som
bending and in rotati
onal cerclage wires t
instrument, adequate

On reduction of a
defects will occur in
compression fractur
larly, with the insertio
hole can be made wi
of the pedicles of the
vertebral body. A slig
through the pedicle i
3); under fluoroscopi
tensifier, the end pla
vertebra are reduced.
lum is inserted into t
cellous bone graft—b
posterior aspect of th
lar reamer[14]—is pres

Posterolateral fu
formed, *i.e.*, in cases
laminectomy. Preope
puted tomography
fragments that have b
canal. If there is a bur
often be reduced with
with a minor laminec
identified by fluoros
fier and with the aid
side of the dura. Usin
then be pressed back
this is not possible, a
performed after remo
one side. Any fractur
duced or any fragmen
extracted without any
moved threaded rod
The reduction usually
term intraoperative di
vice units, because th
sion. If desirable, intr
be performed as a che
tients can often be m
out any external supp
simple three-point bra

At follow-up exami
was measured by com

relatively easily with a pair of tongs. The screw grips are then locked to the bolt grips by means of the conical screws. When the threaded rods are rotated, the fractured vertebra is distracted (Fig. 2) until the height of the vertebral body is restored to normal.

Subsequently, the threaded rods are locked to the bolt grips. If the posterior articular system is undamaged, the two segments around the fractured vertebra will be adequately stabilized. If any intervertebral joints or vertebral arches are fractured, however, some instability will remain in bending and in rotation. With the use of two diagonal cerclage wires between the two units of the instrument, adequate stability can be achieved.

On reduction of a compressed vertebral body, defects will occur in the cancellous bone (as in compression fractures in tibial condyles). Similarly, with the insertion of transpedicular screws, a hole can be made with a 5-mm drill through one of the pedicles of the fractured vertebra into the vertebral body. A slightly curved punch is brought through the pedicle into the vertebral body (Fig. 3); under fluoroscopic control with the image intensifier, the end plates and anterior wall of the vertebra are reduced, if possible. An aural speculum is inserted into the pedicular hole and a cancellous bone graft—bone paste obtained from the posterior aspect of the iliac crest with an acetabular reamer[14]—is pressed into the vertebra.[8]

Posterolateral fusions are only rarely performed, *i.e.*, in cases of facet fractures and after a laminectomy. Preoperative myelography or computed tomography (CT) scans will reveal any fragments that have been displaced into the spinal canal. If there is a burst fracture, the fragment can often be reduced with only distraction. Otherwise, with a minor laminectomy such a fragment can be identified by fluoroscopy with an image intensifier and with the aid of an elevator inserted at the side of the dura. Using the PSF, the fragment can then be pressed back into the vertebral body. If this is not possible, a limited laminectomy can be performed after removal of the threaded rod on one side. Any fracture fragments can then be reduced or any fragments present in the spinal canal extracted without any effect on the dura. The removed threaded rod is subsequently reinserted. The reduction usually is not jeopardized by short-term intraoperative dismantling of one of the device units, because the patient is in hyperextension. If desirable, intraoperative myelography can be performed as a check. After operation, the patients can often be mobilized immediately without any external support or, in a few cases, with a simple three-point brace.[13]

At follow-up examination, the reduction effect was measured by comparing the anterior height of the injured vertebra with the calculated height of the same vertebra (the mean value of the vertebra above and the one below the injured vertebra). The reduction effect was also estimated by comparing the Cobb angle.

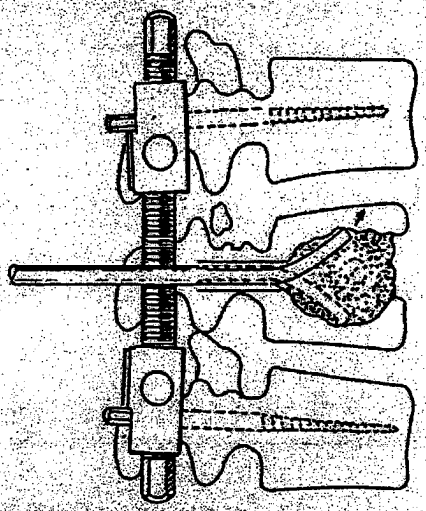

FIG. 3. With a transpedicularly introduced punch, further reduction of fragments in the vertebral body can be reduced. The defect in the vertebra is then filled with a graft in the form of bone paste.[8,13]

PATIENTS

This series consisted of 20 consecutive patients with thoracolumbar burst fractures (14 men and six women) aged 16–59 years (average, 35 years). All fractures had been caused by high-energy trauma, mainly traffic accidents (13 patients). Ten of the patients had neurologic symptoms on admission but only one had complete paraplegia. The injured vertebrae were T12 in three, L1 in five, L2 in four, L3 in two, and L4 in five patients (Table 1).

When classified according to Denis,[11] three fractures were of Type A, 14 of Type B, two of Type D, and one of Type E.

Two patients were treated at a relatively late stage (19 and 45 days, respectively) after injury, and the remaining 18 patients were treated within five days of injury. Of these, seven had surgery on the day of injury.

All were treated with open reduction and fixation with the PSF in the manner described above.

TABLE 1. Kyphotic Deformities

Fractured Vertebra	No. of Patients	Cobb Angle (°) Preoperative	Postoperative
T12	3	24	8
L1	6	18	7
L2	4	7	8 lordosis
L3	2	9	0
L4	5	10 lordosis	11 lordosis

Fifteen patients had transpedicular bone grafting (Fig. 4); in the other five patients the comminution of the vertebra was too severe for grafting to be worthwhile. For these and two other patients, a posterior fusion was done over the two immobilized segments. In 11 patients, minor laminotomies were carried out for inspection and/or additional repositioning of the anterior wall of the spinal canal. Later in the series, perioperative myelography was routinely carried out after reduction to check the repositioning of the anterior wall. This markedly decreased the need for laminotomy.

Eleven of the patients had other injuries, such as thoracic compression injuries or fractures of the lower extremities.

RESULTS

The average follow-up period was ten months (range, six to 17 months). The mean time for roentgenographic control is eight months.

When wound pain subsided, the patients were freely mobilized. They were discharged after two to three weeks if they had no other injury.

Two patients needed further operations. One had an anterior decompression and fusion because a postoperative CT scan showed that the neural decompression was not acceptable. The second patient had continuing radicular pain and was therefore treated with root decompression.

At follow-up examination, only the patient with complete paraplegia remained unchanged. Three patients who were classified before operation as "motor useless," *i.e.*, Frankel *et al.* Grade C,[20] were improved to Frankel Grade D. Six Frankel Grade D patients were improved, although none was entirely free from neurologic symptoms. All except the paraplegic patient are walking without support or with cruiches. Six patients have returned to work, four are back at school, and two are being retrained. Eight are still on the sick list.

Two patients were regarded as technical failures. In one patient the lower grips of the fixator were insufficient, and he regained almost his original kyphotic deformity; however, he is pain-free and working again. This patient was the second in this series and the device was a prototype. Another patient had a translatory instability that was not recognized at the time of operation. This patient should have had diagonal cerclage wiring done to prevent a late lumbar scoliosis of minor degree.

The preoperative and postoperative kyphotic deformities are listed in Table 1. In most of the fractures located in the middle and the lower lumbar spine, a local lordotic curve has been achieved.

The reduction effect, measured by comparing the anterior height of the injured vertebra before and after operation, was satisfying. The preoperative value showed a compression to 56% of the calculated height of the vertebra. At the first postoperative check, the height of the vertebra was raised to an average of 88% of the calculated value. After eight months, this value decreased to 83%. Roughly one-half of the total loss occurred in the two patients defined as technical failures. If these cases are excluded, the average postoperative height is 85% of normal.

The reduction effect, measured by calculating the Cobb angle, showed an average loss of 4° in the group of 20 patients. If the technical failures are excluded, the angulation loss during the eight-month period averaged only 2°.

DISCUSSION

With the PSF, the primary goals of the treatment are achieved: the patients are



pain-free after a
easier than afte
operations since
tions, and the br
simple type.[13,35]
are comparable t

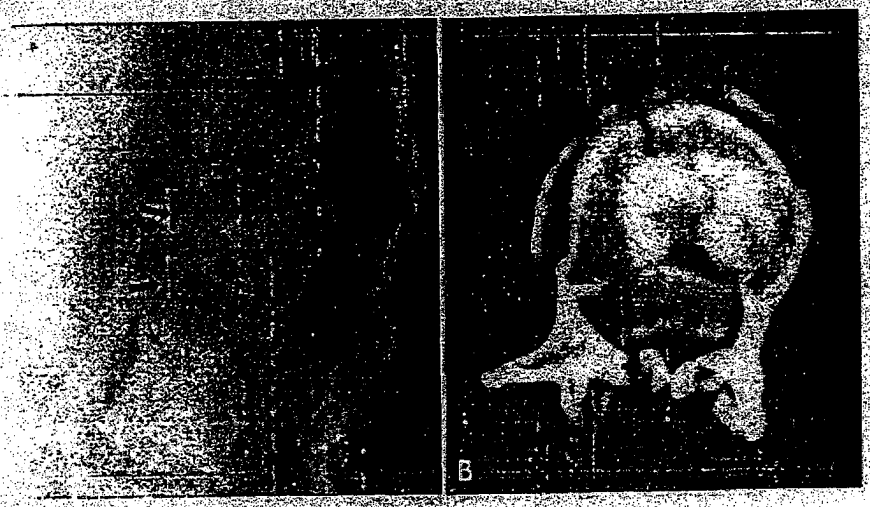



FIGS. 4A–4C. (A) Burst fracture of L2 (arrows). (B) CT scan showing a large fragment located in the spinal canal. (C) Roentgenogram taken six months after reduction and fixation with PSF. The transpedicular grafting gives a slightly higher density to the central part of the body of the vertebra. The height of the vertebral body is well restored.

pain-free after a few days, mobilization is easier than after Harrington distraction operations since there are no sitting restrictions, and the brace, when required, is of a simple type.[13,35] The anatomic end results are comparable to or somewhat better than those achieved with the Harrington technique.[28]

Two principles of treatment are considered to promote regression of partial neurologic deficits in cases of unstable vertebral fractures. One is decompression of the spinal

cord and nerve roots; the other is elimination of instability.[5,16,24,25] The time factor is also important.[10]

Decompression of the contents of the spinal canal can be achieved with distraction procedures, laminectomy, or an anterior surgical approach. Laminectomies alone are currently considered to be of little value, because they increase instability[6,9,18] such that the neurologic deficit may even be aggravated.[34] Moreover, posterior decompression is usually an illogical choice of treatment since the pressure on the nerve structures is due, in most cases, to vertebral fragments or disc tissue that is forced into the spinal canal from the anterior direction.[1,27] This has been demonstrated in recent years with CT investigations.[43,44] Because distraction operations alone also do not guarantee adequate decompression,[27] especially in patients with a fracture more than three or four days old, anterior decompression operations combined with posterior or anterior fixation procedures have been used increasingly in recent years.[3,4,17,26,27,33]

Radical anterior decompression and stabilization, however, is in many cases a rather extensive procedure. Posterior reduction and internal fixation with the Dick device[13] or the PSF,[35] used in this series, are far less demanding procedures and give results equivalent to those of anterior operations.

The anatomic results in this series are comparable to or somewhat better than those achieved with the Harrington technique, the reduction having been close to anatomic (Fig. 4). The tolerance for flexion deformity should also be better than in Harrington-operated patients, since the possibility of compensating for such a deformity is better preserved when only two vertebral segments are immobilized. Several problems with Harrington-operated patients have been reported (*e.g.*, restricted lumbar mobility and loss of lordosis), notably after scoliosis surgery. The same is apparently true for traumatized patients treated the same way.[13]

The fractured and grafted vertebrae[8,15] are expected to heal after six months, although the device is not removed before at least one year. The loss of anterior vertebral height and increasing flexion deformity can to some extent be explained by the two technical failures in this series. For the rest of the patients, the loss of vertebral height is less than that described after Harrington fixation without technical failures.[28] The reason for the loss of correction in patients who do not show any signs of PSF failure is probably that the grip of the screws decreased somewhat in the cancellous bone of the vertebrae.

It is interesting that there is relatively more loss of flexion than of vertebral height. This is probably due to fact that an injured disc will collapse when the screw grip in the vertebra decreases somewhat.

The major advantage of this method seems to be that further deformation after device removal can be avoided, but this still has to be evaluated and confirmed.

REFERENCES

1. Aebi, M., Mohler, J., Zäch, G., and Morscher E.: Analysis of 75 operated thoracolumbar fractures and fracture dislocations with and without neurological deficit. Arch. Orthop. Trauma. Surg. 105:100, 1986.
2. Armstrong, G. W. D., and Johnston, D. H.: Stabilization of spinal injuries using Harrington instrumentation. J. Bone Joint Surg. 56B:590, 1974.
3. Bohlman, H. H.: Traumatic fractures of the upper thoracic spine with paralysis. J. Bone Joint Surg. 56A:1299, 1974.
4. Bohlman, H. H., and Eismont, F. J.: Surgical techniques of anterior decompression and fusion for spinal cord injuries. Clin. Orthop. 154:57, 1981.
5. Bradford, D. S., Akbarnia, B. A., Winter, R. B., and Seljeskog, E. L.: Surgical stabilization of fracture dislocation of the thoracic spine. Spine 2:185, 1977.
6. Clark, W. K.: Spinal cord decompression in spinal cord injury. Clin. Orthop. 154:9, 1981.
7. Convery, F. R., Minteer, M. A., Smith, R. W., and Emerson, S. M.: Fracture dislocation of the dorsolumbar spine. Acute operative stabilization by Harrington instrumentation. Spine 3:160, 1978.
8. Daniaux, H.: Teknik und erste Ergebnisse der transpedikulären Spongiosaplastik bei Kompressionsbrüchen im Lendenwirbelsäulenbereich. Acta Chir. Austriaca (Suppl.) 43:79, 1982.
9. Davies, W. E., Morris, J. H., and Hill, V.: An analysis of conservative (non-surgical) management of thoracolumbar fractures and fracture dislocations with neural damage. J. Bone Joint Surg. 62A:1324, 1980.
10. De la Torre, J. C.: Spinal cord injury: Review of basic and applied research. Spine 6:315, 1983.

11. Denis, F.: Spinal instability as defined by three-column spine concept in acute spinal trauma. Clin. Orthop. 189:65, 1984.
12. Denis, F., Armstrong, G. W., D., Searls, K., and Matta, L.: Acute thoracolumbar burst fractures in the absence of neurologic deficit. Clin. Orthop. 189:142, 1984.
13. Dick, W.: Innere Fixation von Brust- und Lendenwirbelfrakturen. Bern, Verlag Hans Huber, 1984.
14. Dick, W.: Use of the acetabular reamer to harvest autogenic bone graft material: A simple method for producing bone paste. Arch. Orthop. Trauma. Surg. 105:235, 1986.
15. Dickson, J. H., Harrington, P. R., and Erwin, W. D.: Results of reduction and stabilization of the severely fractured thoracic and lumbar spine. J. Bone Joint Surg. 60A:799, 1978.
16. Donovan, W. H., and Dwyer, A. P.: An update on the early management of traumatic paraplegia (nonoperative and operative management). Clin. Orthop. 189:12, 1984.
17. Dunn, H. K.: Anterior stabilization of thoracolumbar injuries. Clin. Orthop. 189:116, 1984.
18. Edwards, C. C., Simmons, S., Levine, A. M., Bands, R. E., and Campbell, S. E.: Primary rigid fixation of 135 thoracolumbar injuries: Analysis of results. Orthop. Trans. 9:479, 1985.
19. Erikson, D. L., Leider, L. L., and Brown, W. E.: One-stage decompression-stabilization for thoracolumbar fractures. Spine 2:53, 1977.
20. Frankel, H. L., Hancock, D. O., Hyslop, G., Melzak, J., Michaelis, L. S., Ungar, G. H., Vernon, J. D. S., and Walsh, J. J.: The value of postural reduction in the initial management of closed injuries of the spine with paraplegia and tetraplegia. Paraplegia 7:179, 1969.
21. Harrington, P. R.: Instrumentation in spine instability other than scoliosis. S. Afr. J. Surg. 5:7, 1967.
22. Jacobs, R. R., and Casey, M. P.: Surgical management of thoracolumbar spinal injuries: General principles and controversial considerations. Clin. Orthop. 189:22, 1984.
23. Jacobs, R. R., Nordwall, A., and Nachemson, A.: Reduction, stability, and strength provided by internal fixation systems for thoracolumbar spinal injuries. Clin. Orthop. 171:300, 1982.
24. Jelsma, R. K., Kirsch, P. T., Jelsma, L. F., Ramsey, W. C., and Rice, J. F.: Surgical treatment of thoracolumbar fractures. Surg. Neurol. 18:156, 1982.
25. Jelsma, R. K., Rice, J. F., Jelsma, L. F., and Kirsch, P. T.: The demonstration and significance of neural compression after spinal injury. Surg. Neurol. 18:79, 1982.
26. Johnson, J. R., Leatherman, K. D., and Holt, R. T.: Anterior decompression of the spinal cord for neurological deficit. Spine 8:396, 1983.
27. Kostuik, J. P.: Anterior fixation for fractures of the thoracic and lumbar spine with or without neurological involvement. Clin. Orthop. 189:103, 1984.
28. Lindahl, S., Willén, J., and Irstam, L.: Unstable thoracolumbar fractures: A comparative radiologic study of conservative treatment and Harrington instrumentation. Acta Radiol. [Diagn.] 26:67, 1985.
29. Louis, R.: Surgery of the Spine. Berlin, Springer Verlag, 1983.
30. Magerl, F.: External skeletal fixation of the lower thoracic and the lumbar spine. *In* Uthoff, H. K. (ed.): Current Concepts of External Fixation of Fractures. Berlin, Springer Verlag, 1982, pp. 353–366.
31. Magerl, F. P.: Stabilization of the lower thoracic and lumbar spine with external skeletal fixation. Clin. Orthop. 189:125, 1984.
32. McAfee, P. C., and Bohlman, H. H.: Complications following Harrington instrumentation for fractures of the thoraco-lumbar spine. J. Bone Joint Surg. 67A:672, 1985.
33. McAfee, P. C., Bohlman, H. H., and Yuan, H. A.: Anterior decompression of traumatic thoraco-lumbar fractures with incomplete neurologic deficit using a retroperitoneal approach. J. Bone Joint Surg. 67A:89, 1985.
34. Morgan, T. H., Wharton, G. W., and Austin, G. N.: The results of laminectomy in patients with incomplete spinal cord injuries. Paraplegia 9:14, 1971.
35. Olerud, S., Karlström, G., and Sjöström, L.: A new principle in the treatment of fractures of the thoracolumbar spine: Transpedicular segmental fixation. Orthopedics (in press).
36. Osebold, W. R., Weinstein, S. L., and Sprague, B. L.: Thoracolumbar spine fractures: Results of treatment. Spine 6:13, 1981.
37. Roy-Camille, R., Saillant, G., Berteaux, D., and Marie-Anne, S.: Early management of spinal injuries. *In* McKibbin, B. (ed.): Recent Advances in Orthopaedics. Edinburgh, Churchill Livingstone, 1979, pp. 57–87.
38. Roy-Camille, R., Saillant, G., Marie-Anne, S., and Mamoudy, P.: Behandlung von Wirbelfrakturen und Luxationen am thorakolumbalen Übergang. Orthopäde 9:63, 1980.
39. Soreff, J., Axdorph, G., Bylund, P., Odéen, I., and Olerud, S.: Treatment of patients with unstable fractures of the thoracic and lumbar spine. Acta Orthop. Scand. 53:369, 1982.
40. Svensson, A., Aaro, S., and Öhlén, G.: Harrington instrumentation for thoracic and lumbar vertebral fractures. Acta Orthop. Scand. 55:38, 1984.
41. Wenger, D. R., and Carollo, J. J.: The mechanics of thoracolumbar fractures stabilized by segmental fixation. Clin. Orthop. 189:89, 1984.
42. White, A. A. III, and Panjabi, M.: Clinical Biomechanics of the Spine. Philadelphia, J. B. Lippincott, 1978, pp. 223–224.
43. White, R. R., Newberg, A., and Seligson, D.: Computerized tomographic assessment of the traumatized dorsolumbar spine before and after Harrington instrumentation. Clin. Orthop. 146:150, 1980.
44. Willén, J., Lindahl, S., Irstam, L., and Nordwall, A.: Unstable thoracolumbar fractures: A study by CT and conventional roentgenology of the reduction effect of Harrington instrumentation. Spine 9:214, 1984.
45. Yosipovitch, Z., Robin, G. C., and Makin, M.: Open reduction of unstable thoracolumbar spinal injuries and fixation with Harrington rods. J. Bone Joint Surg. 59A:1003, 1977.